

ACNS 2031 Medulloblastoma Protocol Contouring Atlas

Study Radiation Oncologists:

Joshua D. Palmer, MD

Luke Pater, MD

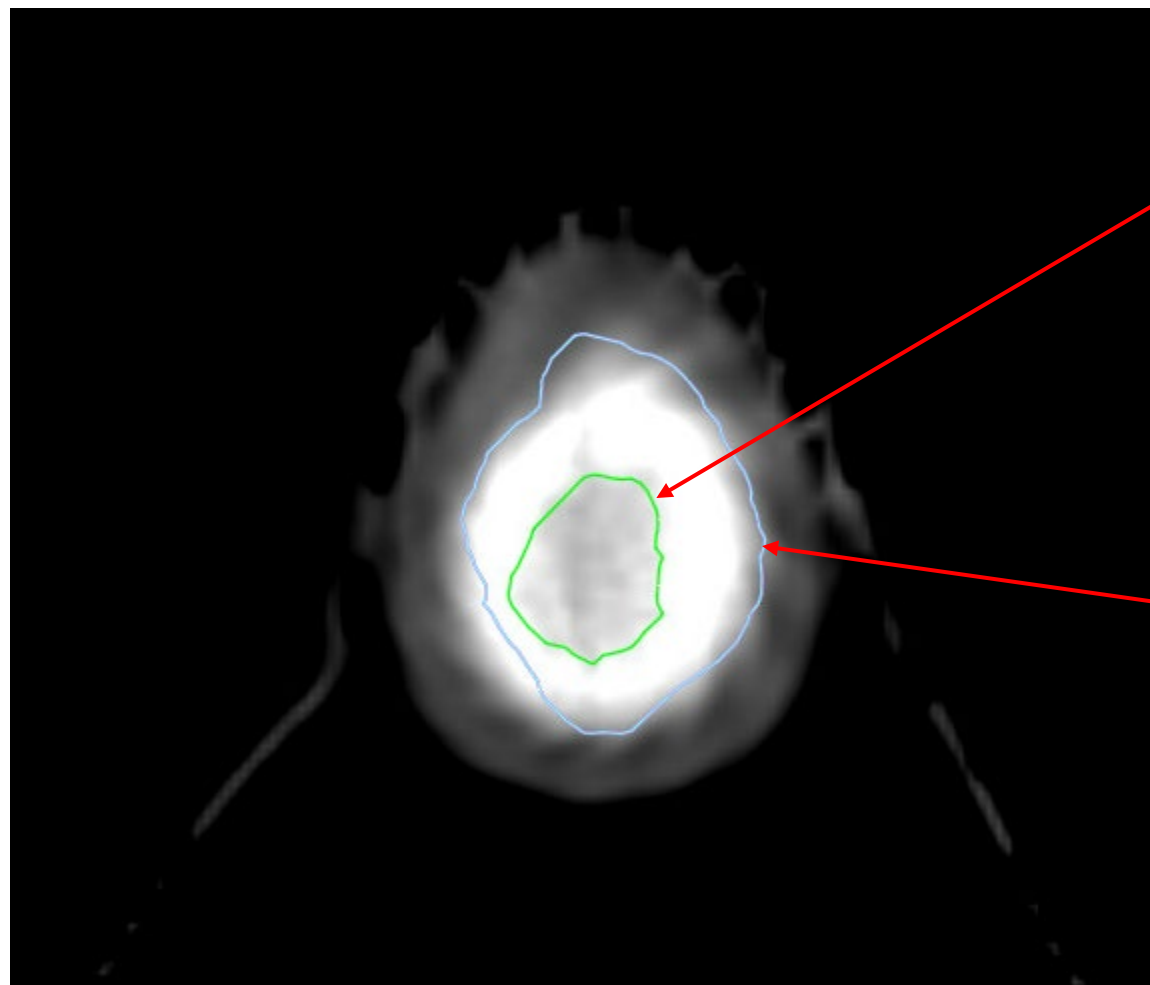
Stephanie Terezakis, MD

Children's Oncology Group

This protocol is for research purposes only, and should not be copied, redistributed or used for any other purpose. Medical and scientific information contained within this protocol is not included to authorize or facilitate the practice of medicine by any person or entity. Research means a systematic investigation, including research development, testing and evaluation, designed to develop or contribute to generalizable knowledge. This protocol is the research plan developed by the Children's Oncology Group to investigate a particular study question or set of study questions and should not be used to direct the practice of medicine by any person or to provide individualized medical care, treatment, or advice to any patient or study subject. The procedure in this protocol are intended only for use by the clinical oncologists in carefully structured settings and may not prove to be more effective than standard treatment. Any person who requires medical care is urged to consult with his or her personal physician or treating physician or visit the nearest local hospital or healthcare institution.

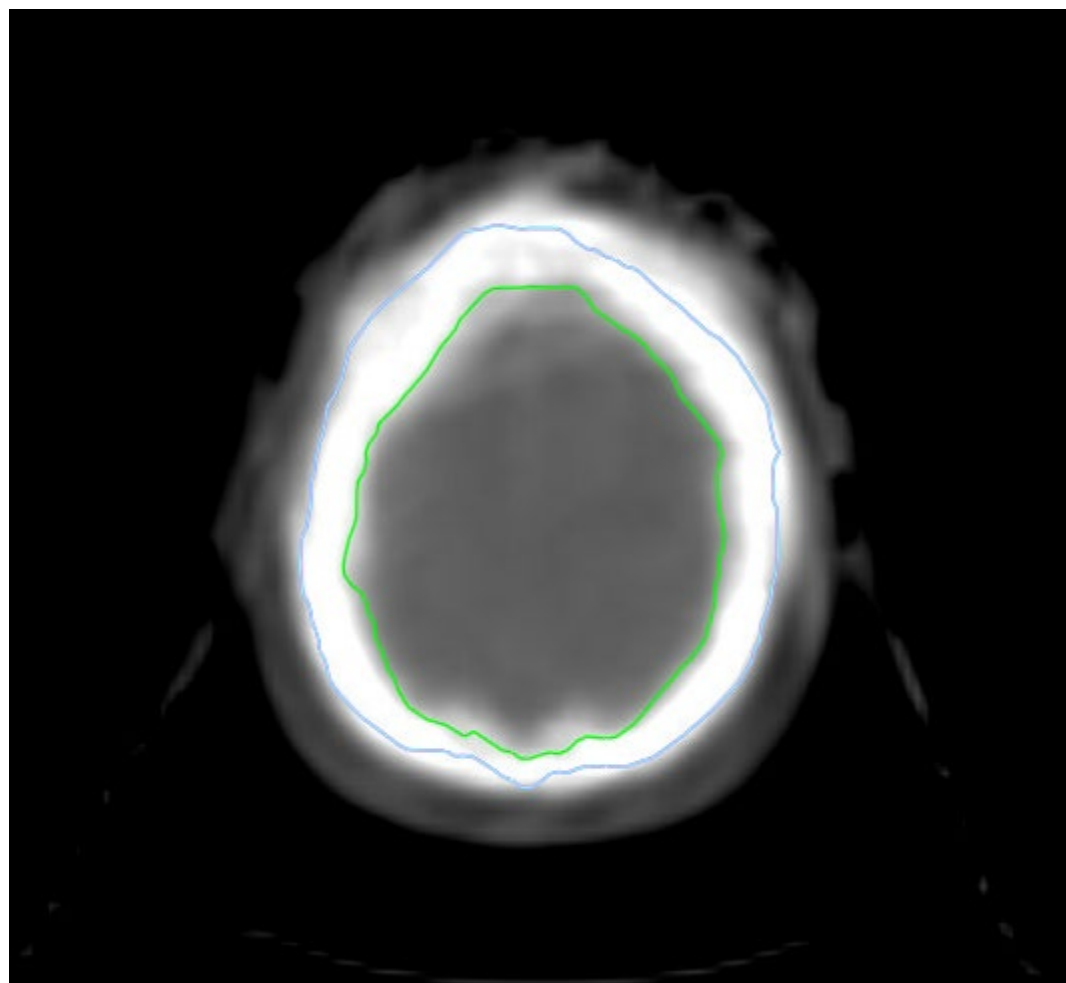
General Guidelines

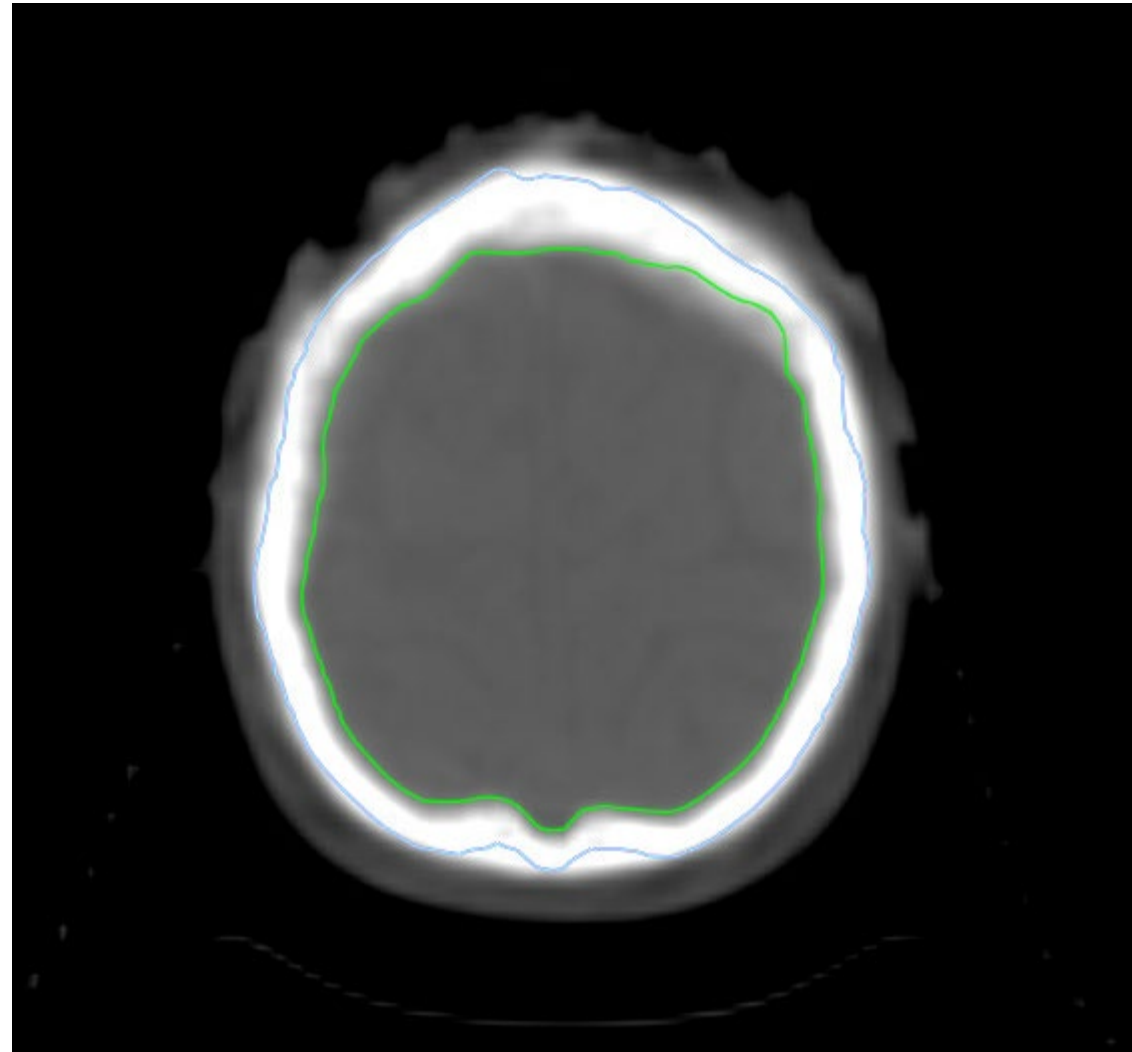
- The CTV_Brain encompasses the whole brain within the inner table of the calvarium, cribriform plate, inferior temporal lobes, pituitary fossa, and the CSF contained within the dural sheath of the cranial nerves (examples will be shown in the atlas)
- The Spinal CTV includes the subarachnoid space including the nerve roots laterally
- The lower extent of the CTV_Spine is 1.5 cm below the termination of the thecal sac
- PTV is utilized for photon planning (***Section 17.7.4***)

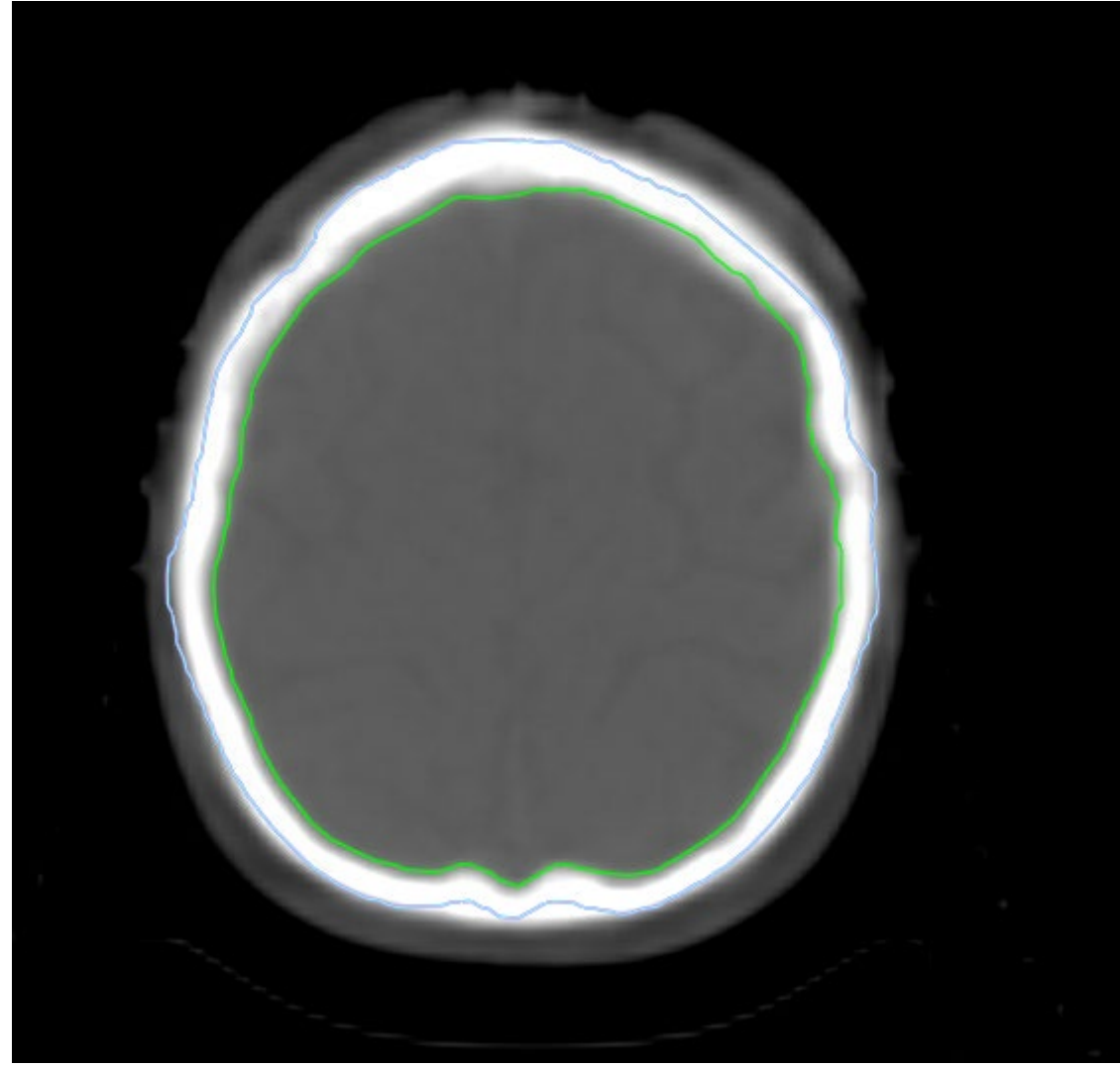


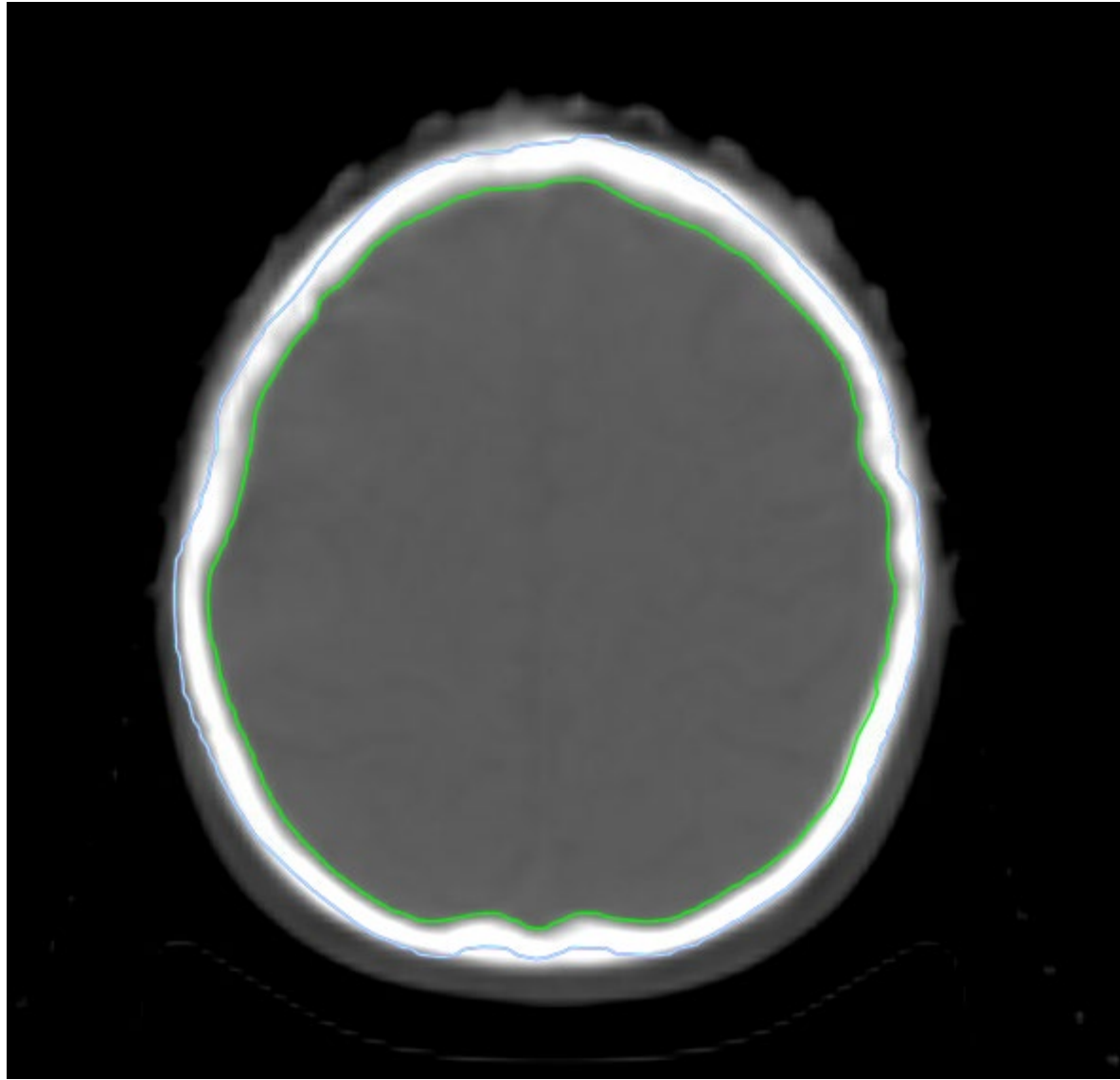
CTV_Brain- green

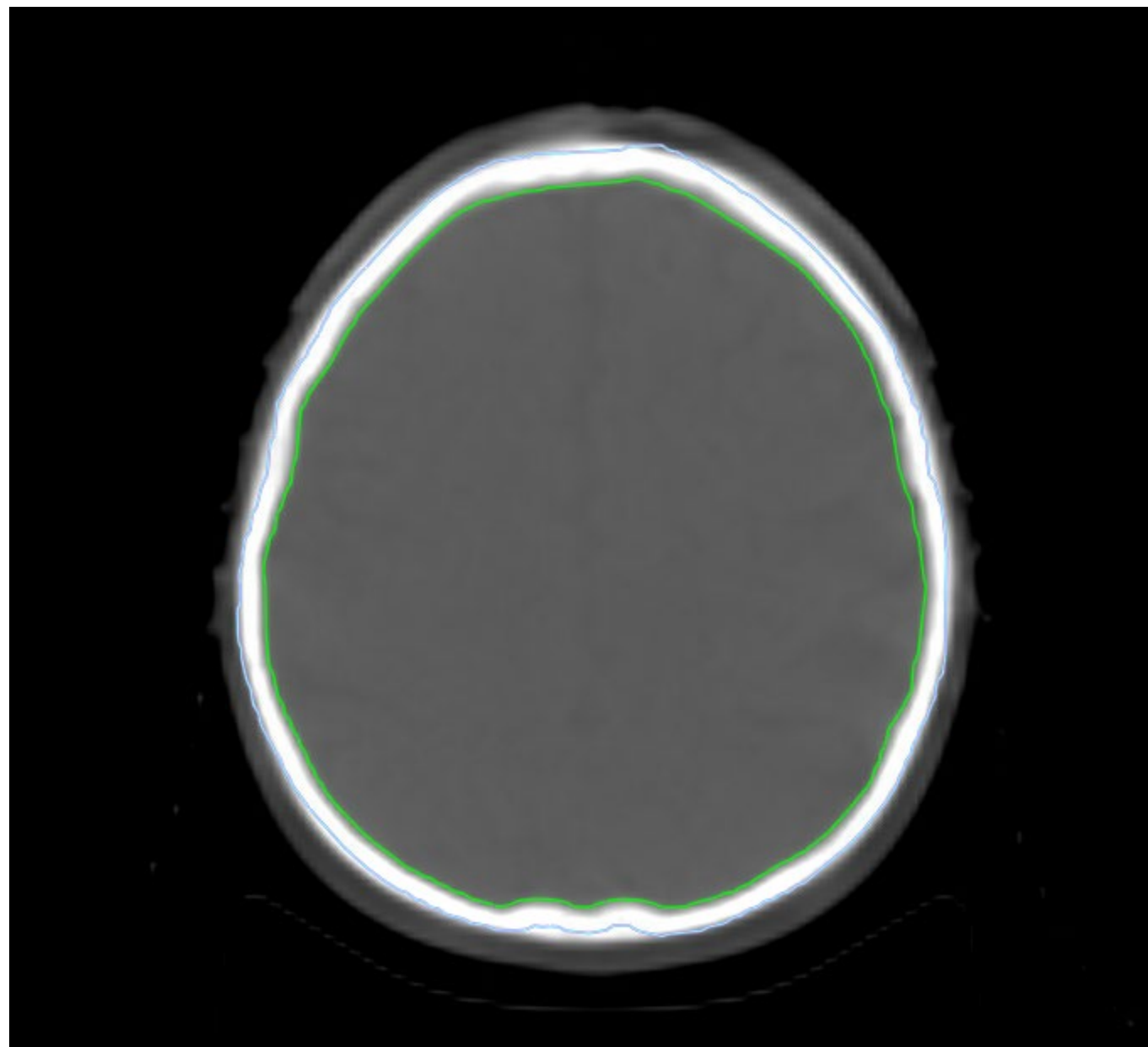
PTV_CSI- Cyan

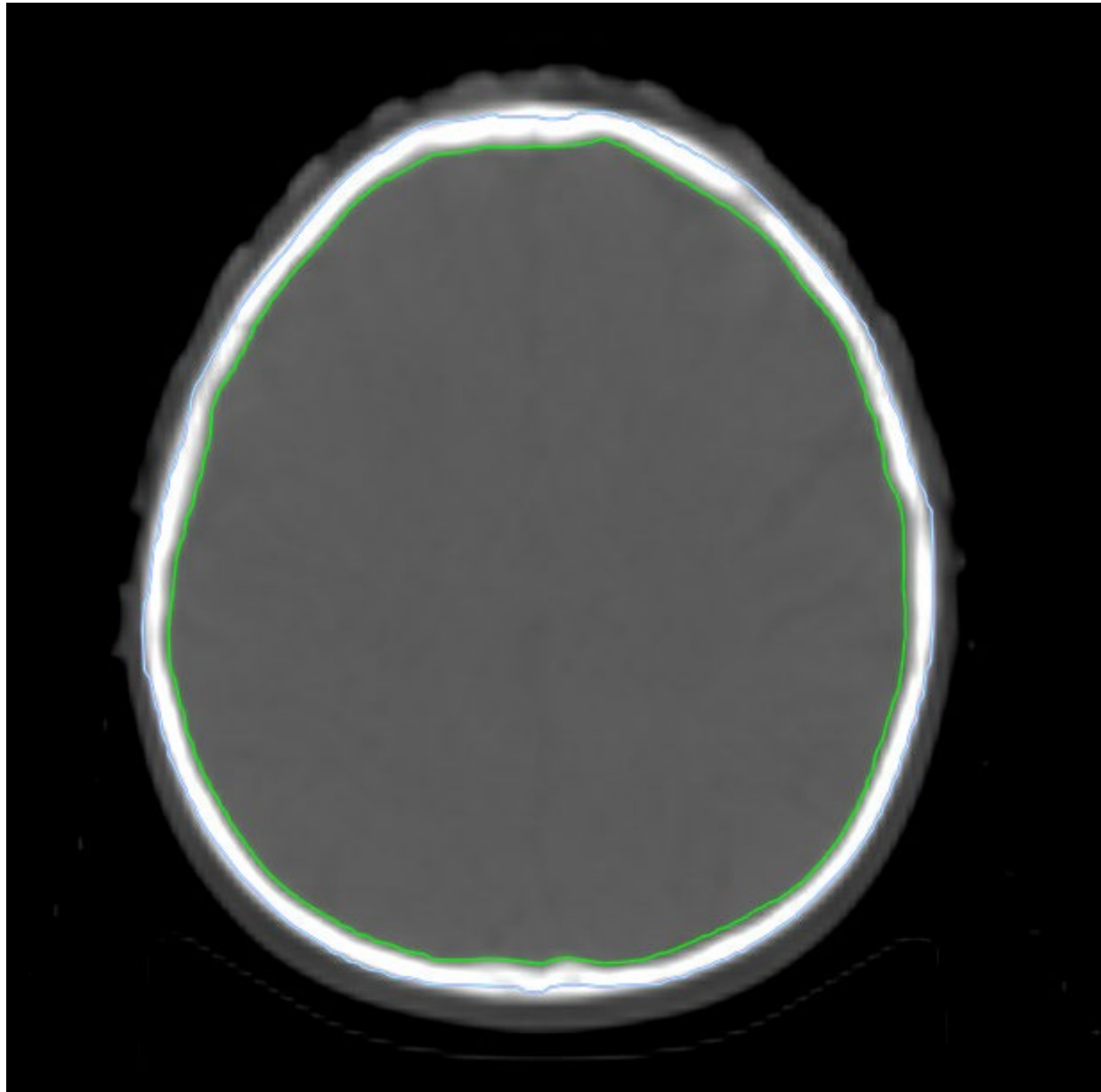


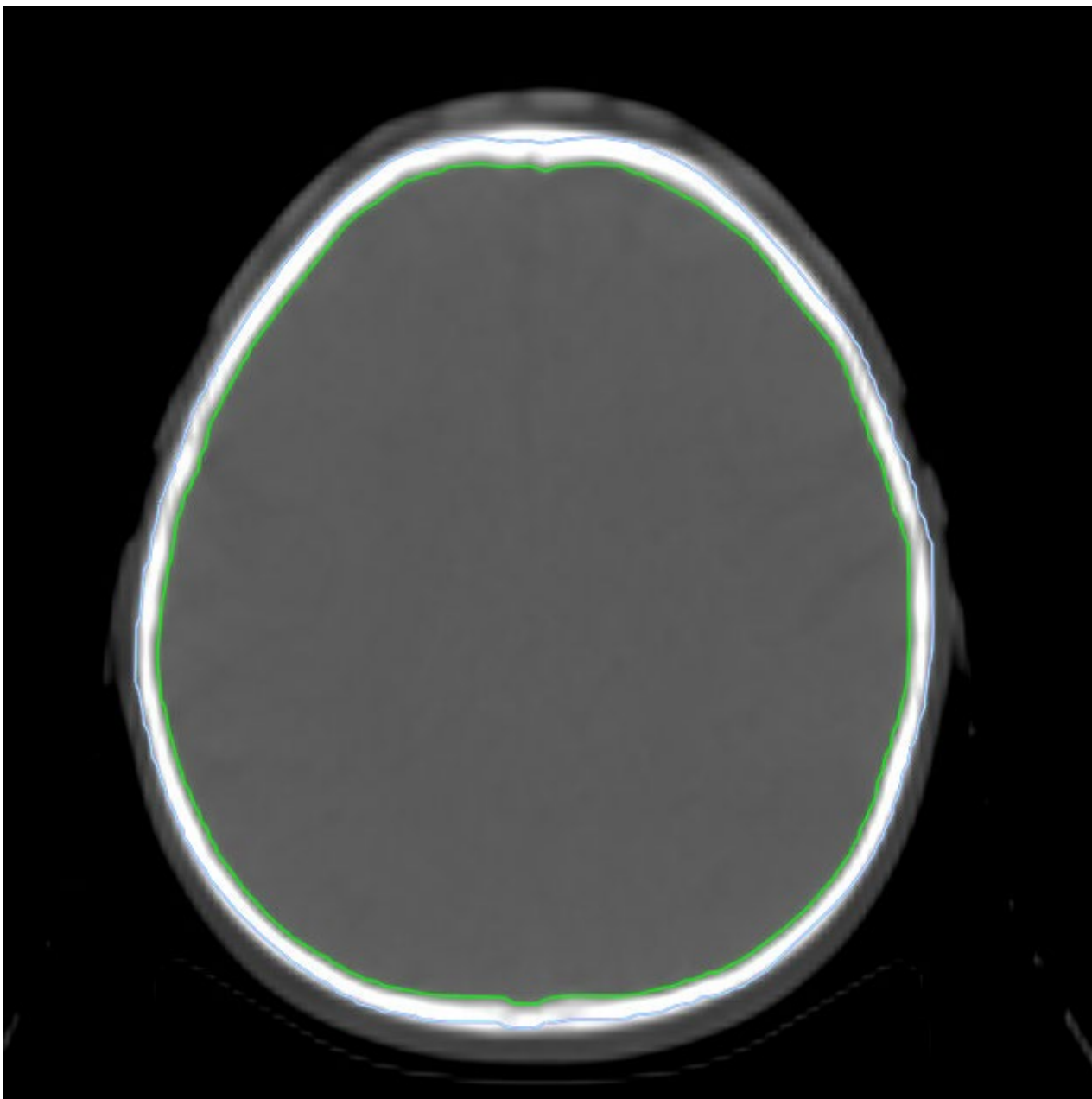


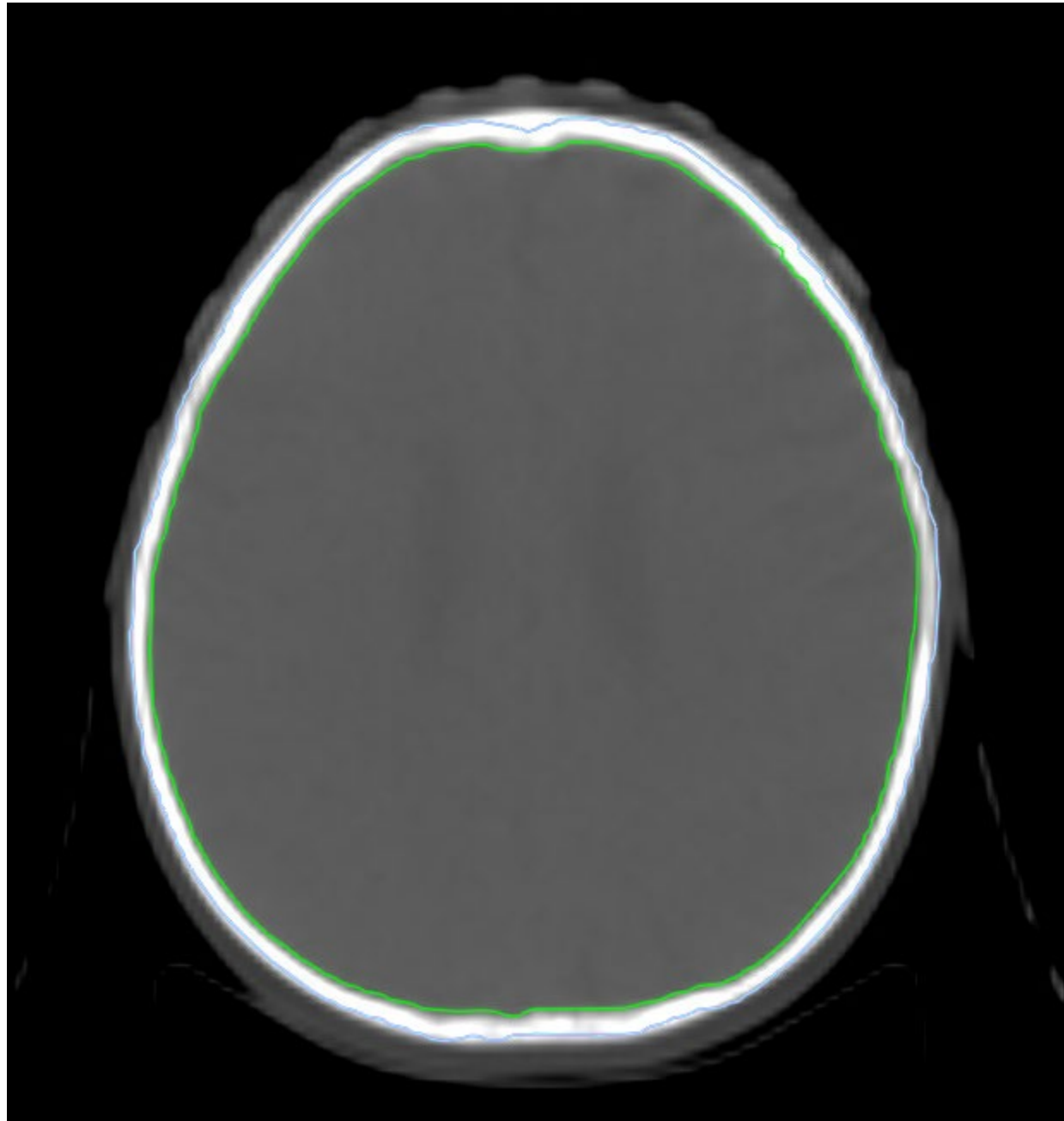


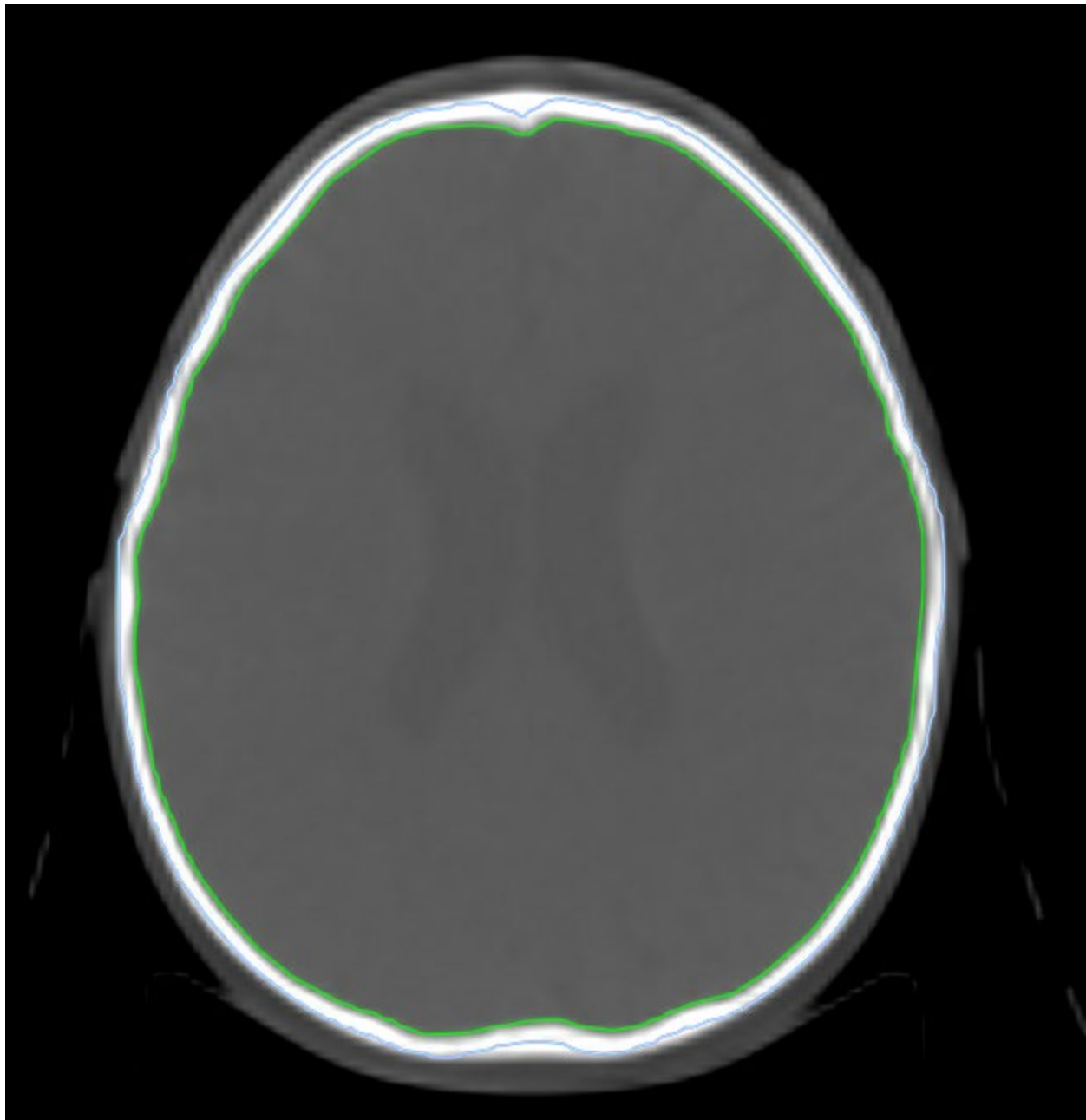


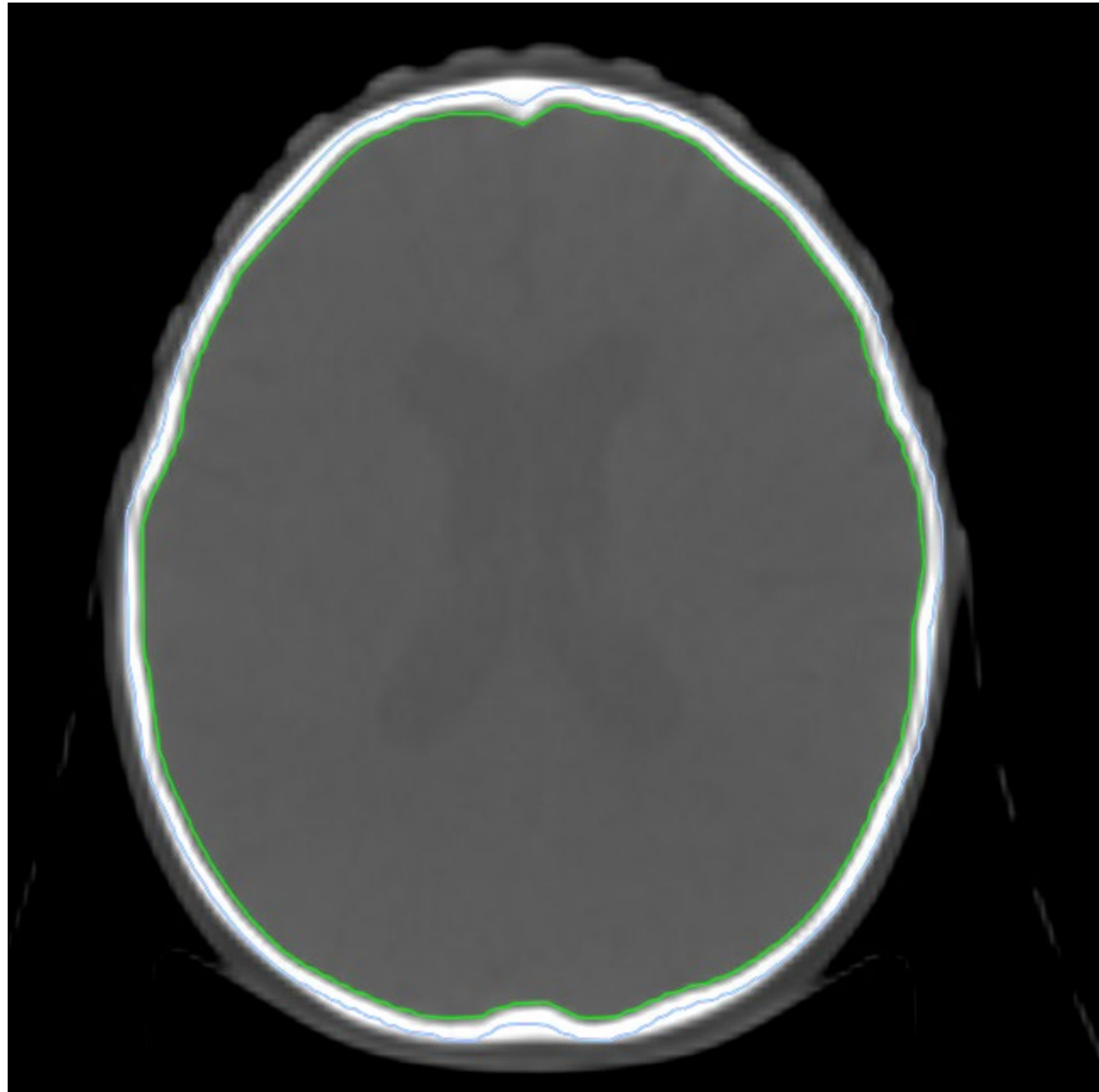


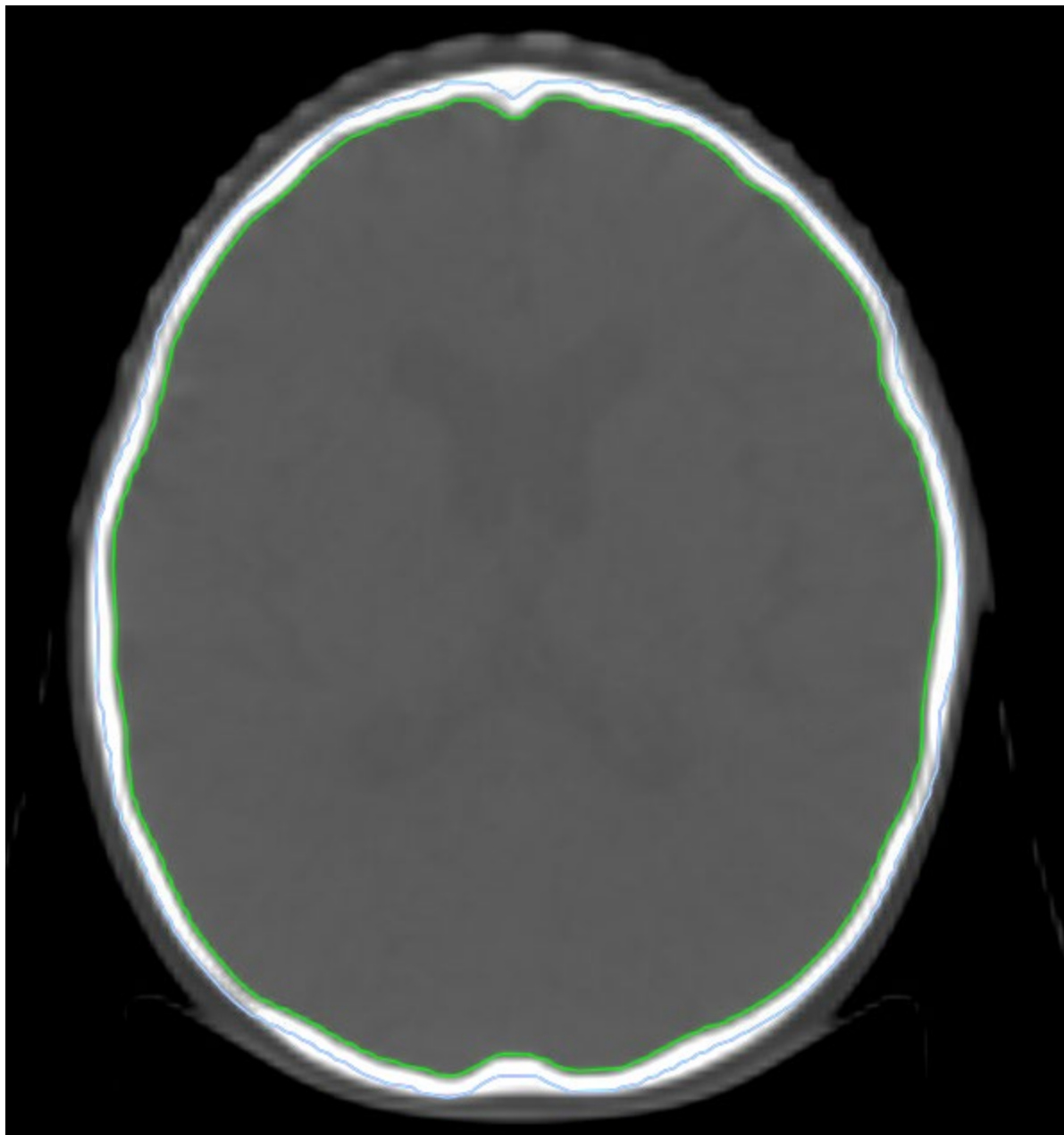


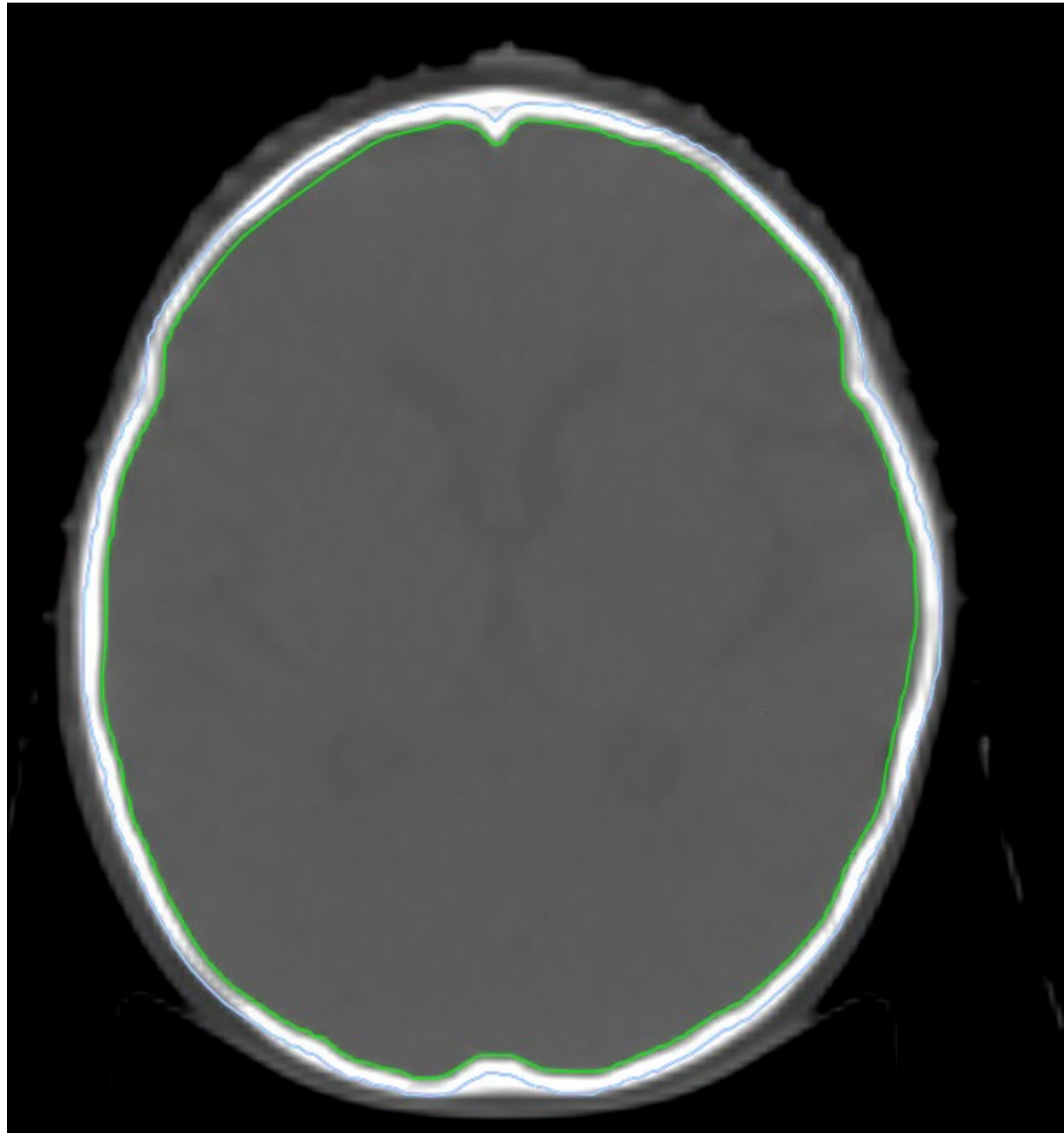


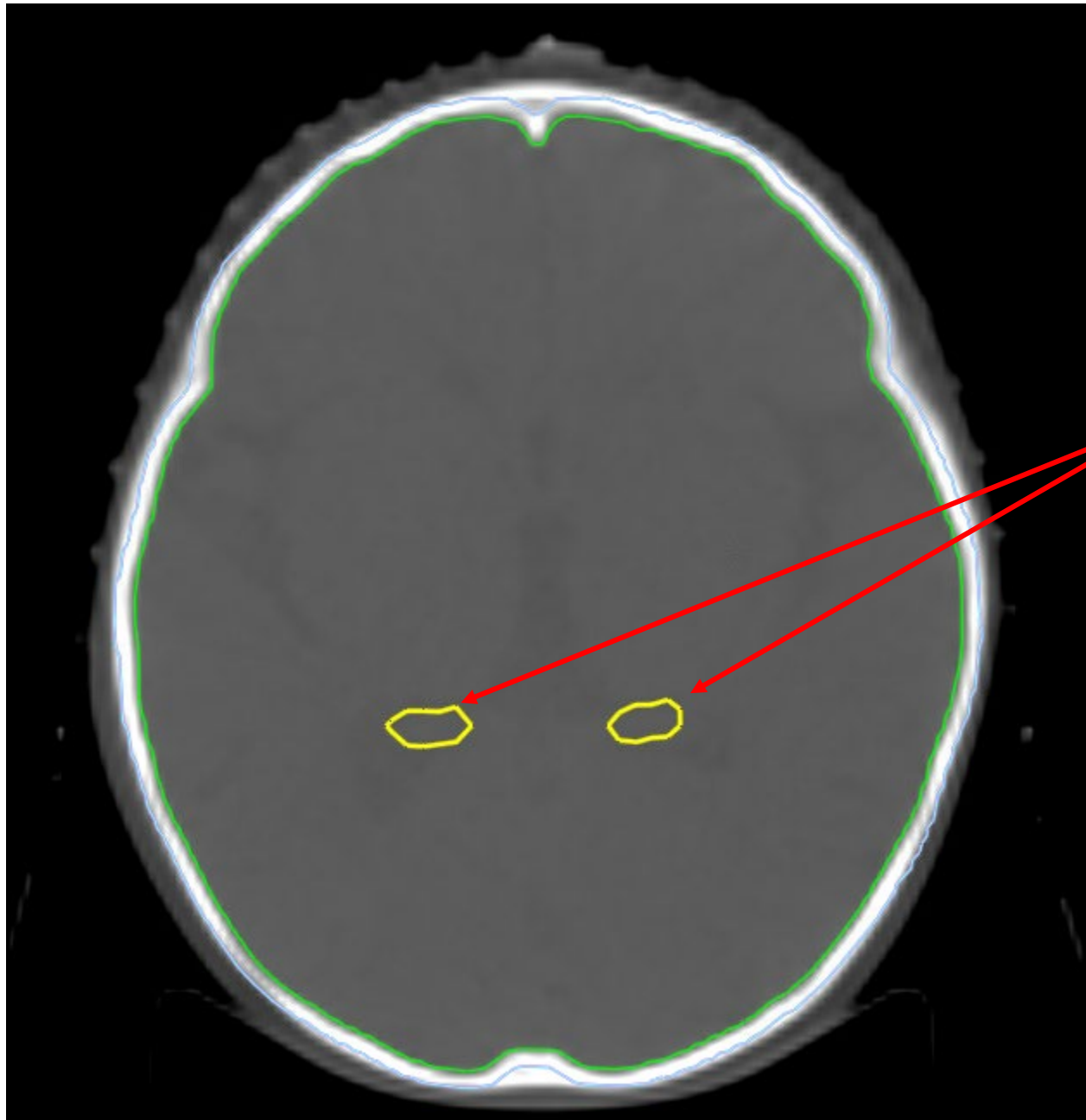




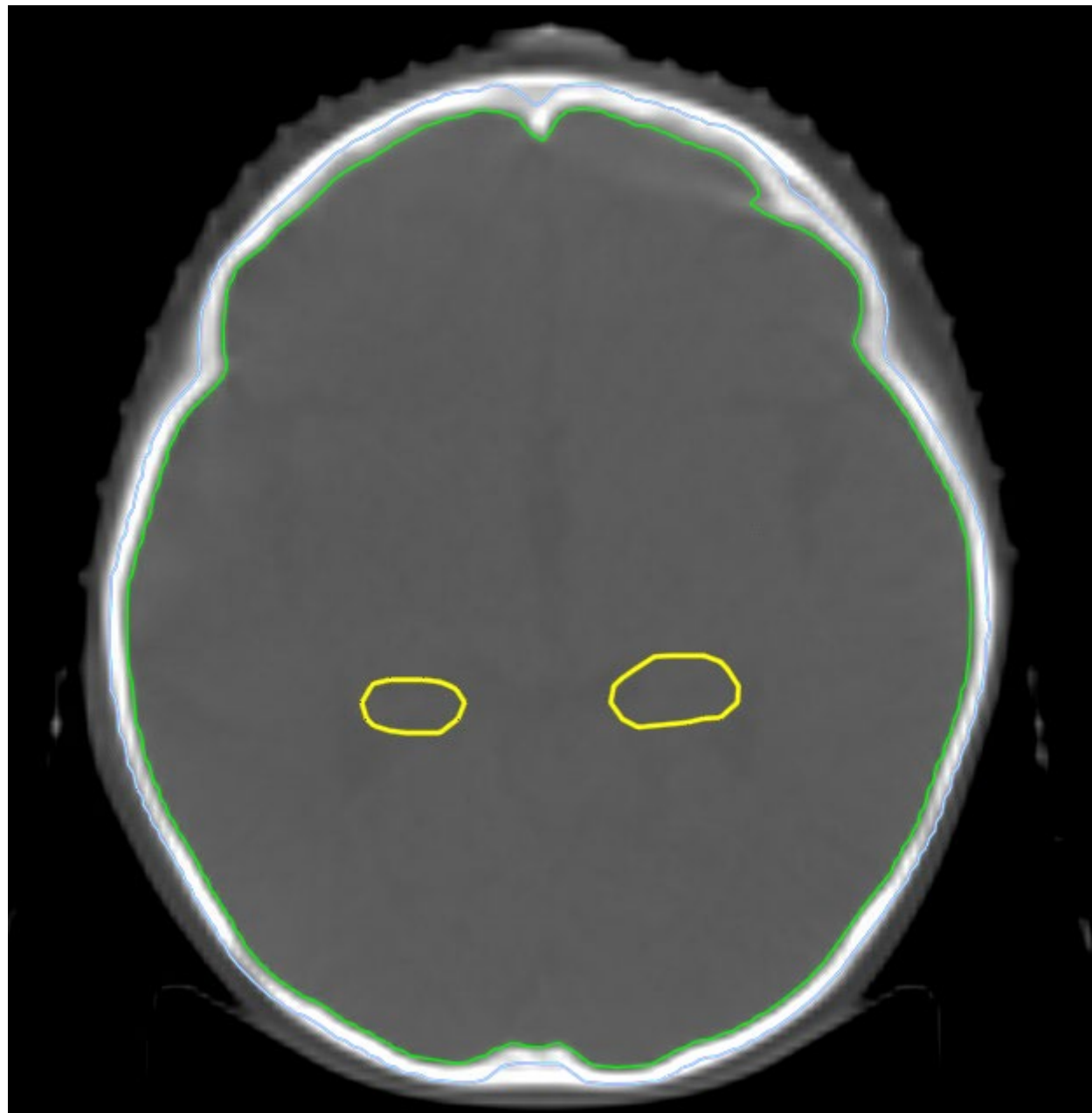


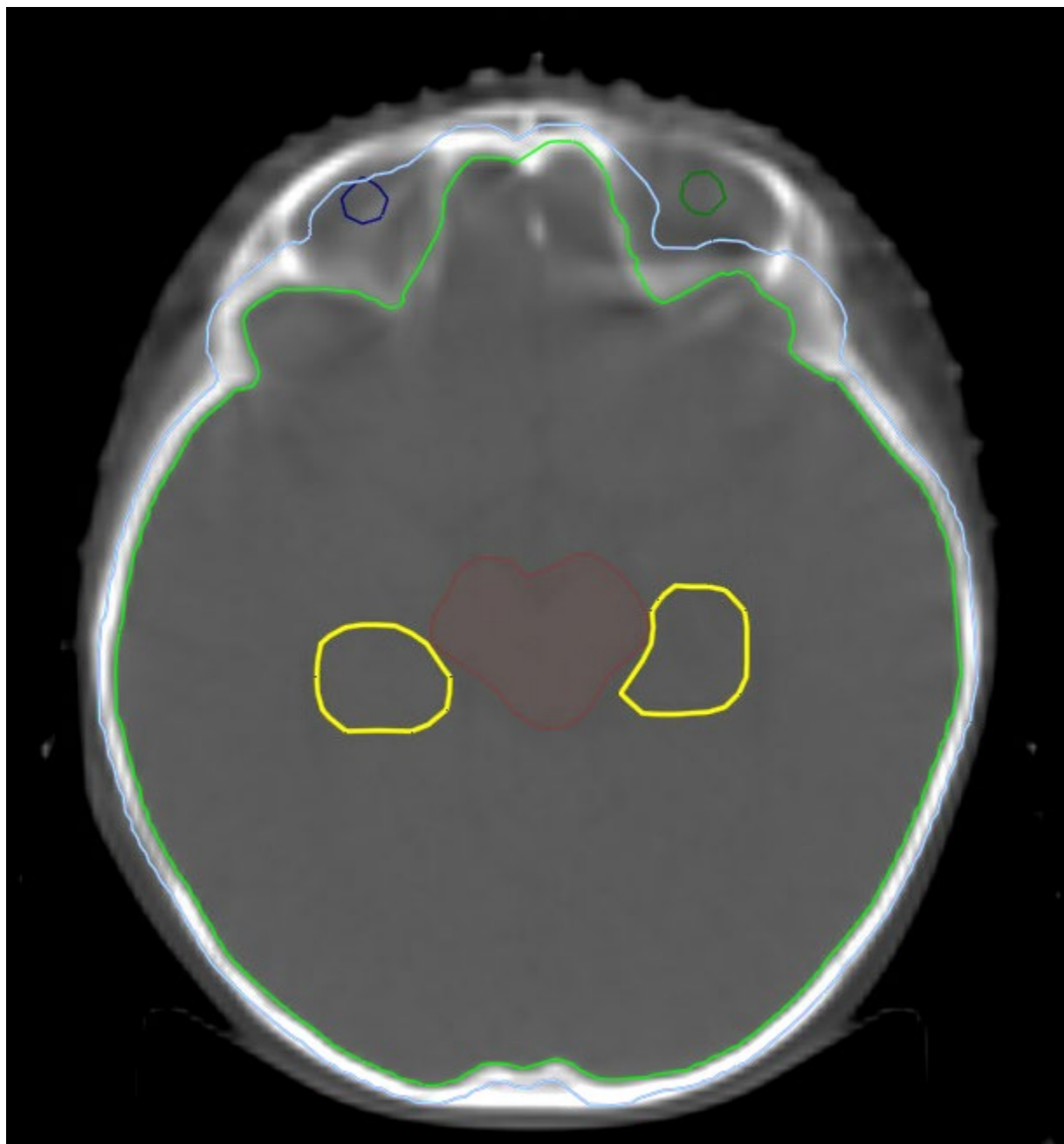




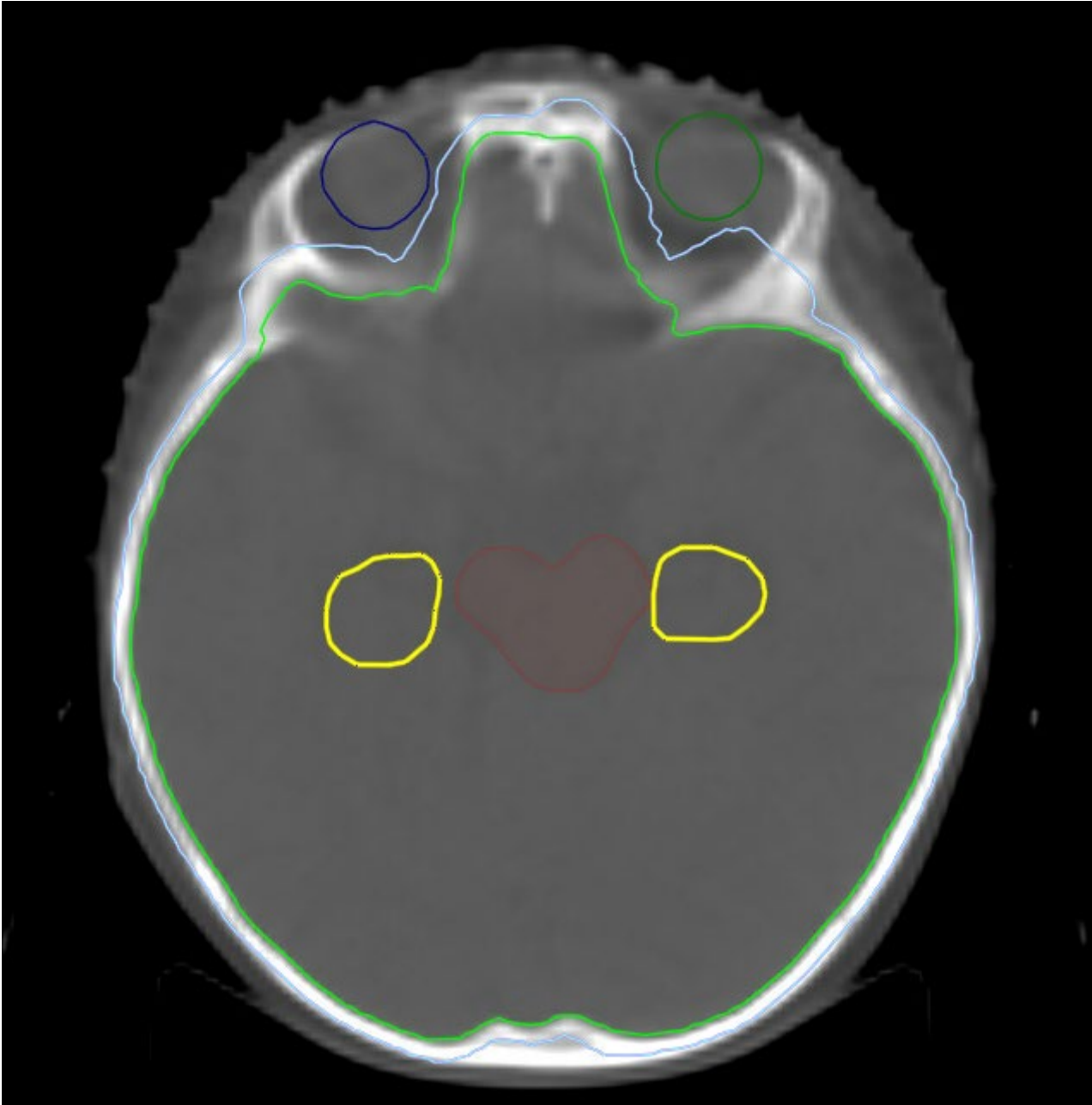


Hippocampi- yellow



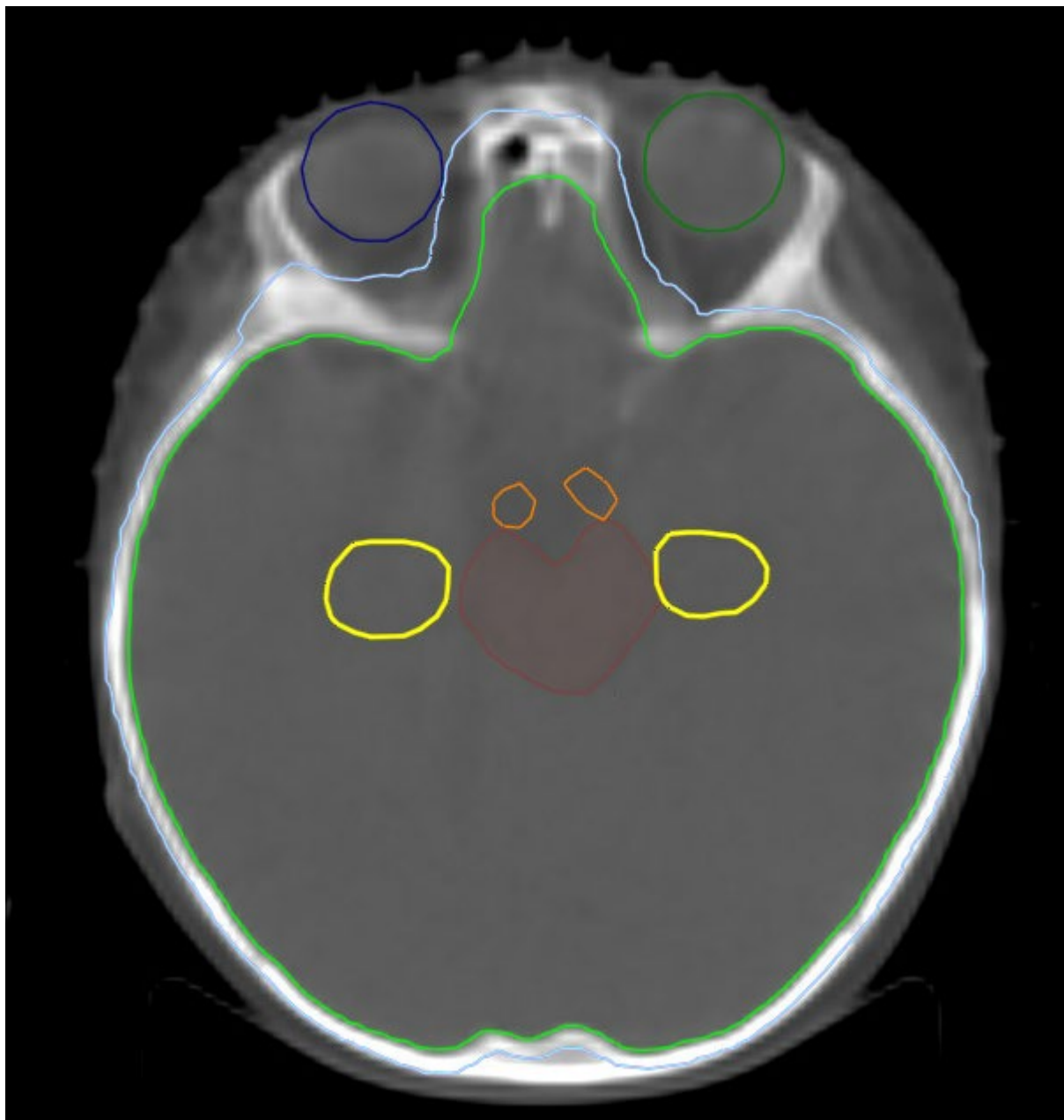


Right eye- Blue

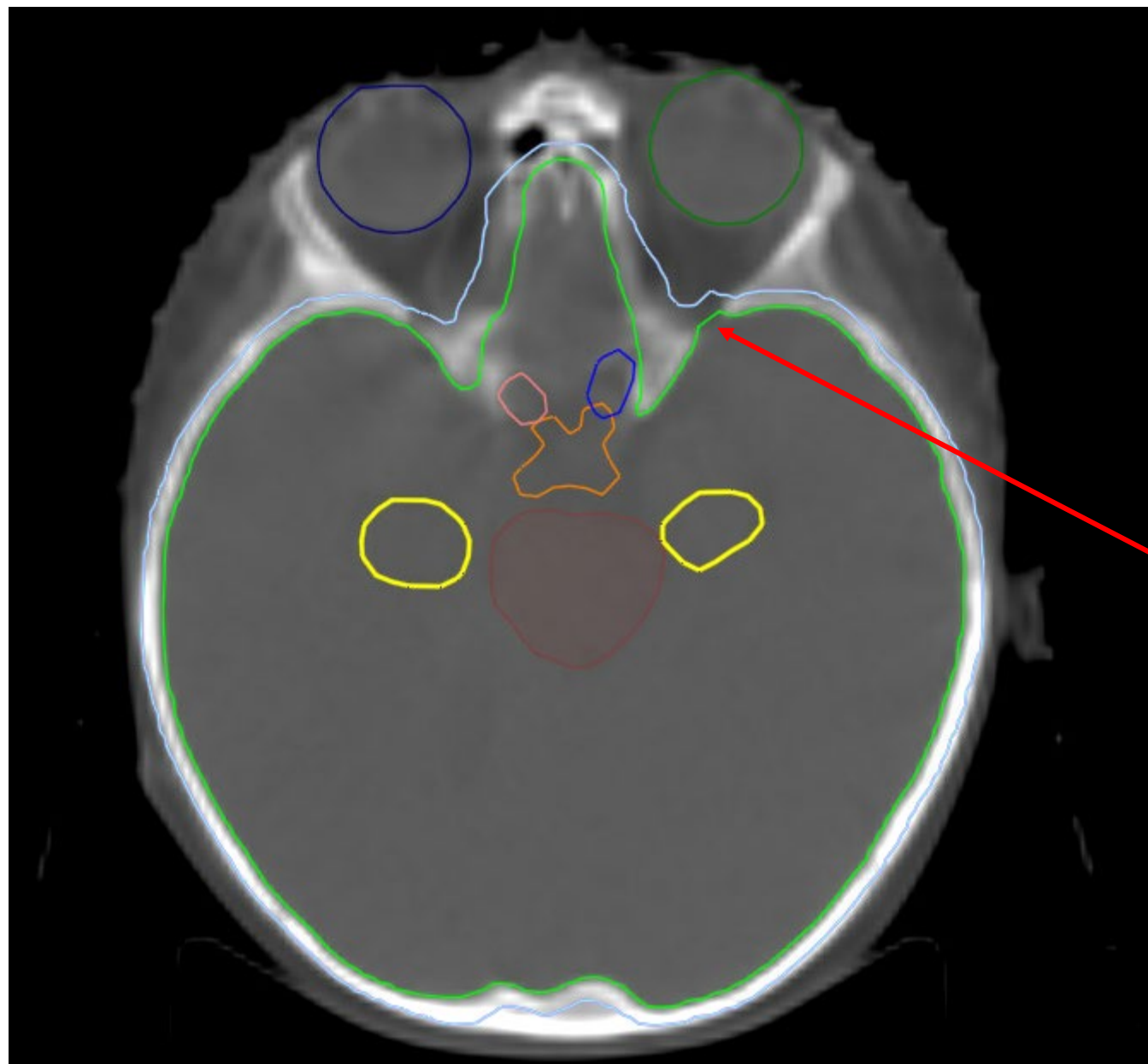


Left eye- Dark Green

Brainstem- Brown



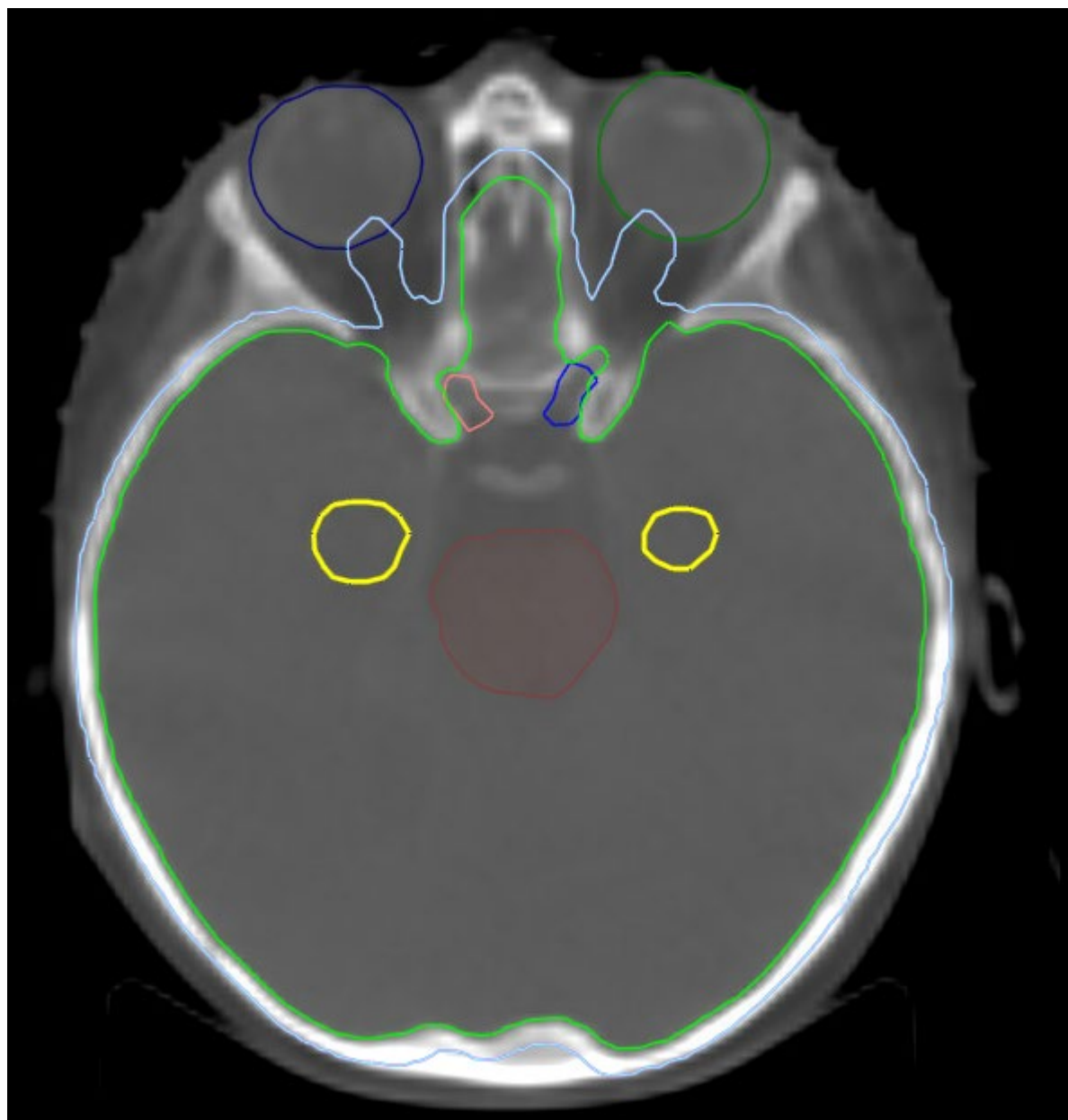
Right optic nerve- Pink



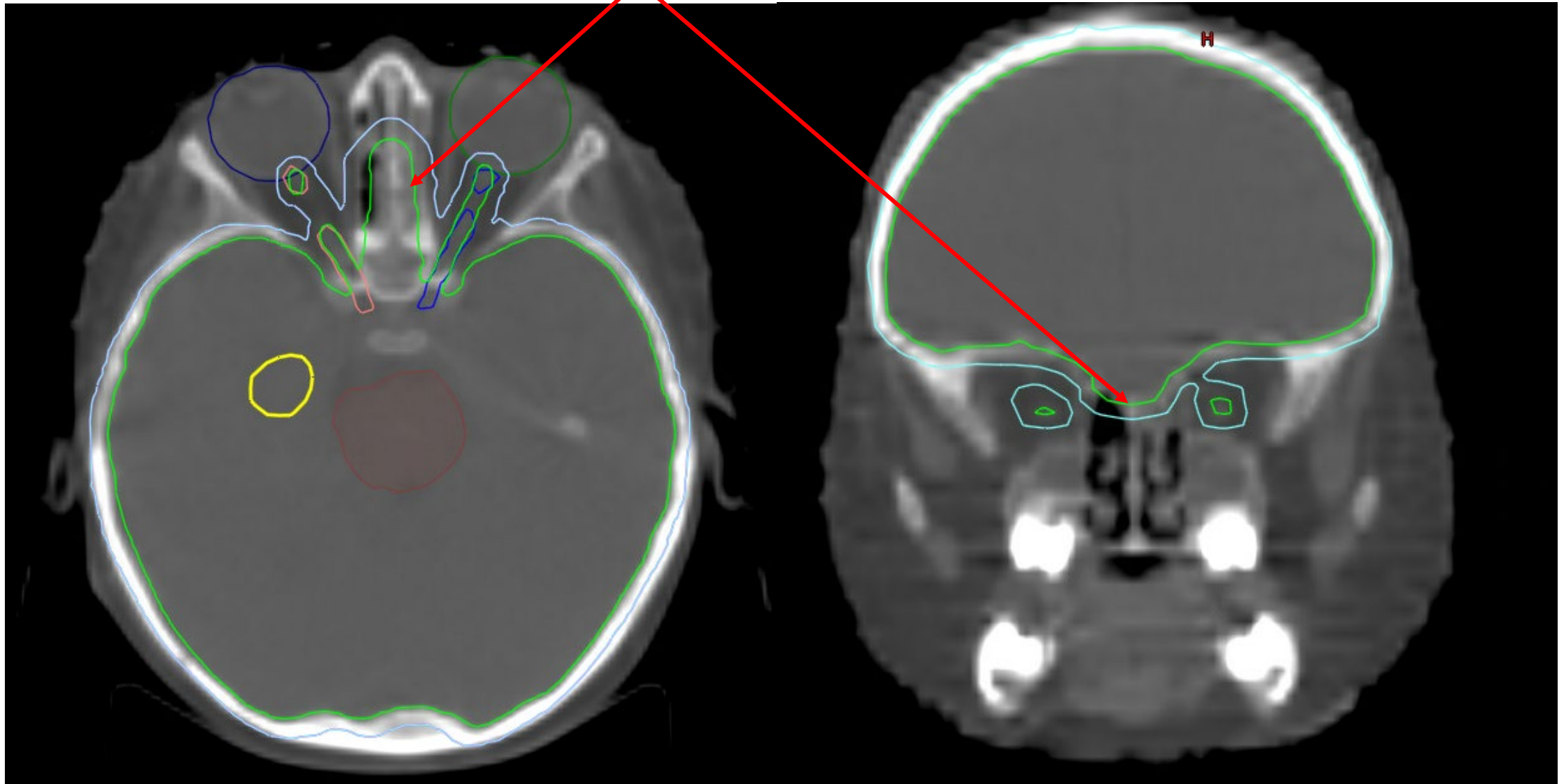
Left optic nerve- Blue

Optic Chiasm- Orange

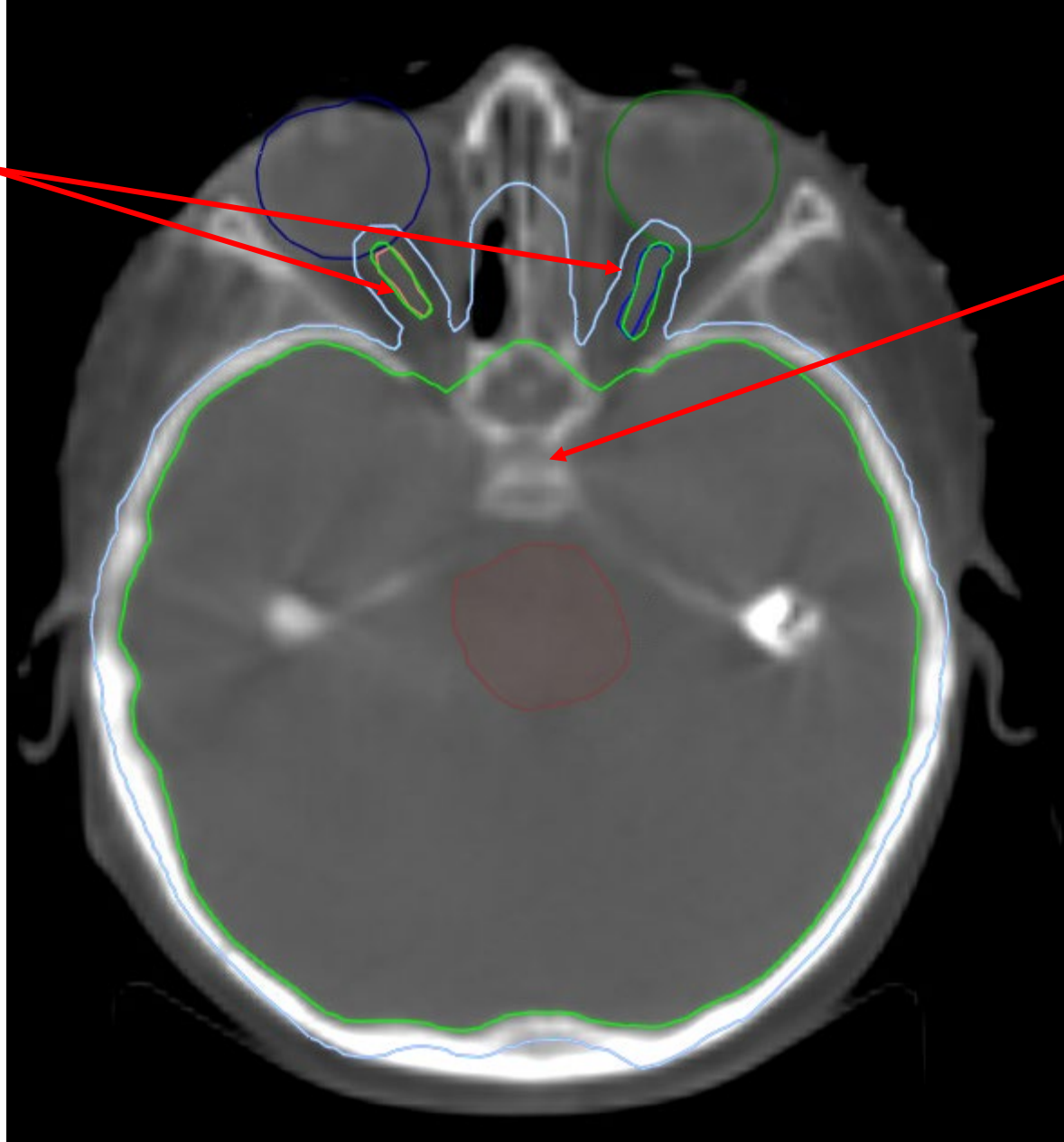
Superior Orbital fissure



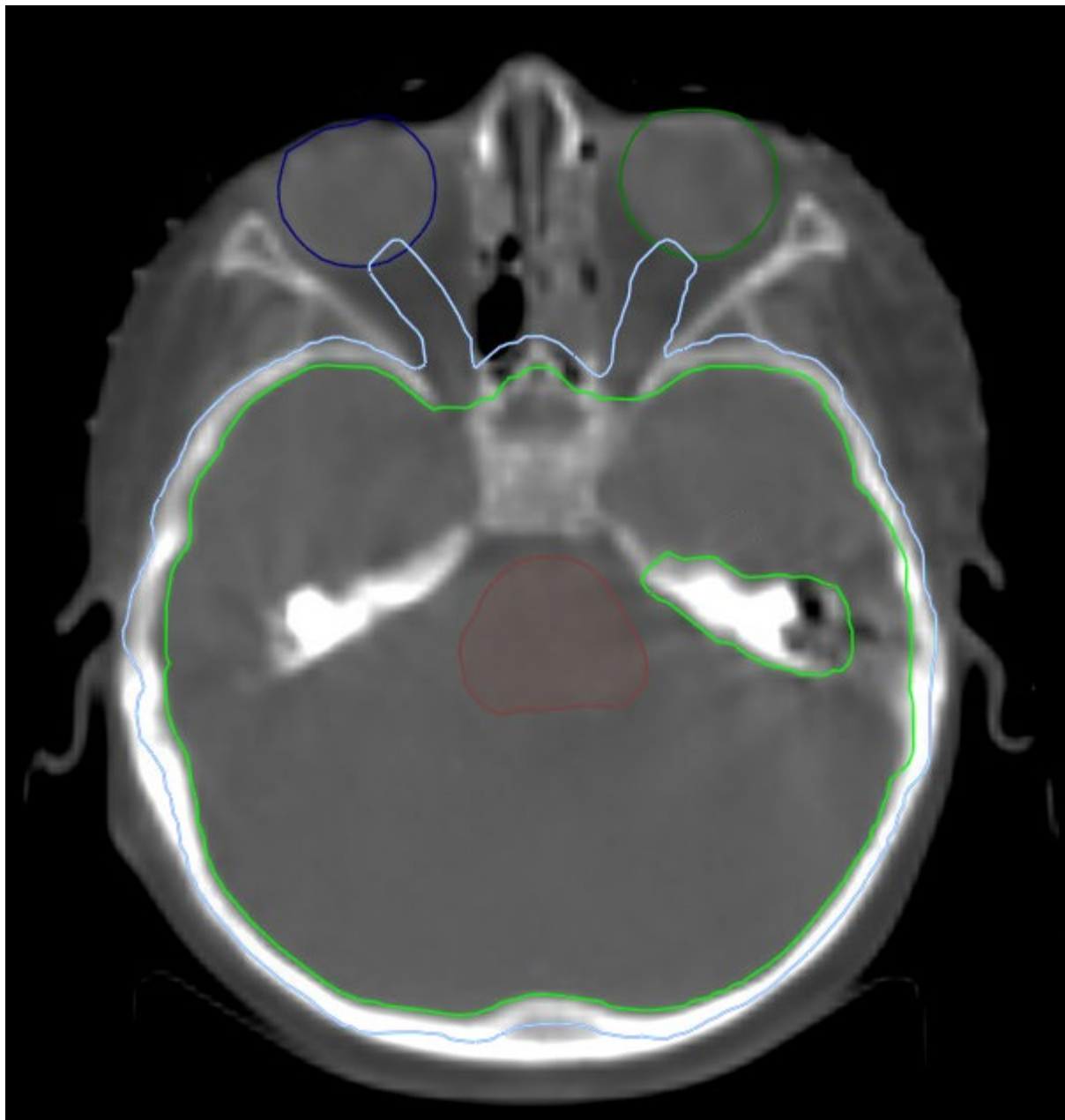
CTV includes the Cribriform plate drawn on the bone window



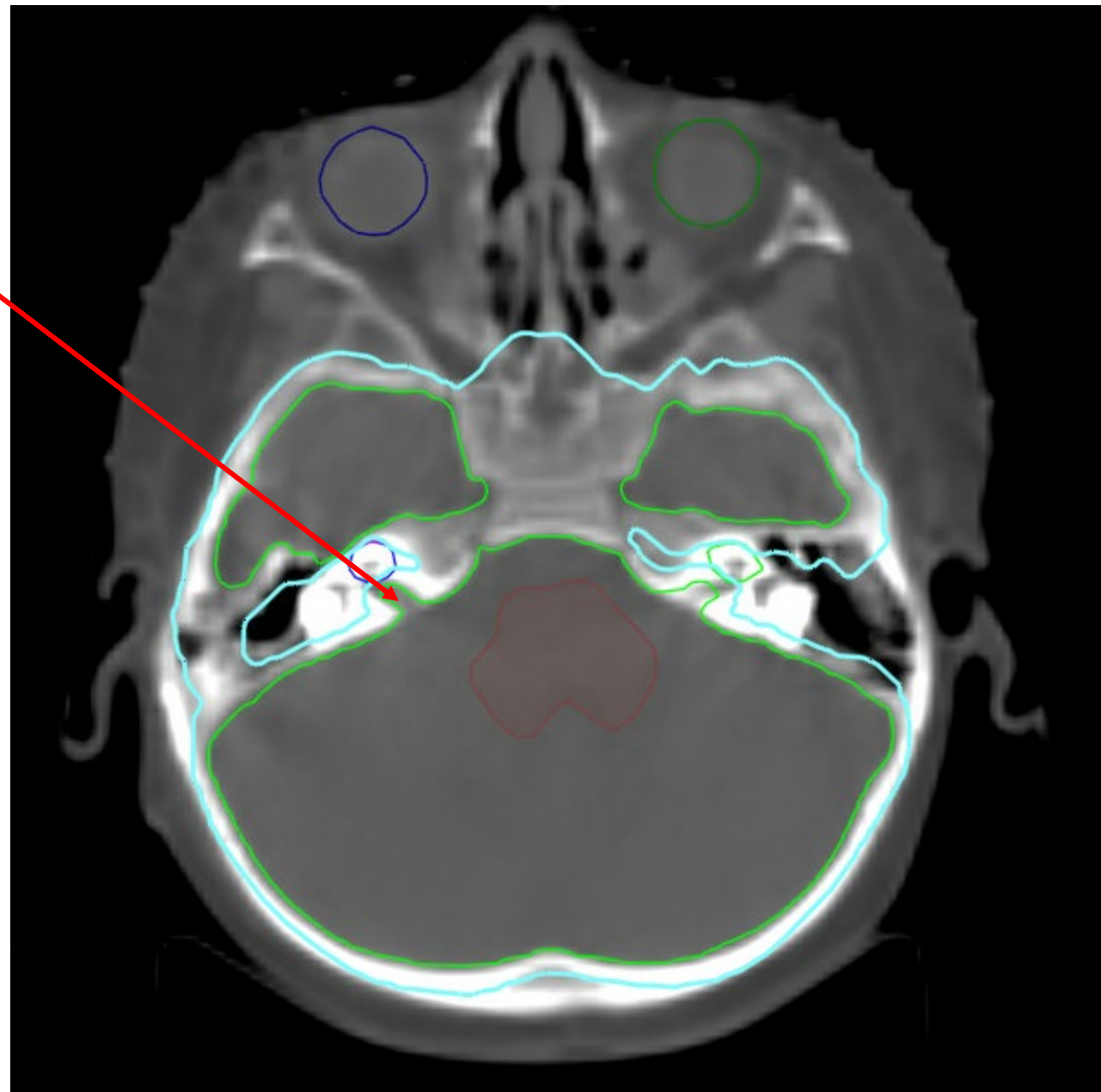
CTV includes the optic nerves



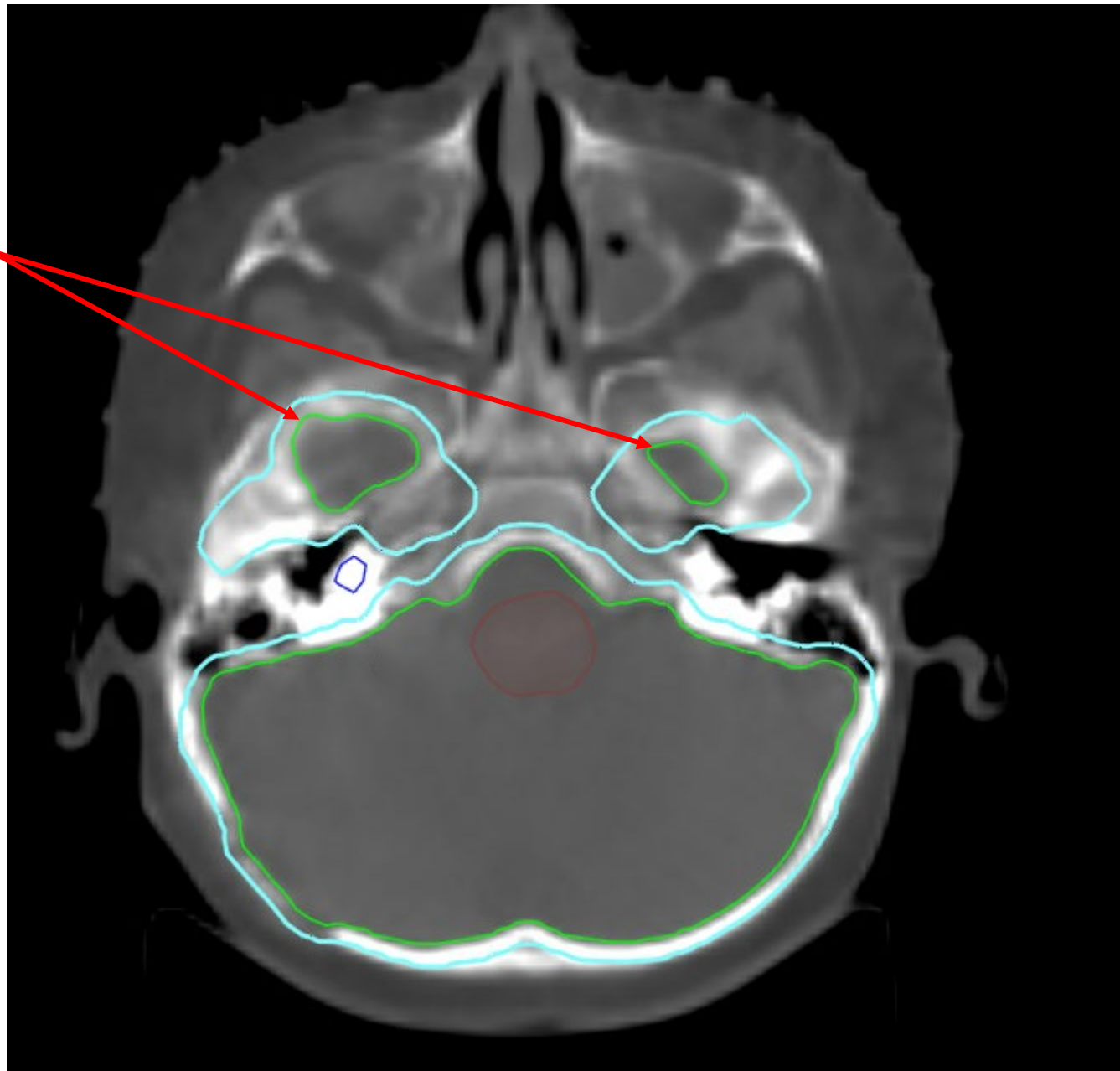
Pituitary Fossa included
in CTV_Brain

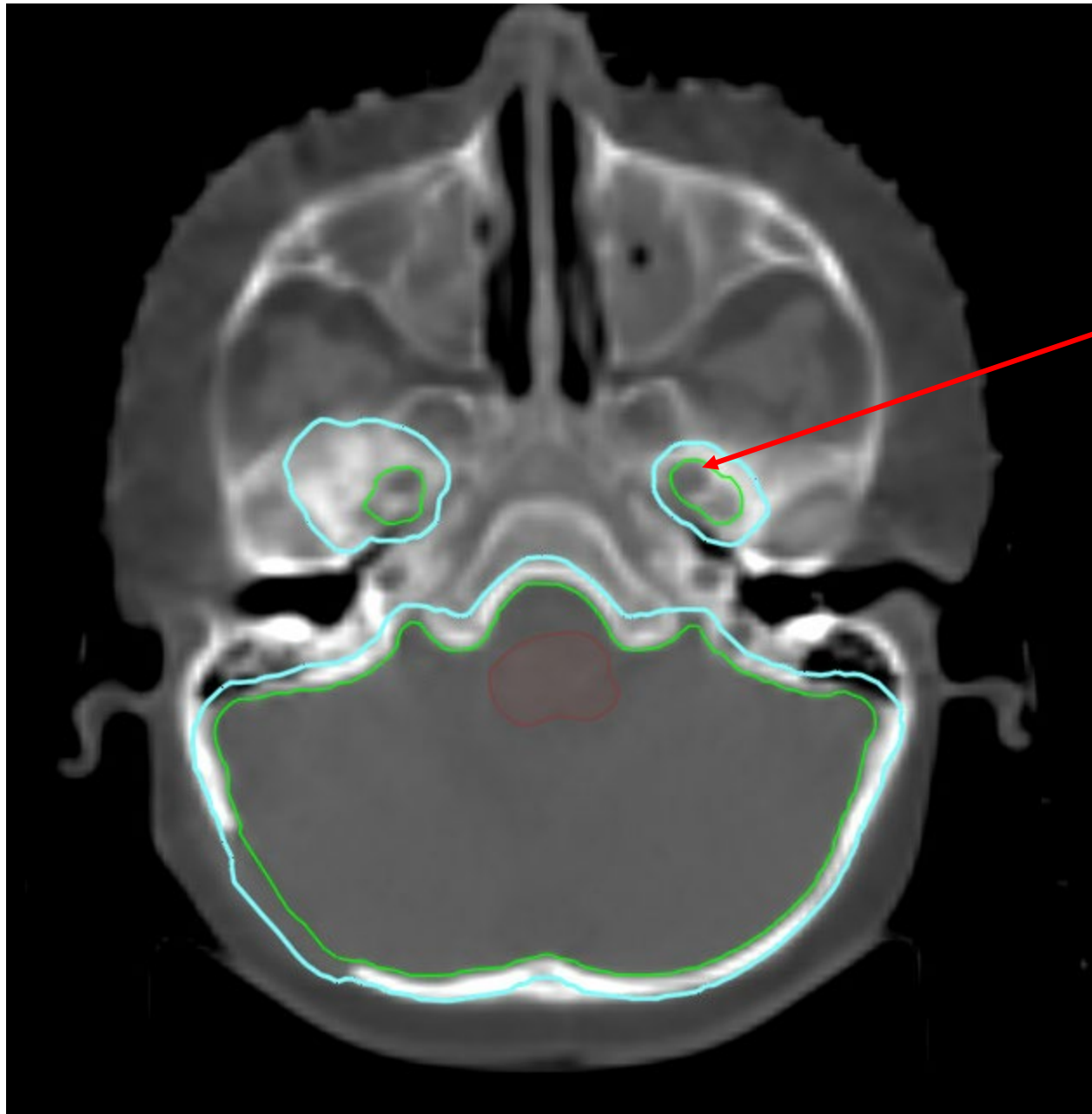


Internal Auditory meatus



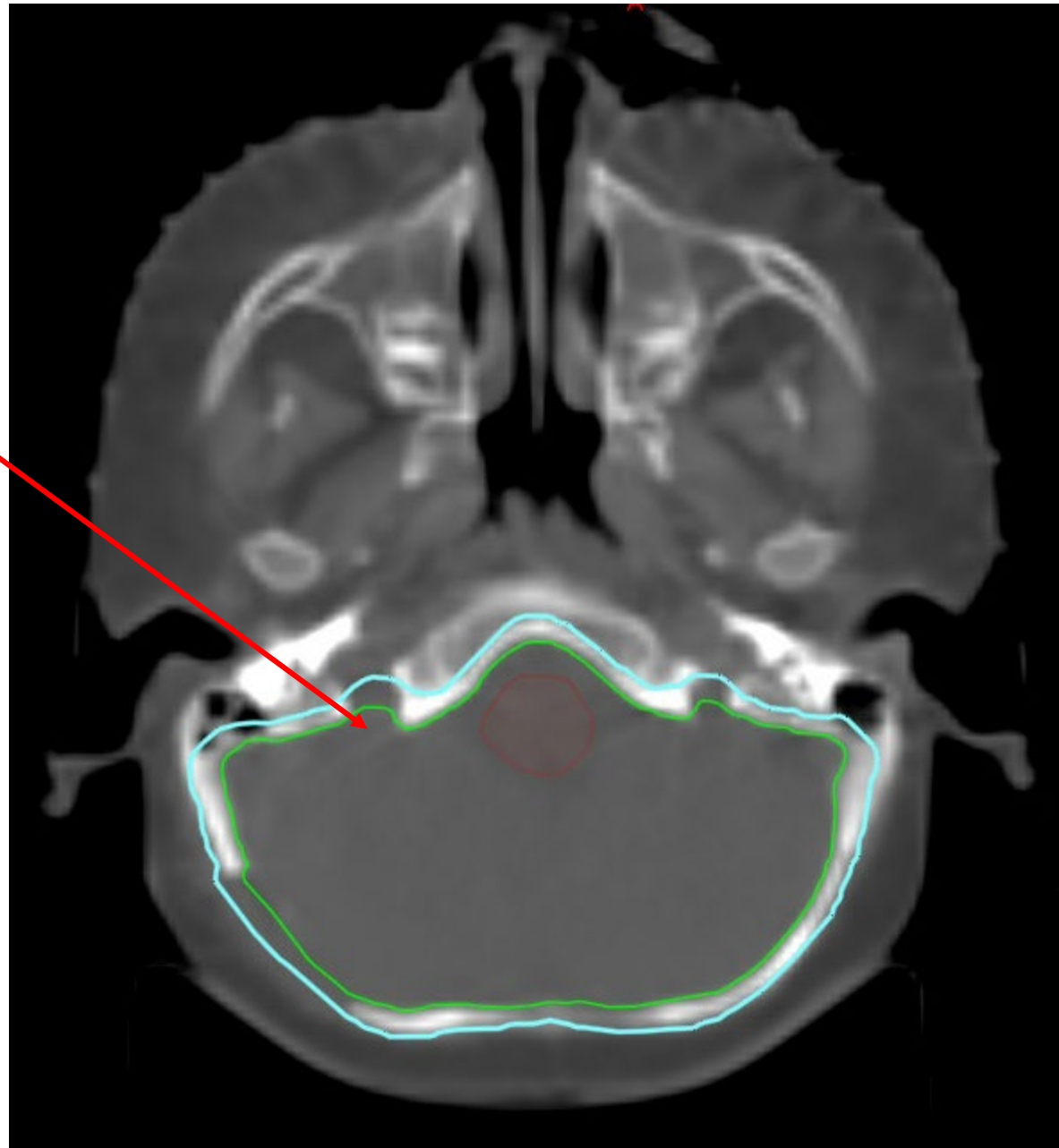
Inferior slices of the middle cranial fossae drawn on the bone window must be included in the CTV_brain



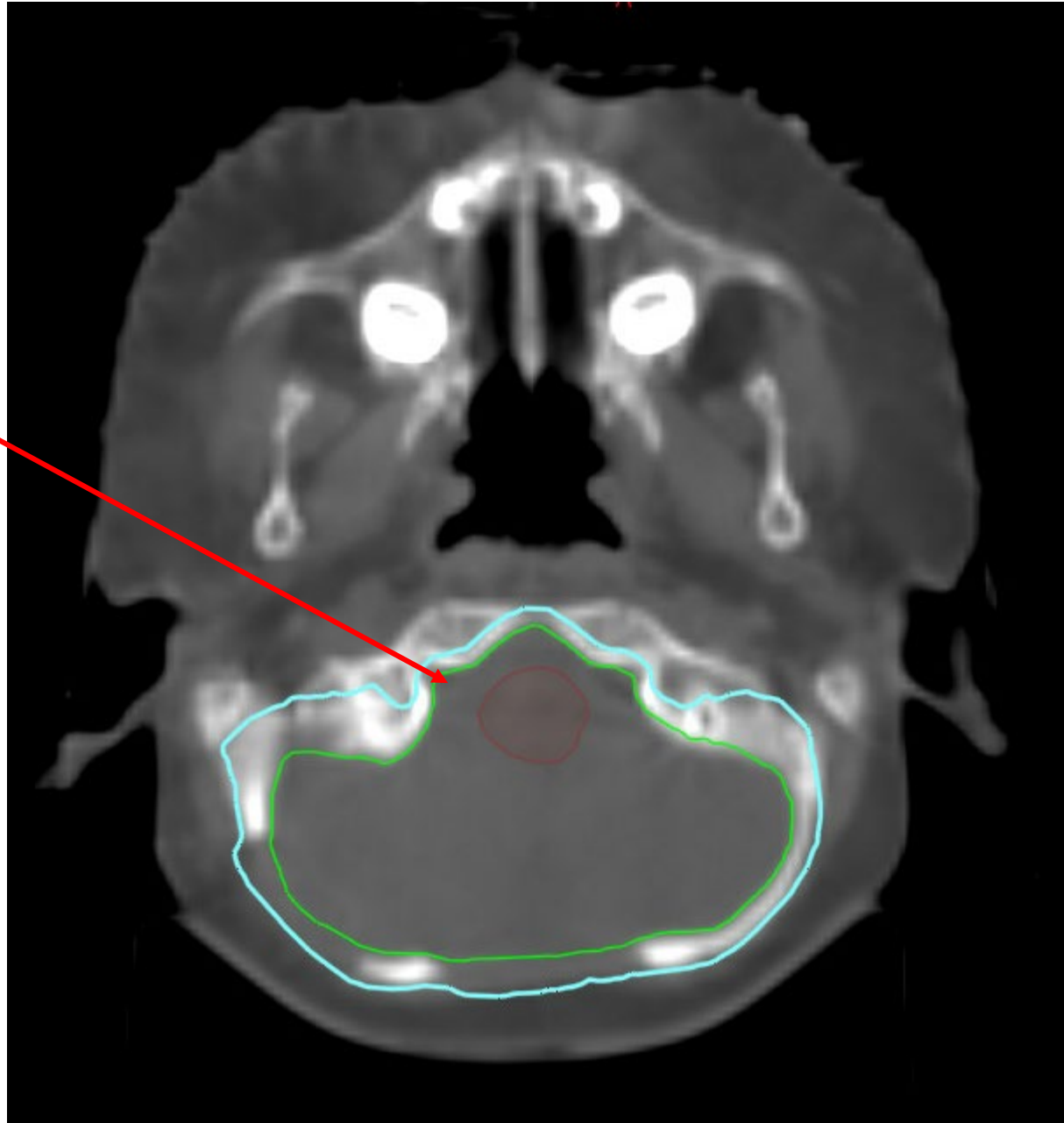


Foramen Ovale

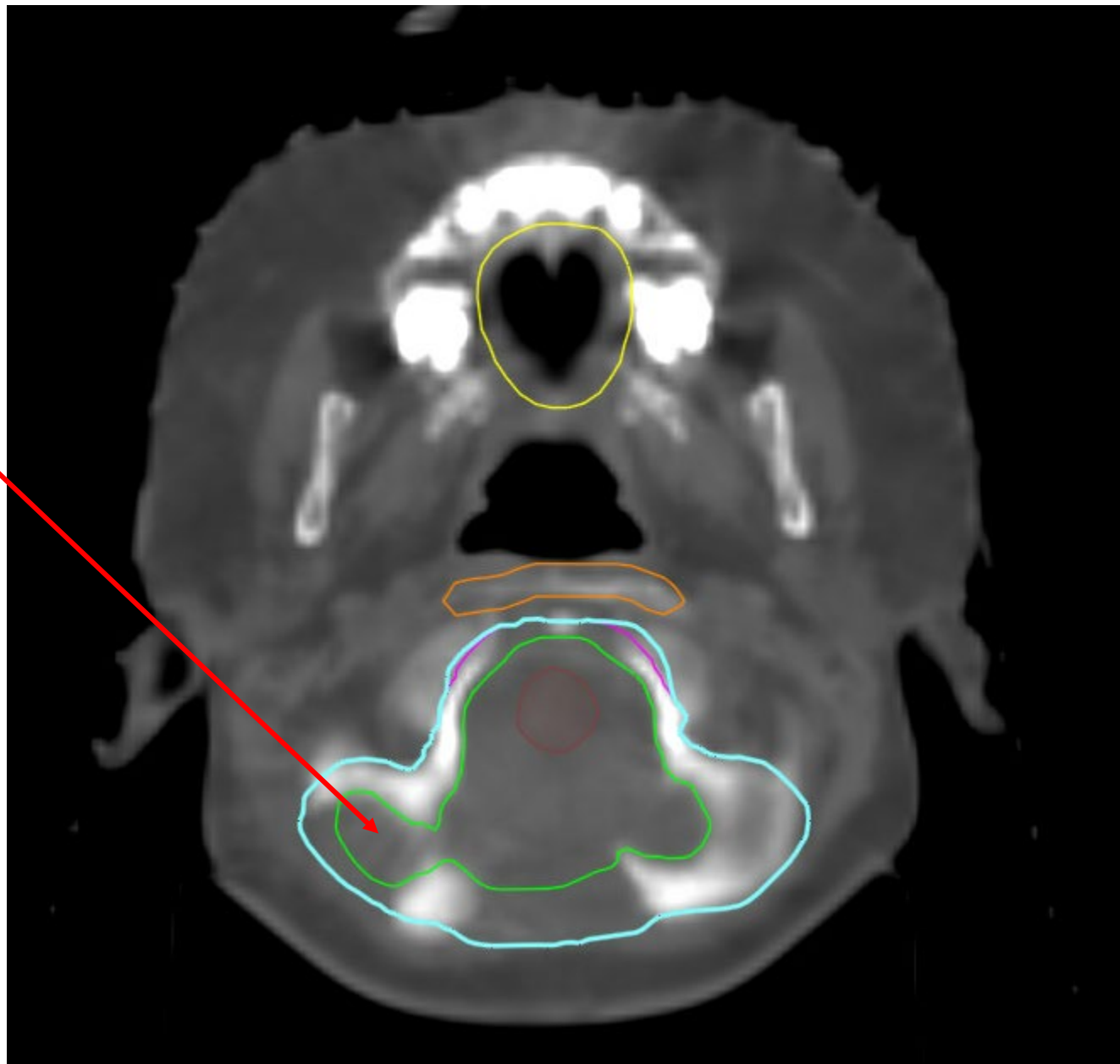
Jugular foramen



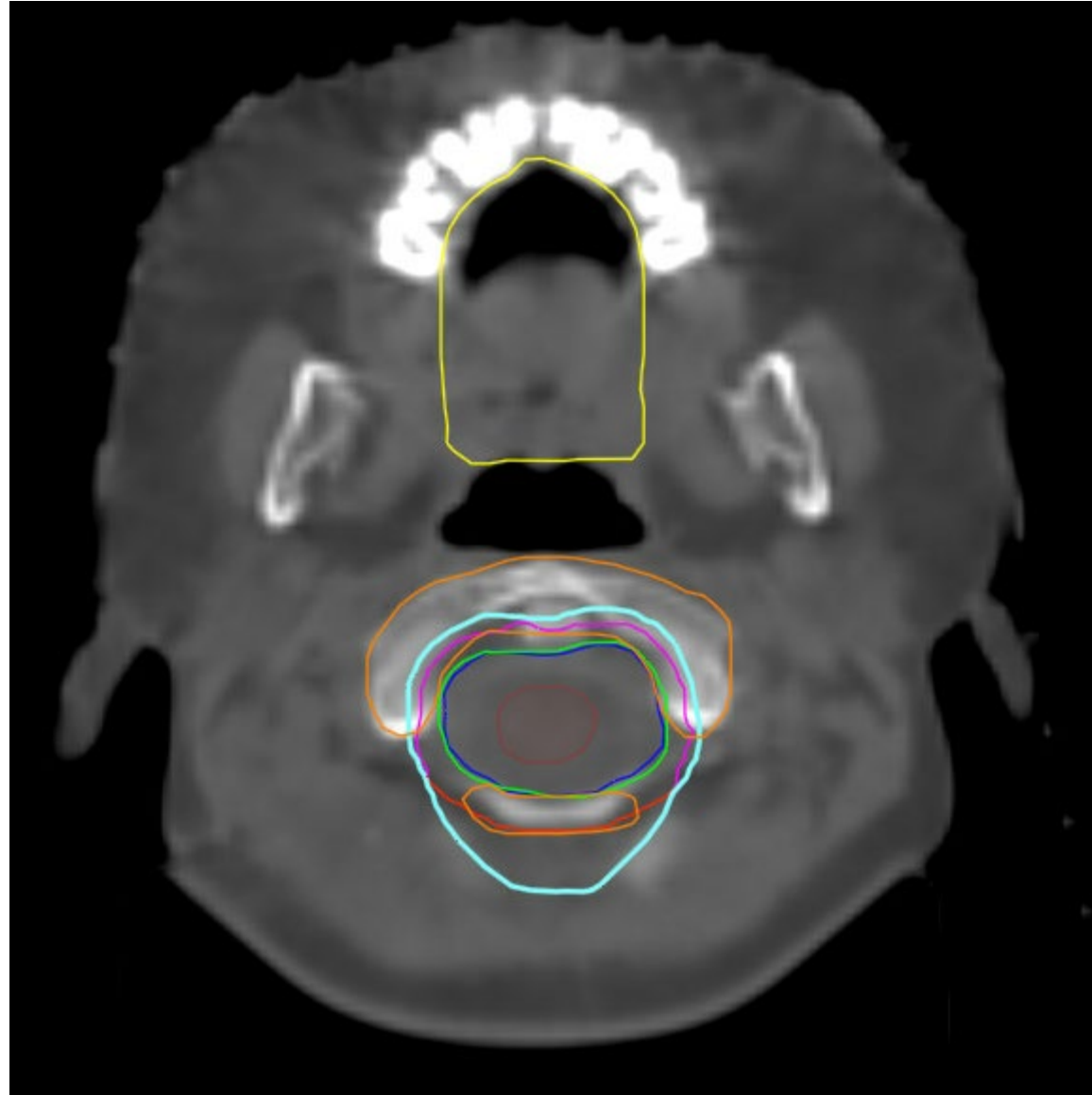
Hypoglossal canal



Cover the inferior cerebellum on bone window

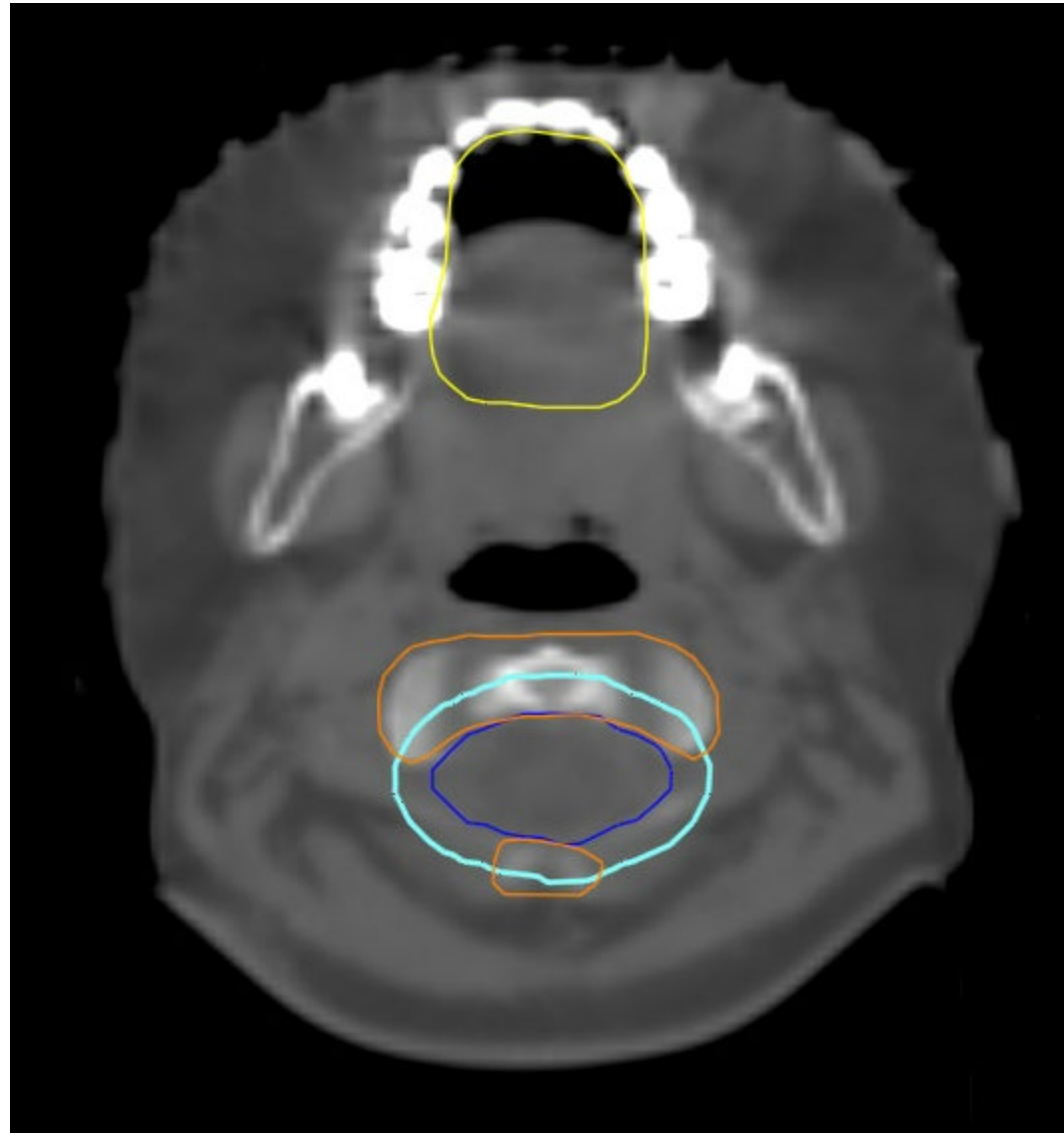


Oral cavity- yellow



Vertebral bodies- Orange

Vertebral bodies- Orange



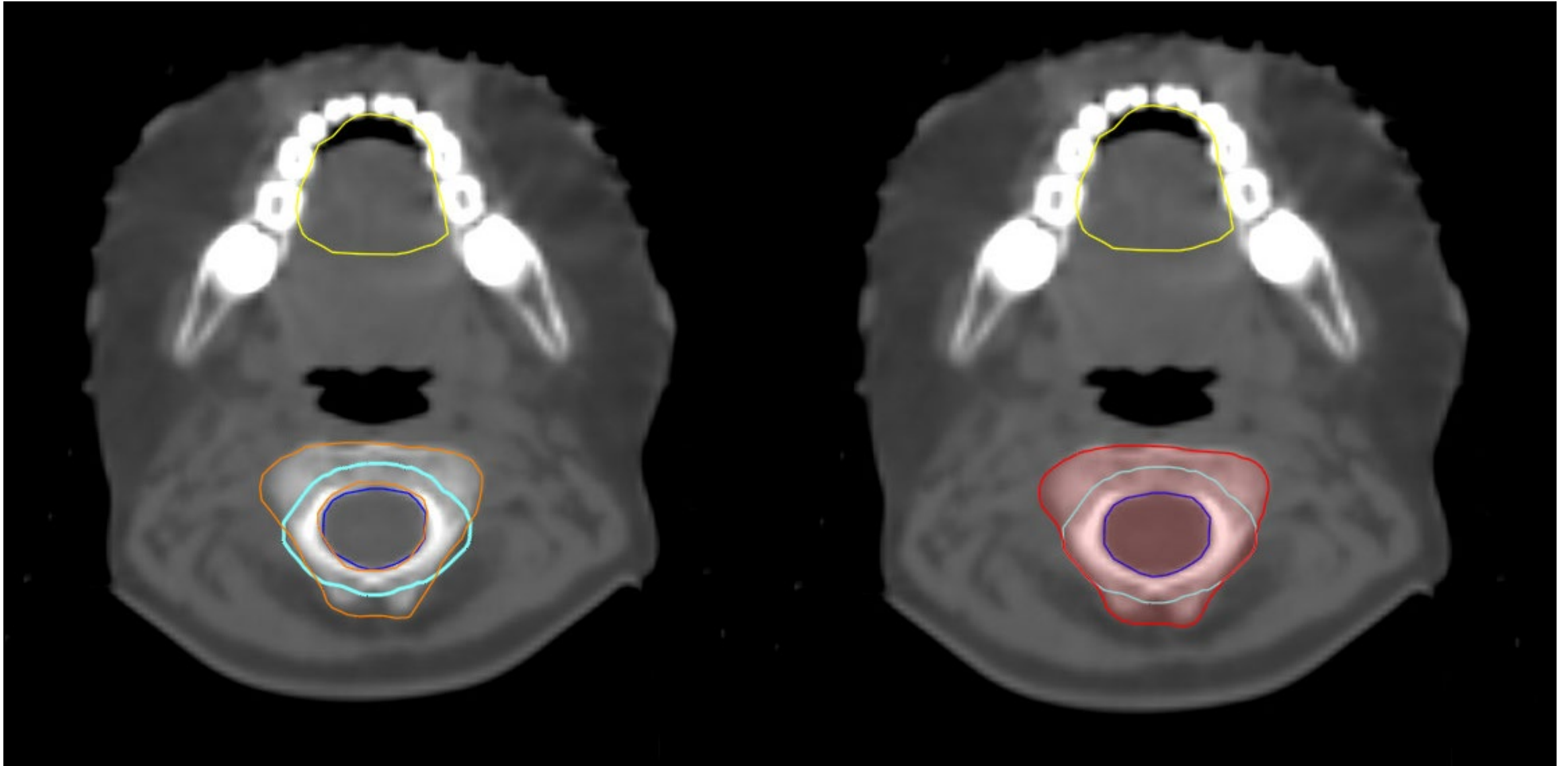
PTV_CSI_2340_cyan

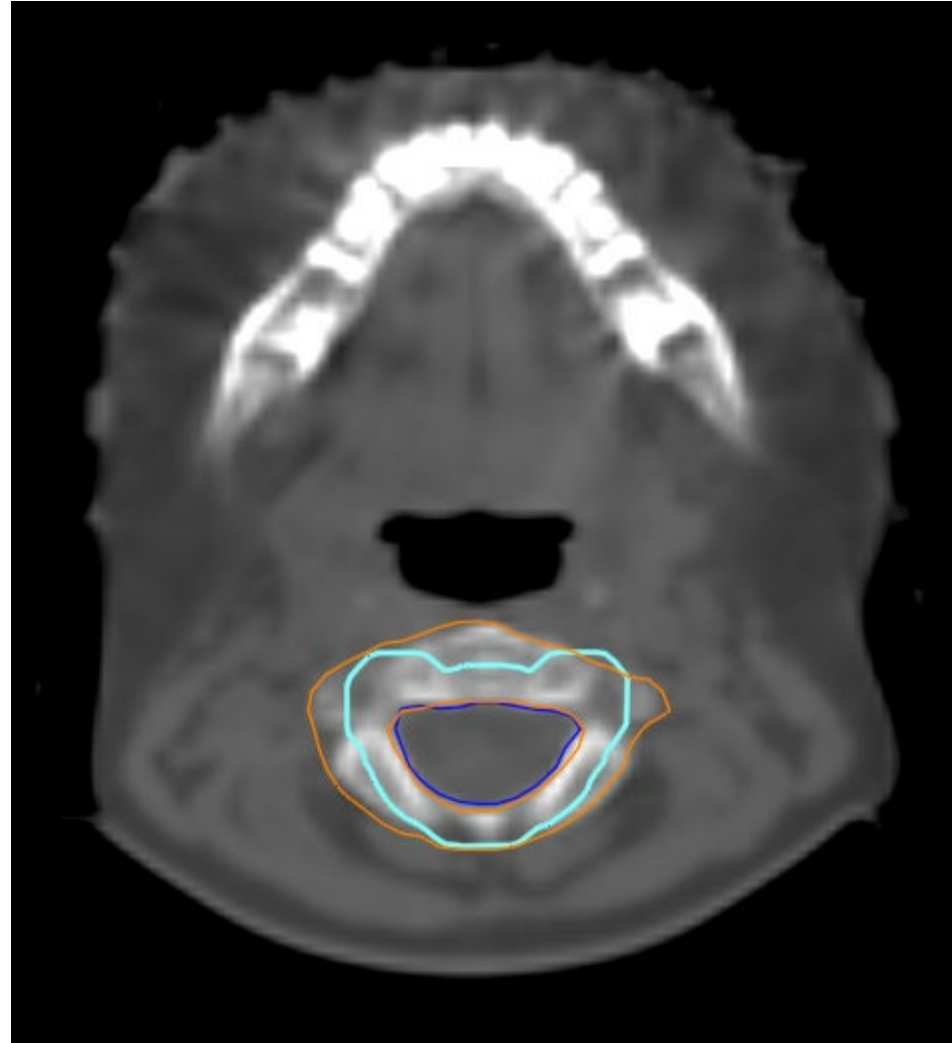
CTV_Spine- Dark Blue

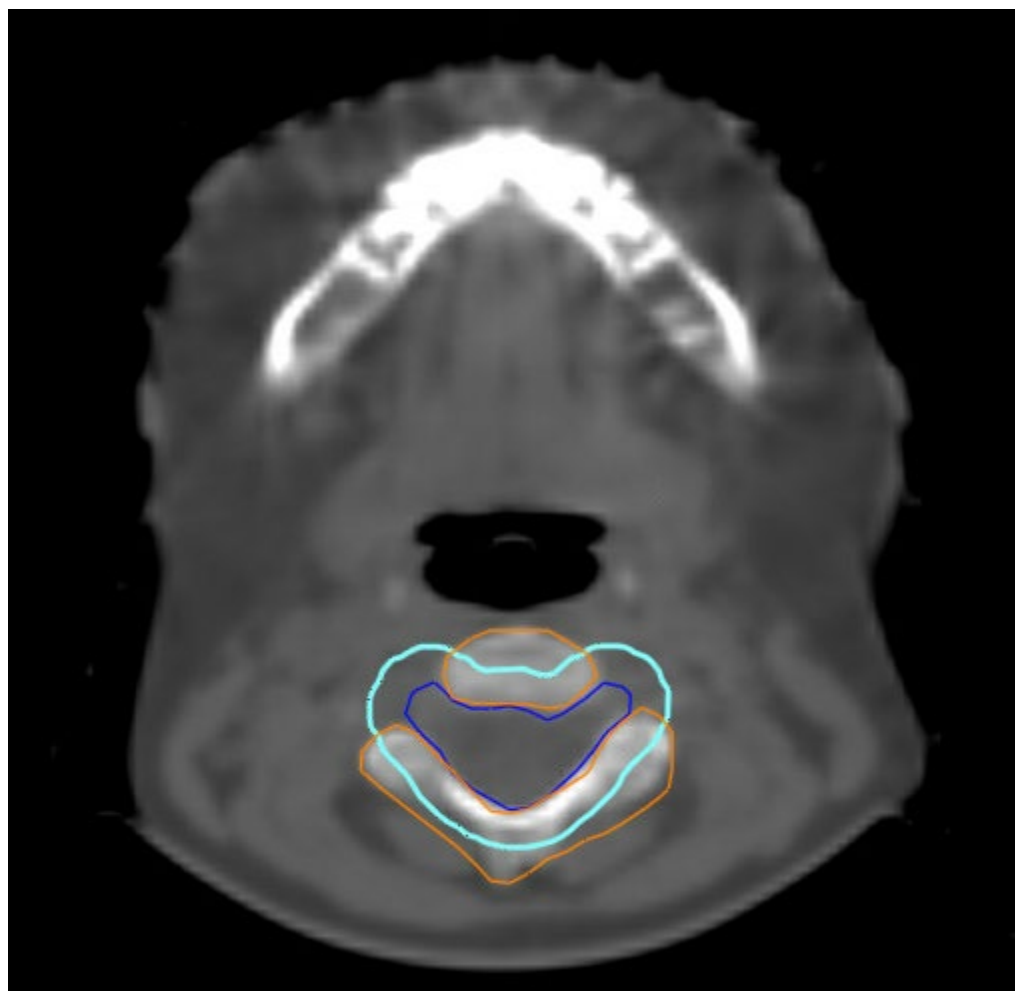
Vertebral Body Sparing

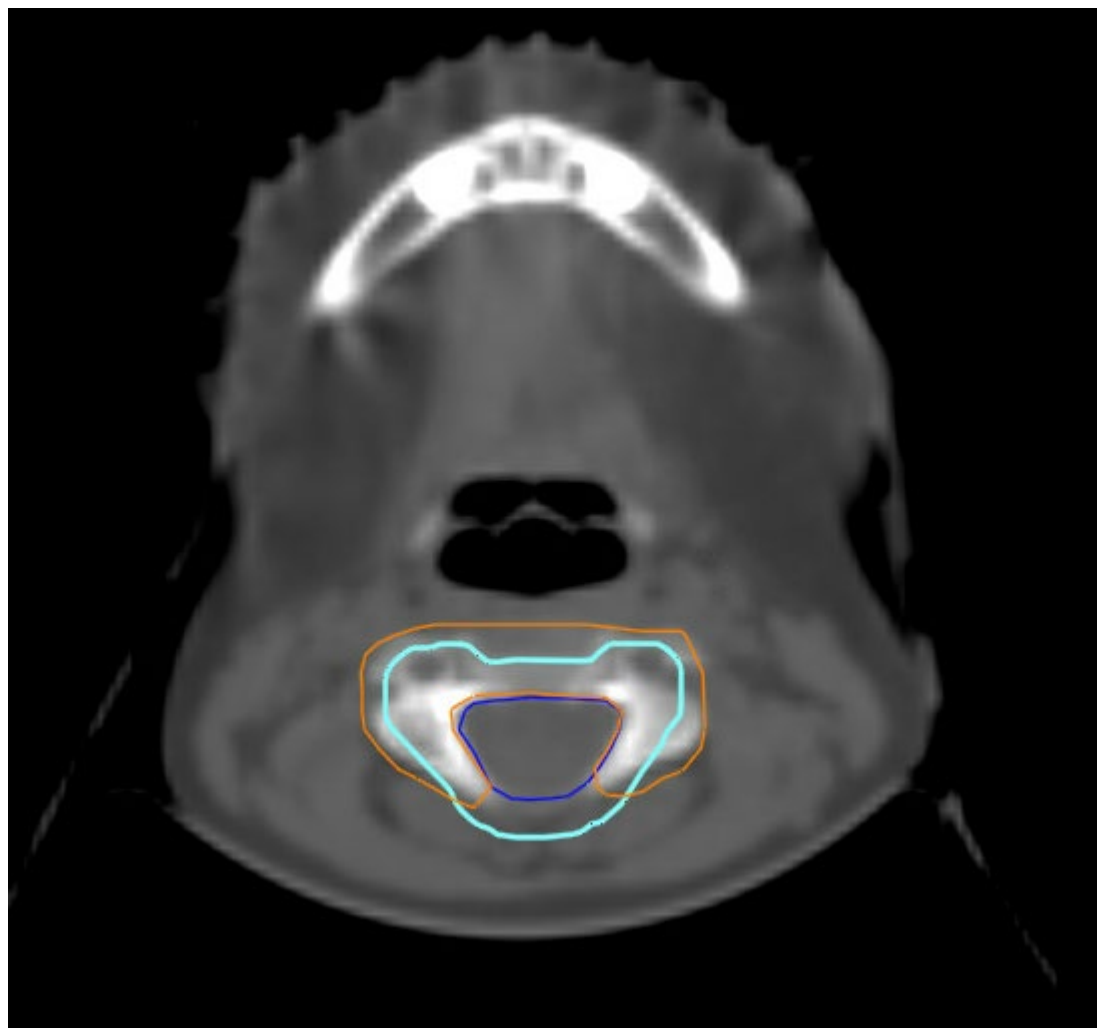
Non- Vertebral Body Sparing

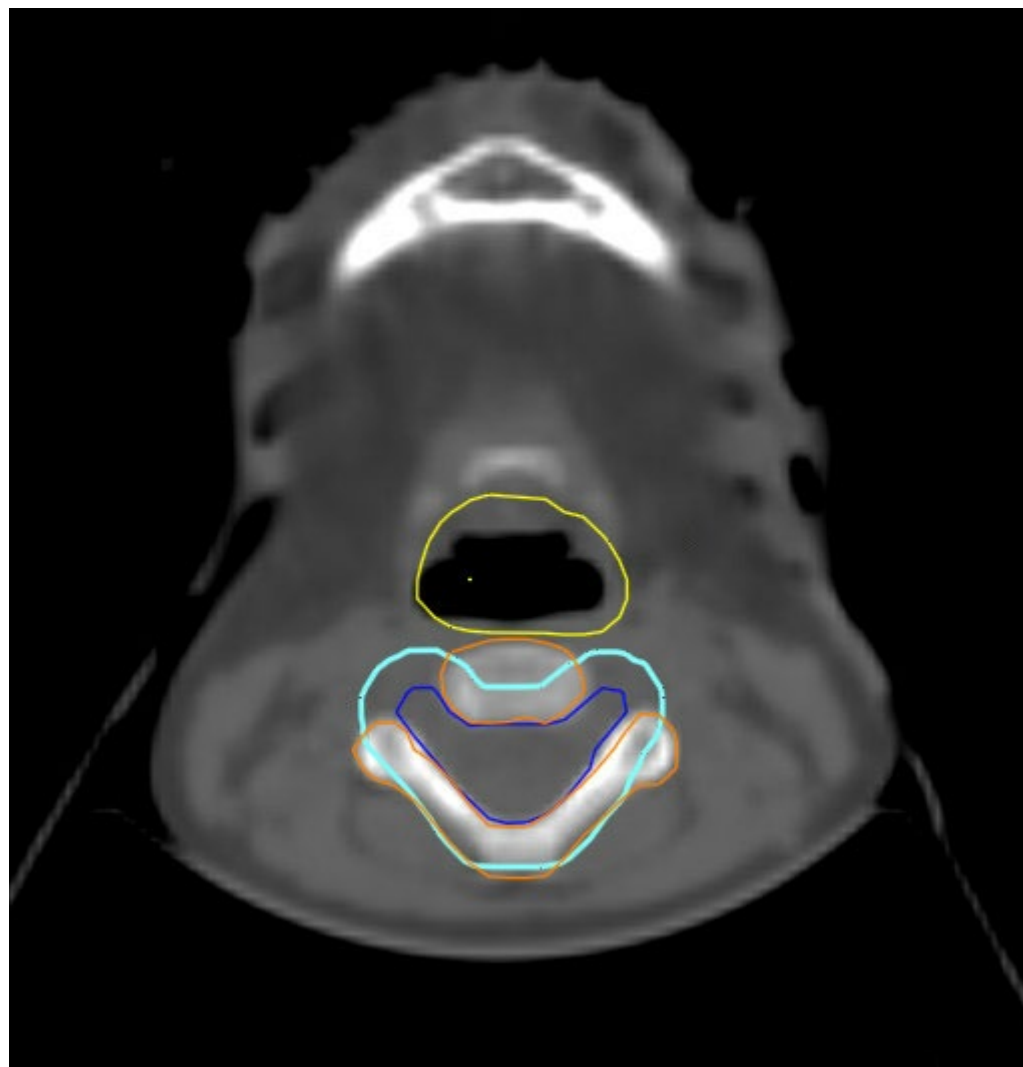
Vertebral body (VB) contours- to be covered by 18 Gy for skeletally immature patients (<13 yo). PTV_CSI-2340 in cyan, VB_1800 in red

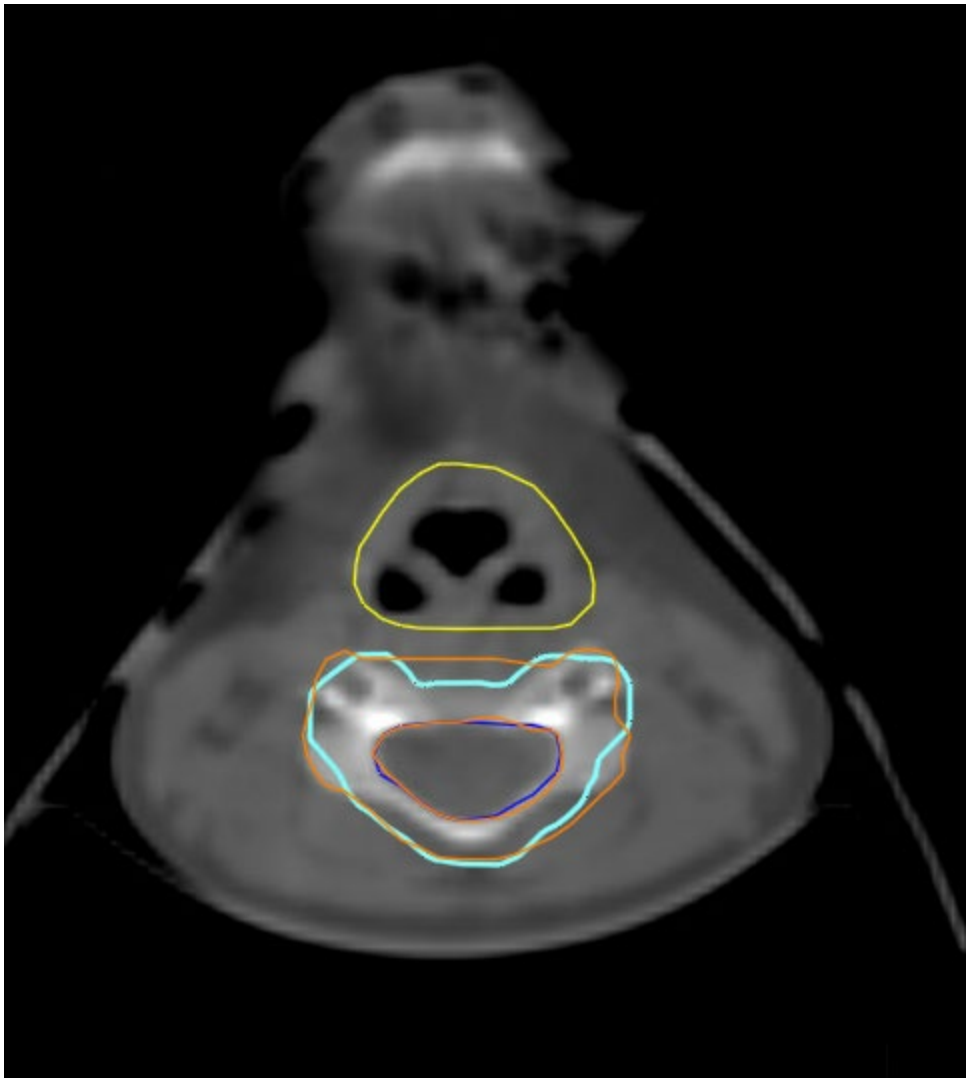




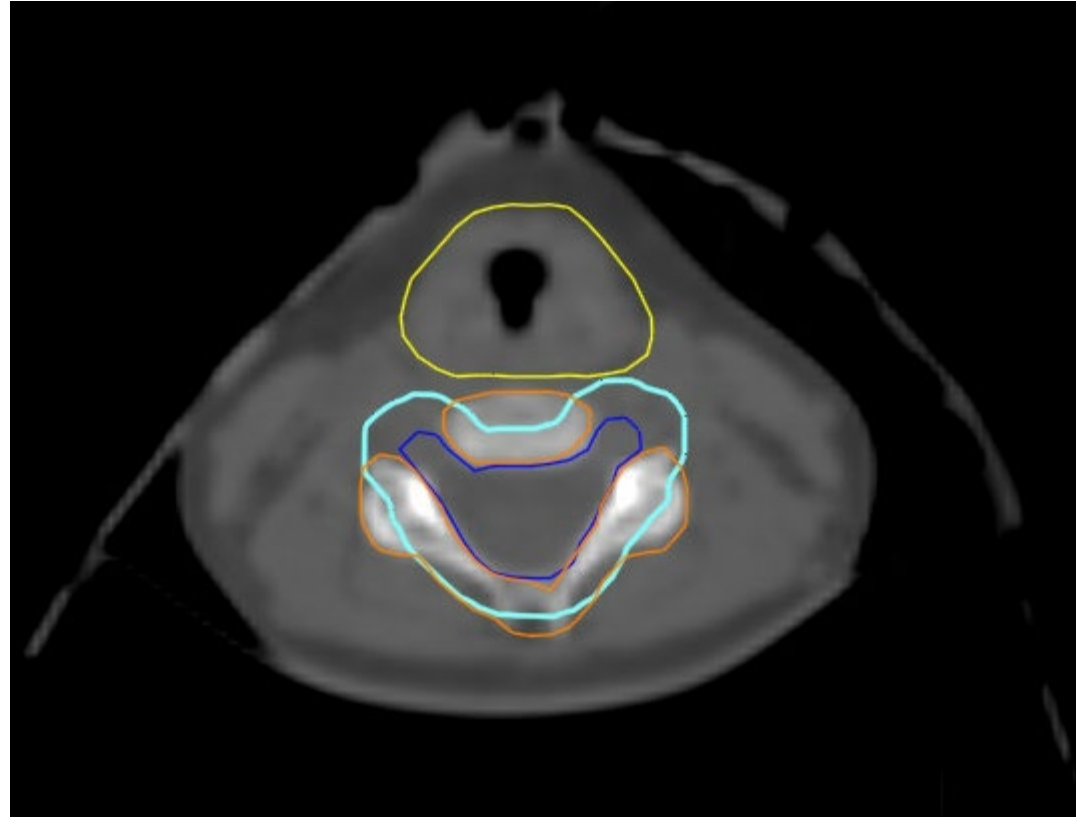


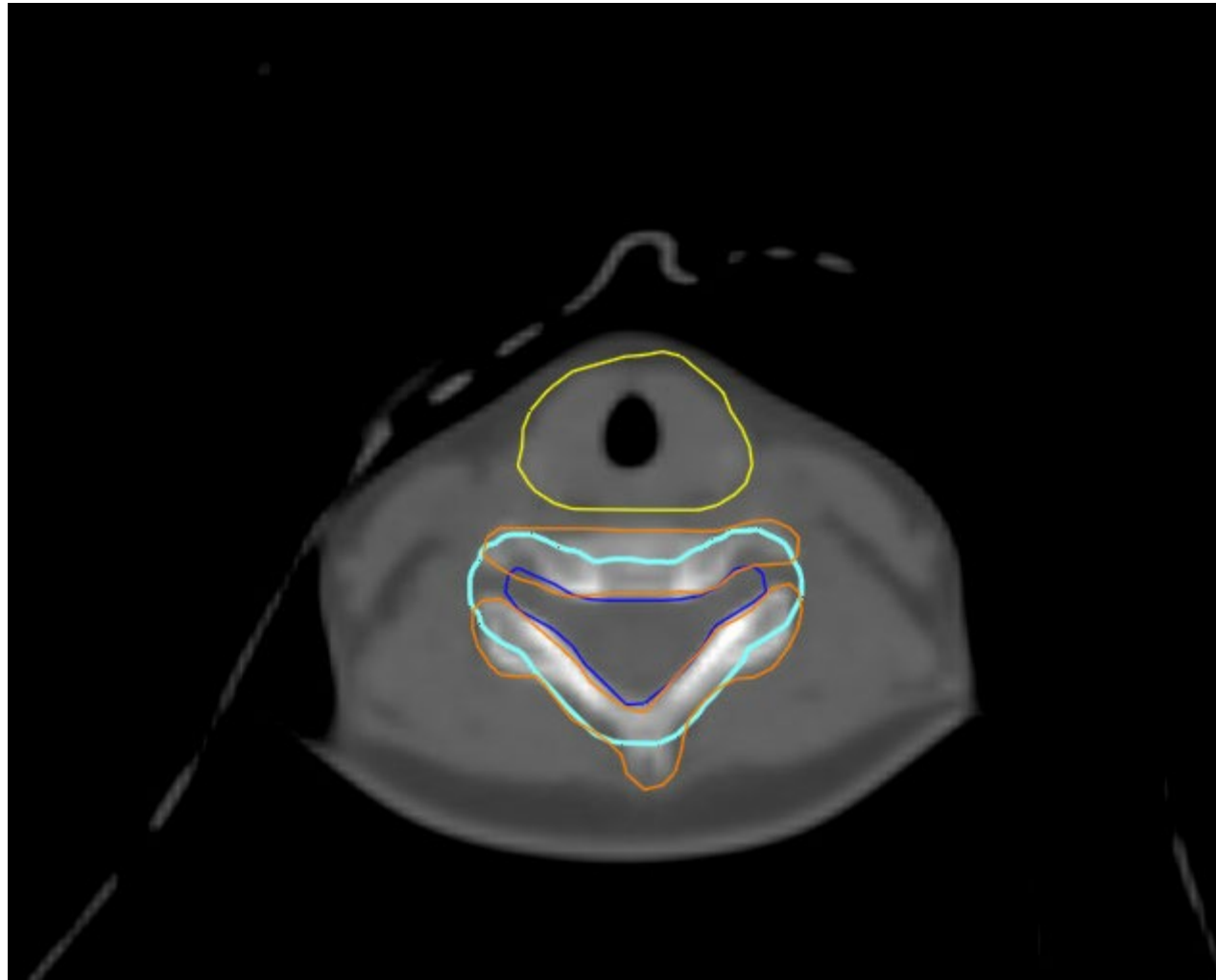


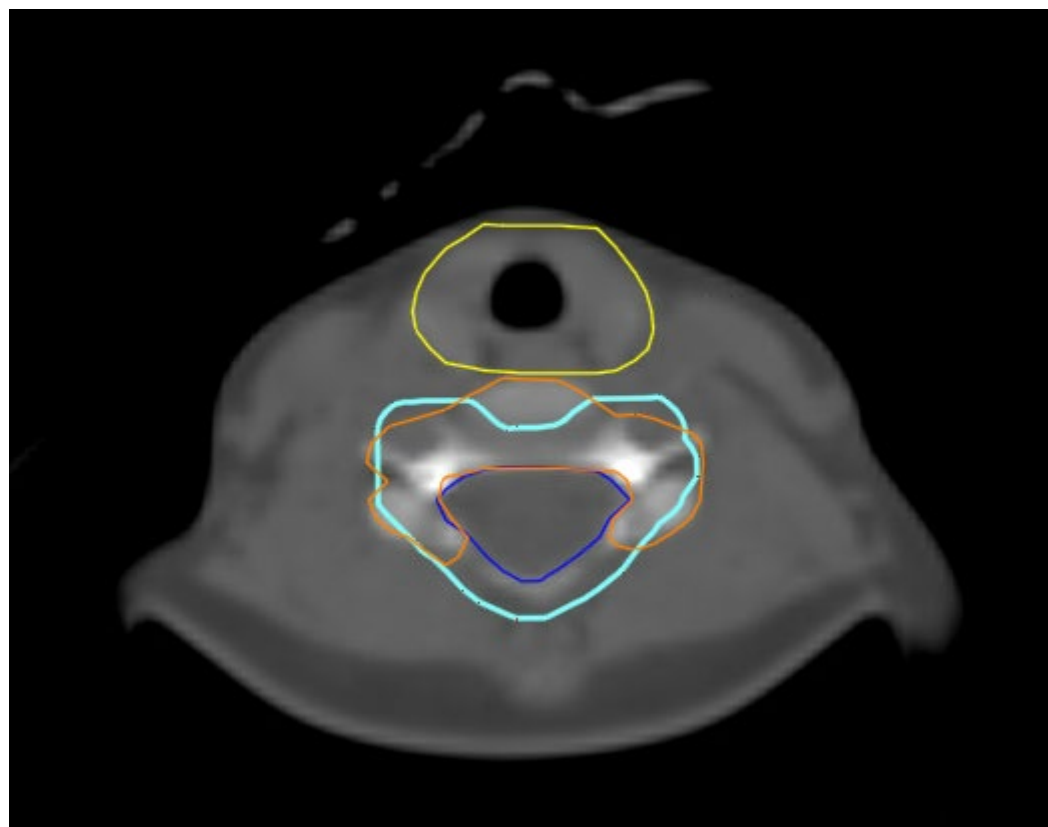


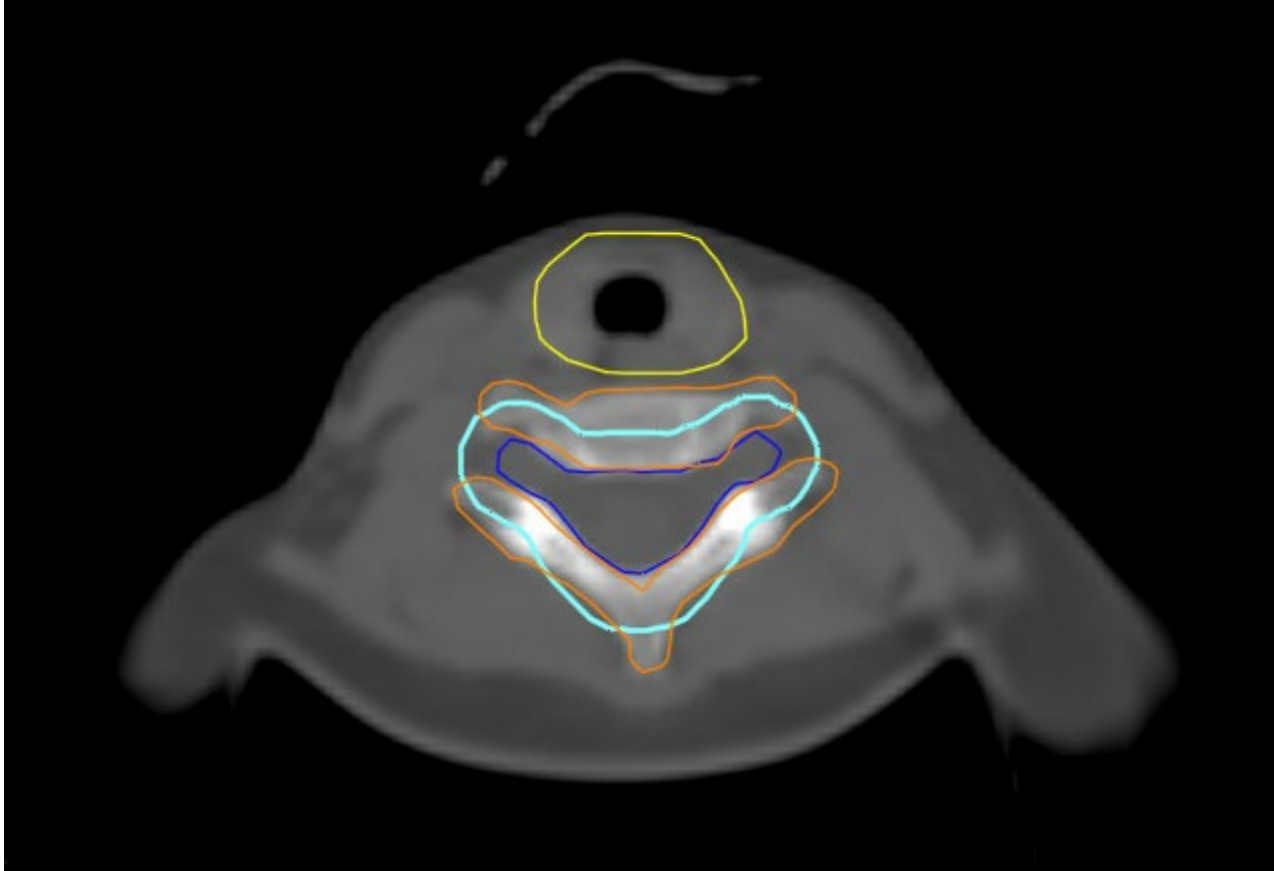


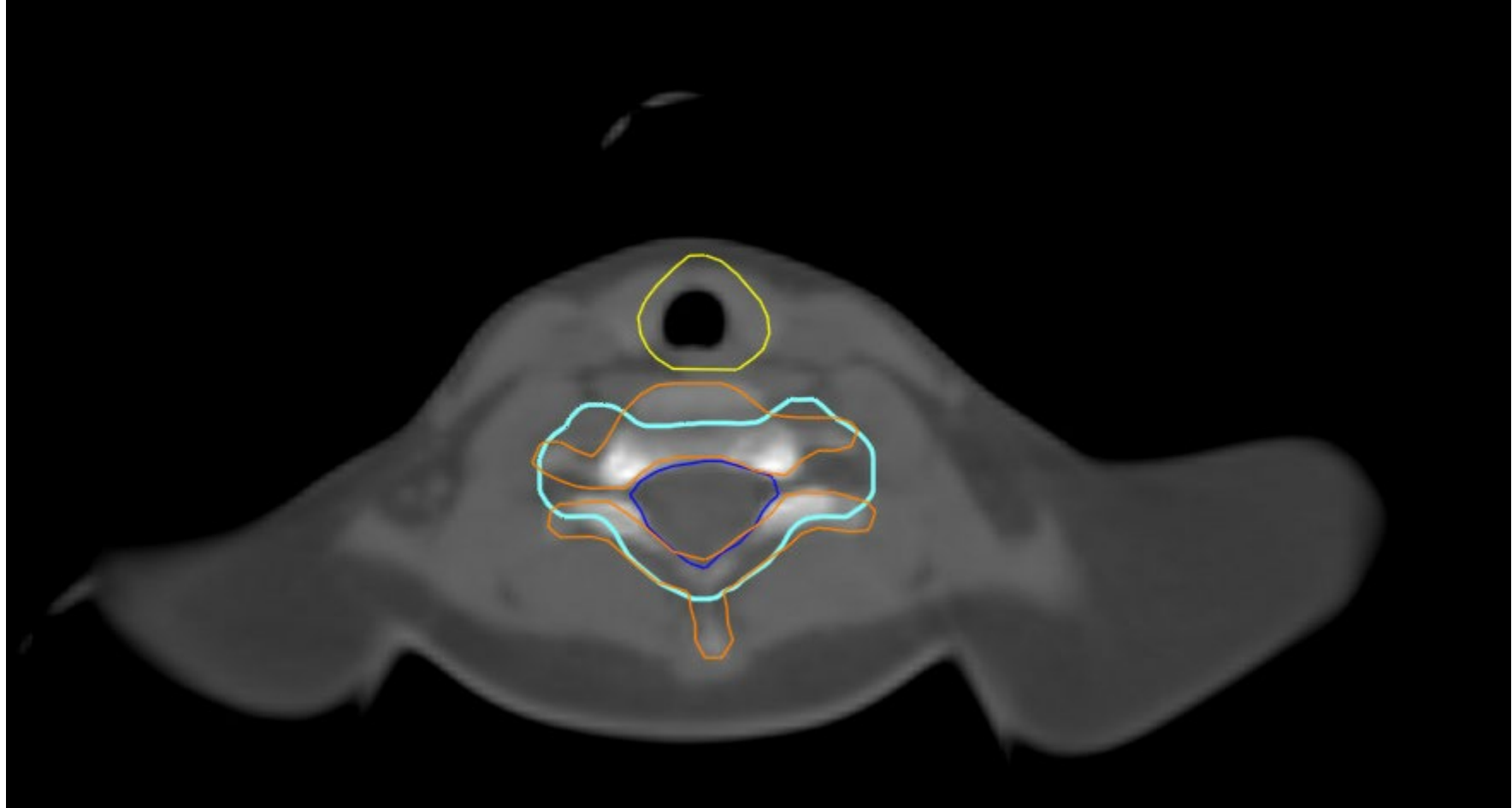
Larynx- yellow



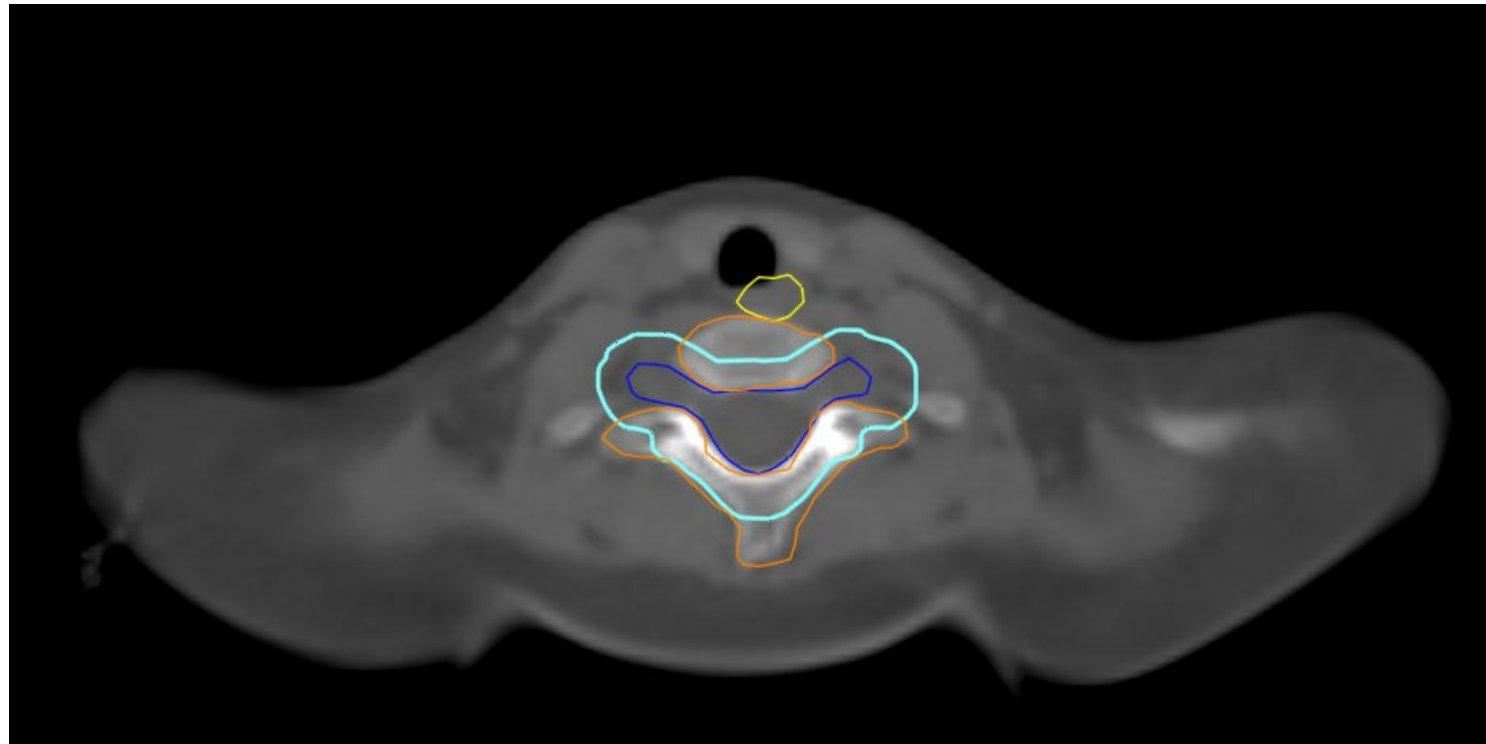






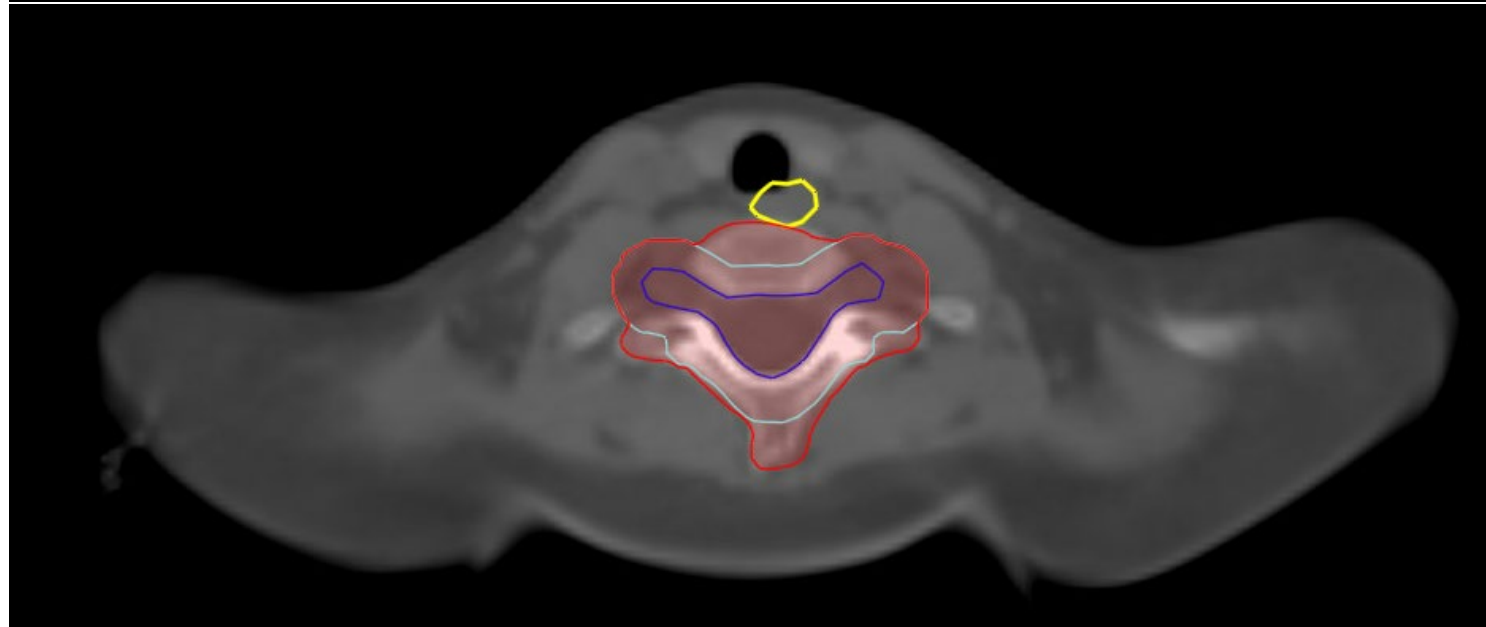


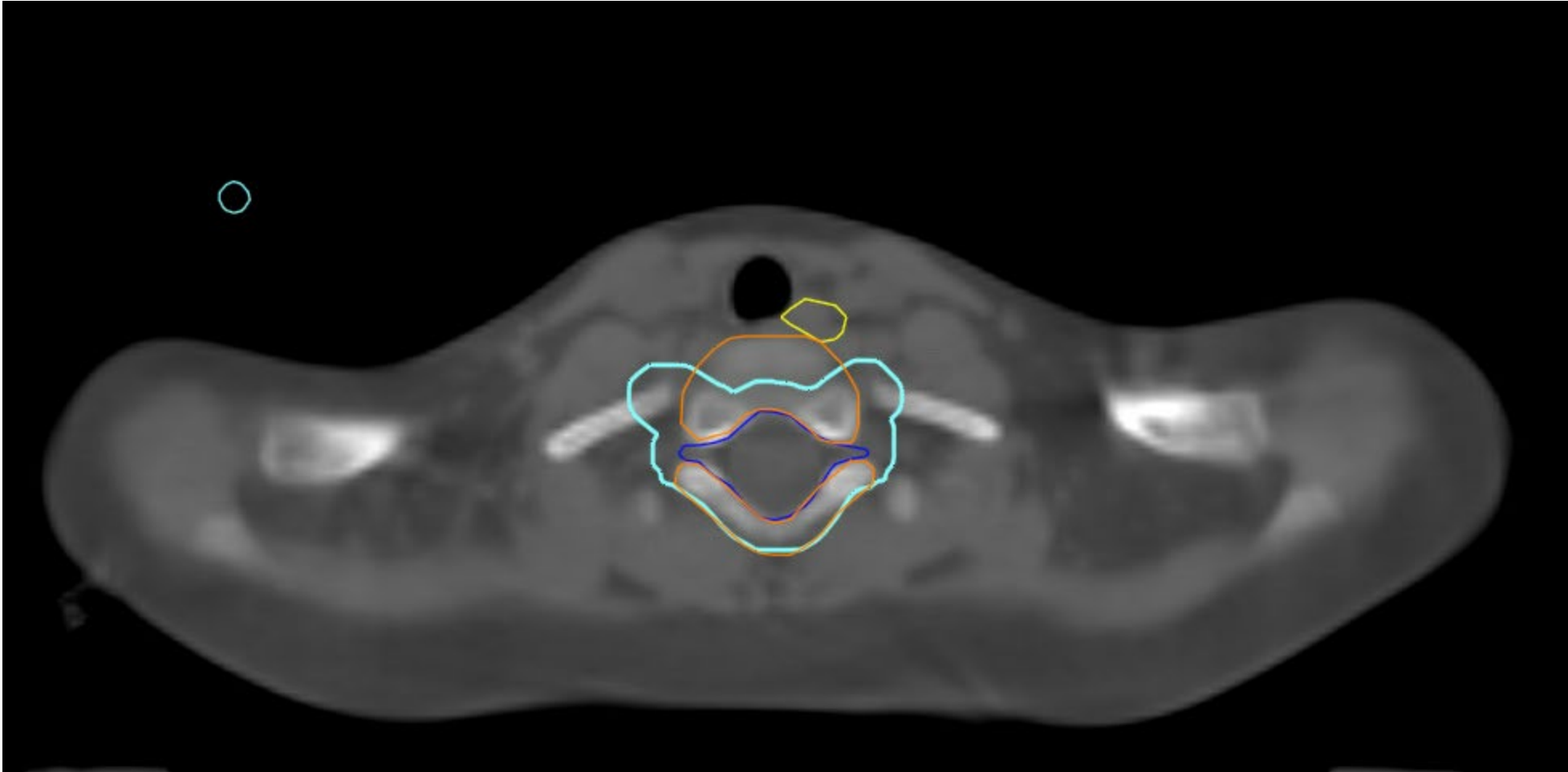
Vertebral Body Sparing



Non- Vertebral Body Sparing

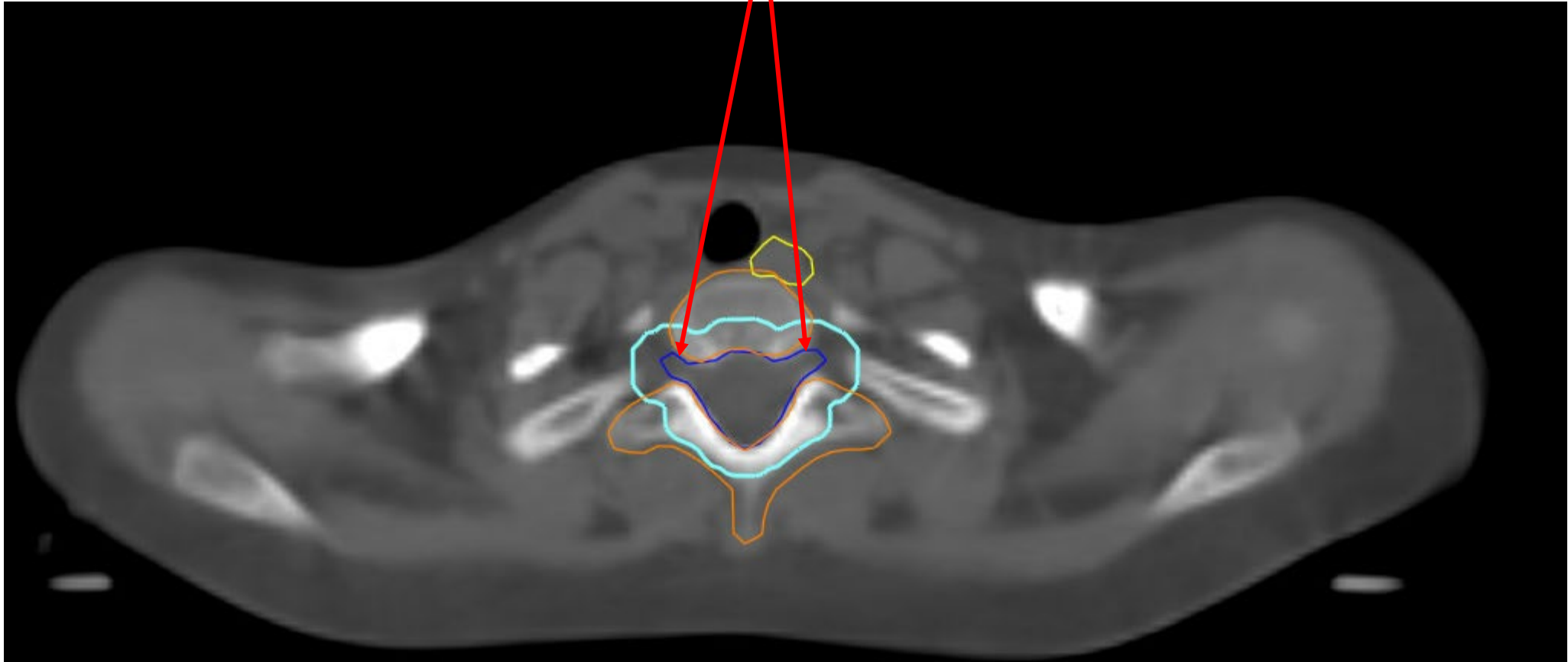
Vertebral body (VB) contours- to be covered by 18 Gy for skeletally immature patients (<13 yo). PTV_CSI-2340 in cyan, VB_1800 in red

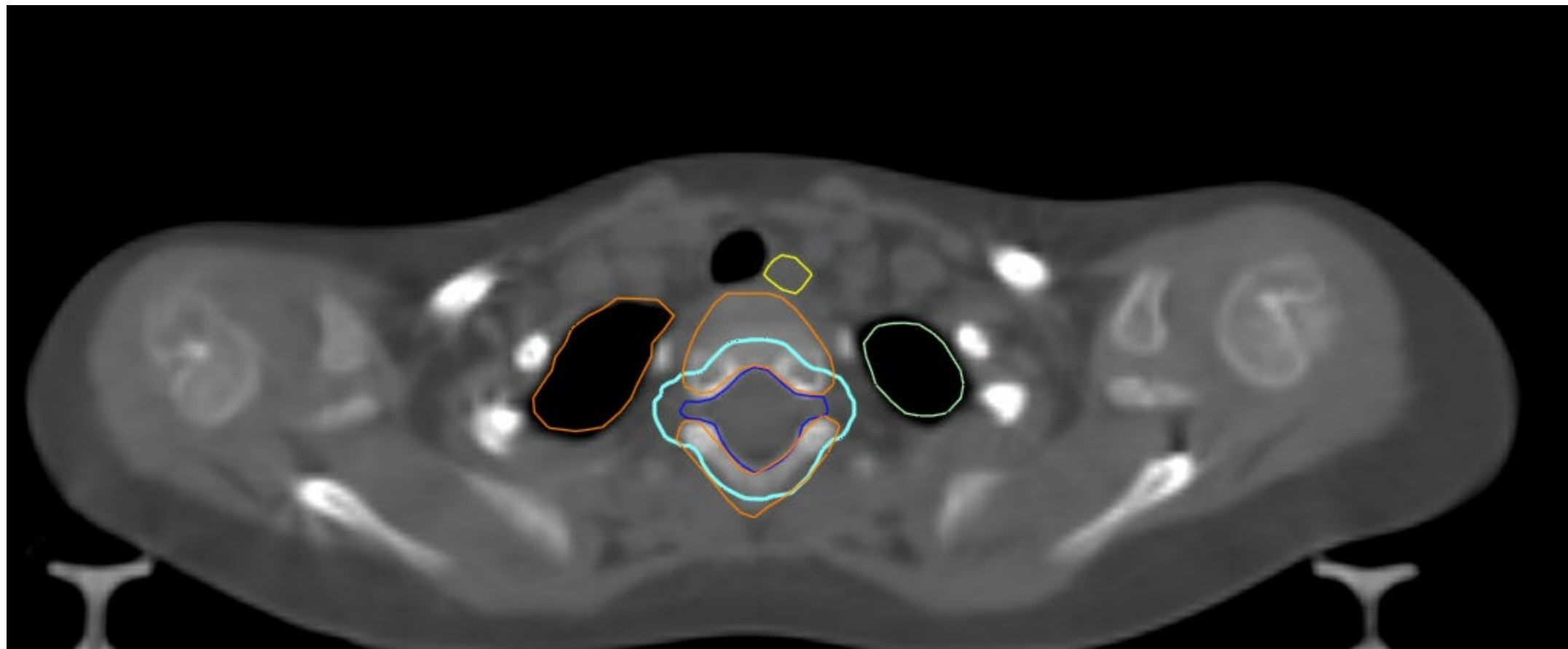


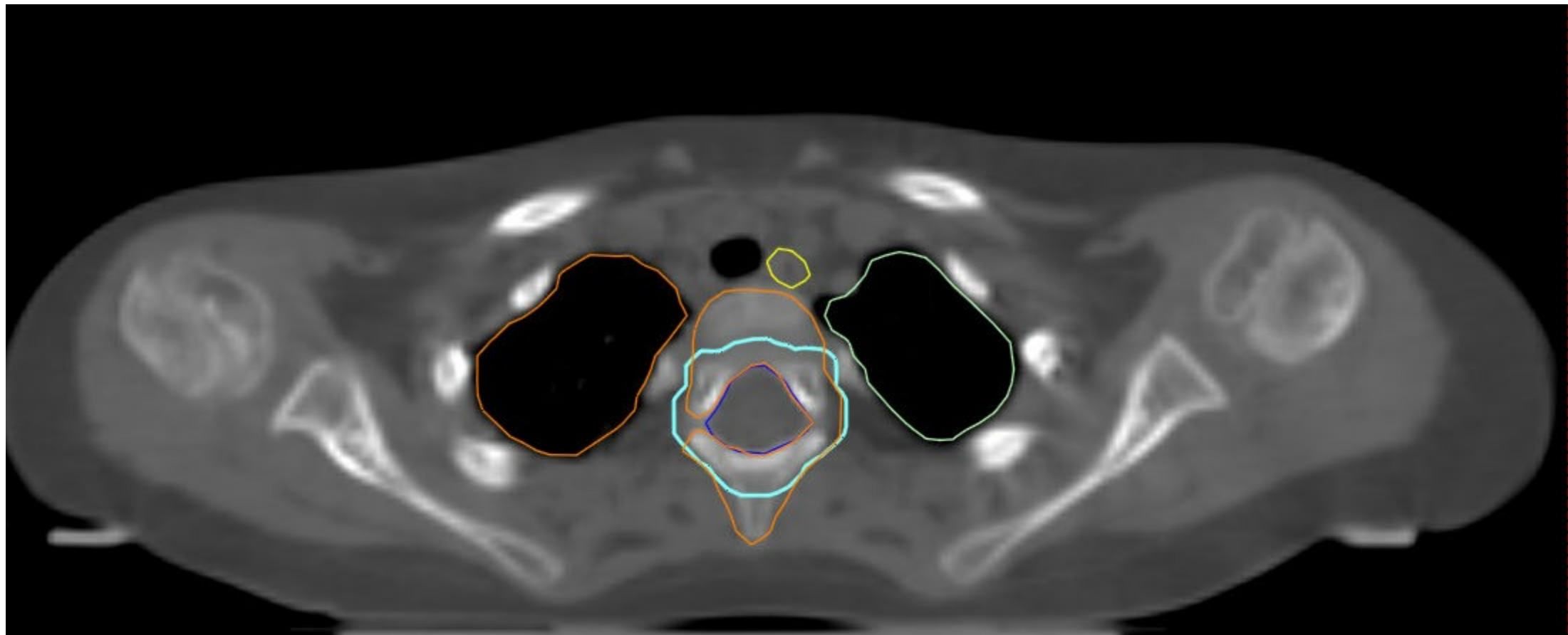


The CTV_spine is the subarachnoid space including the roots laterally

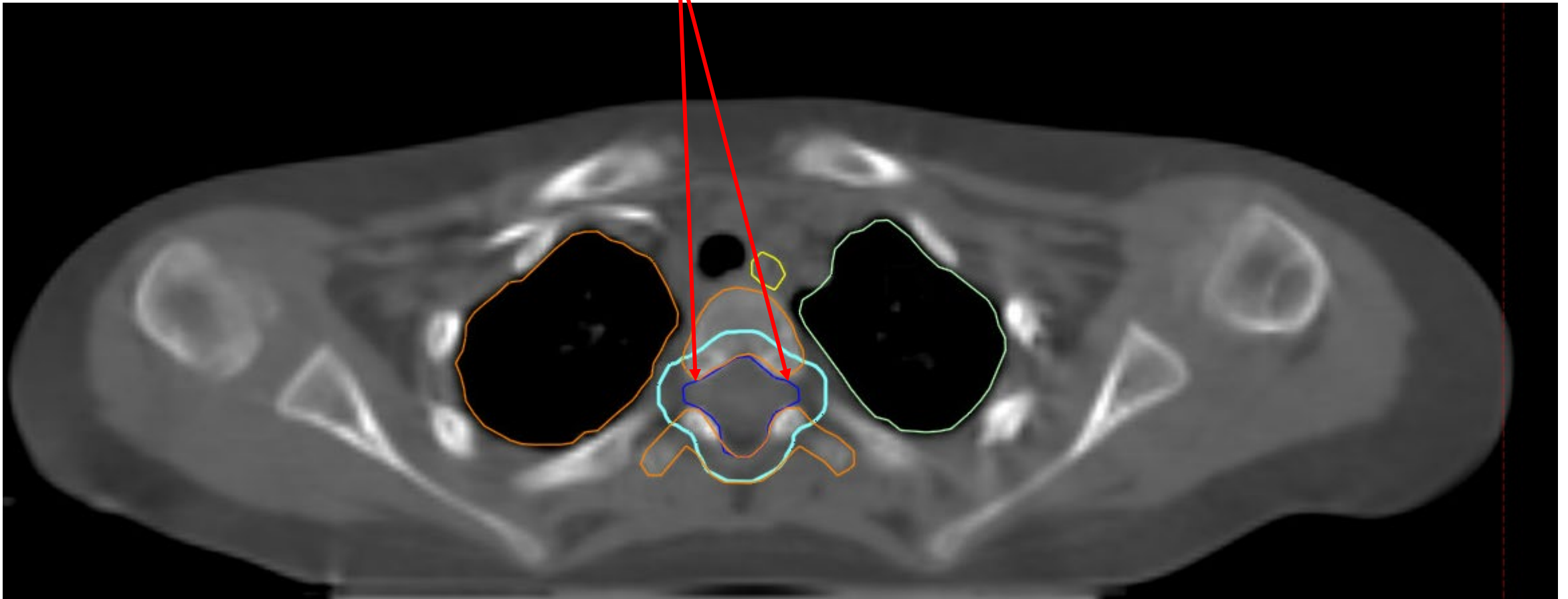
Esophagus- yellow

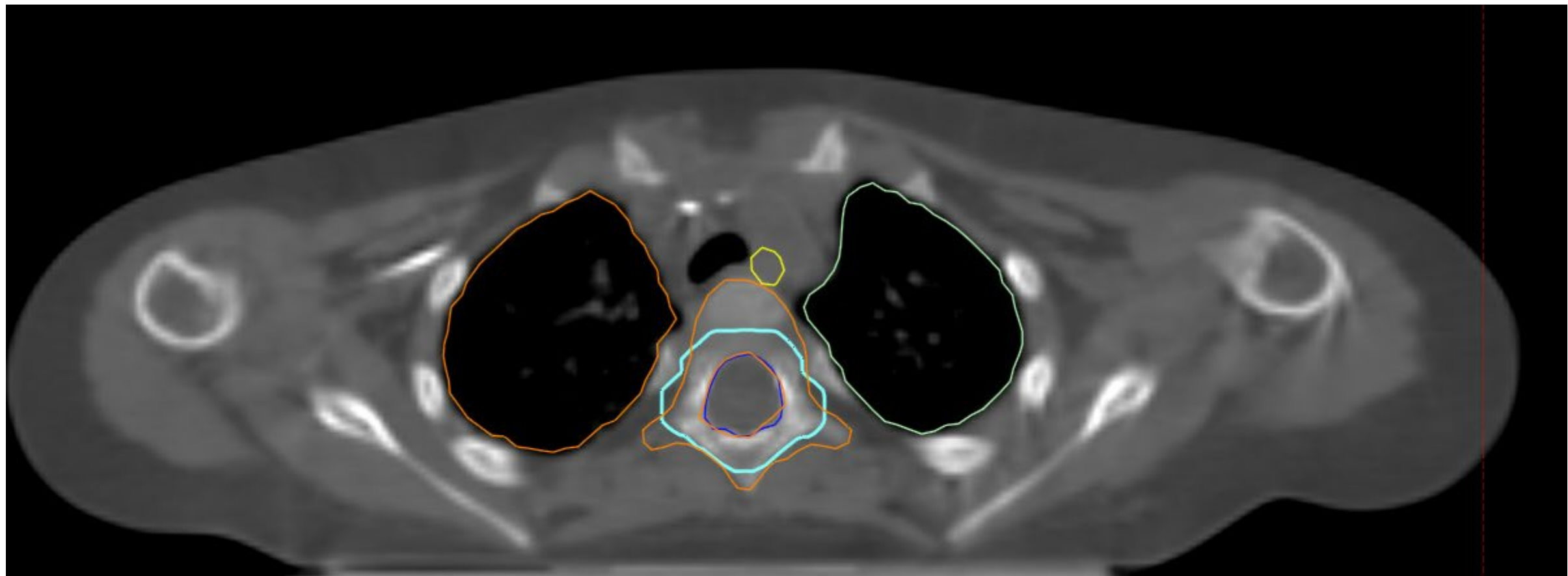


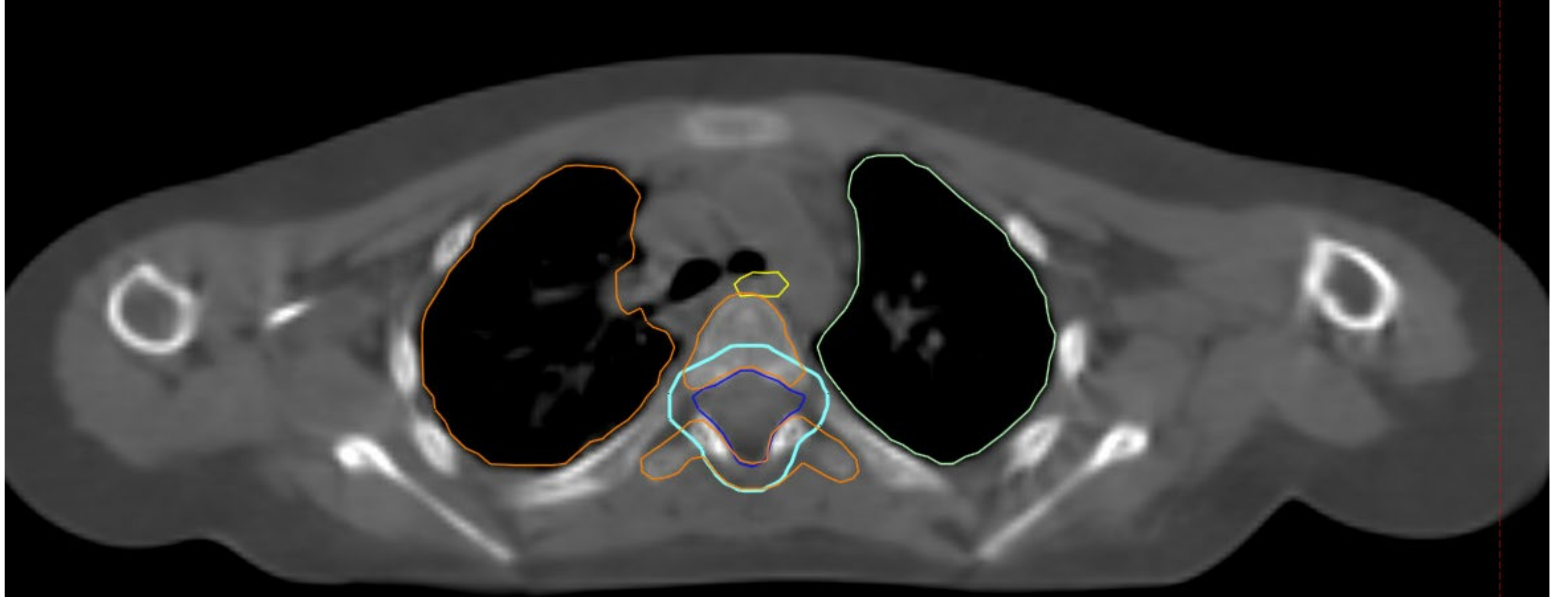


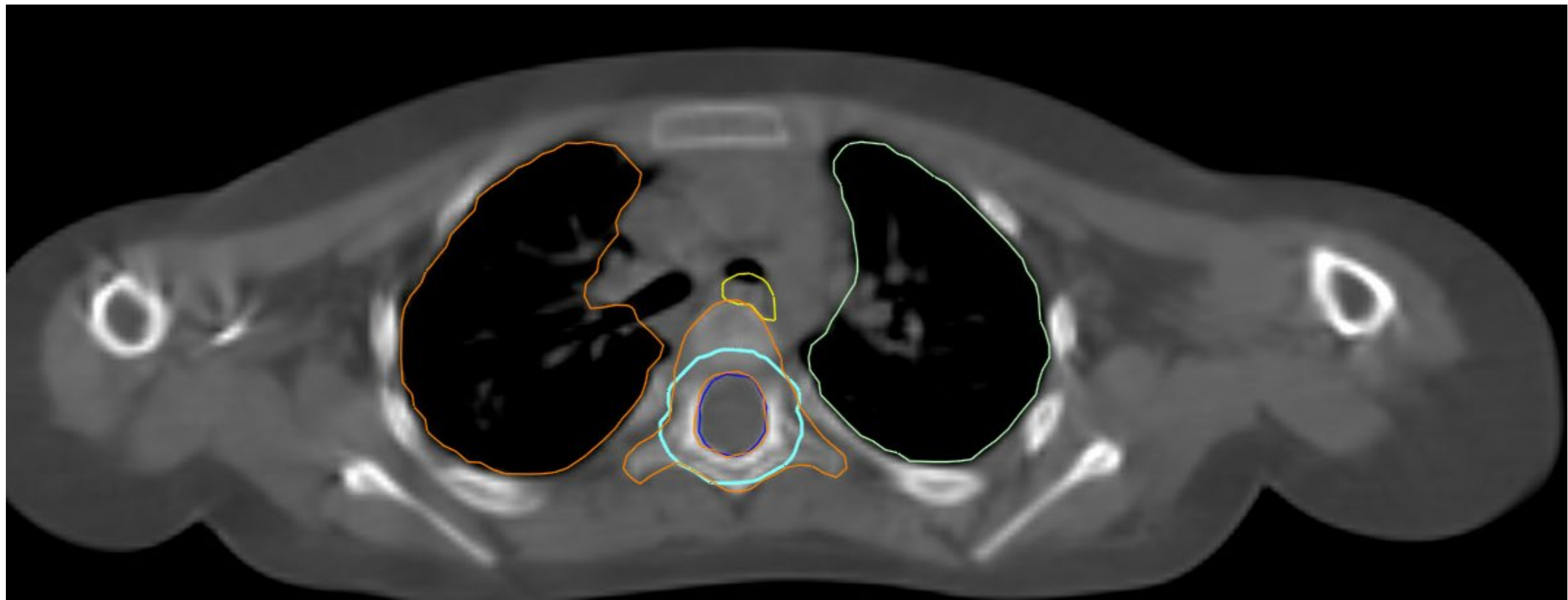


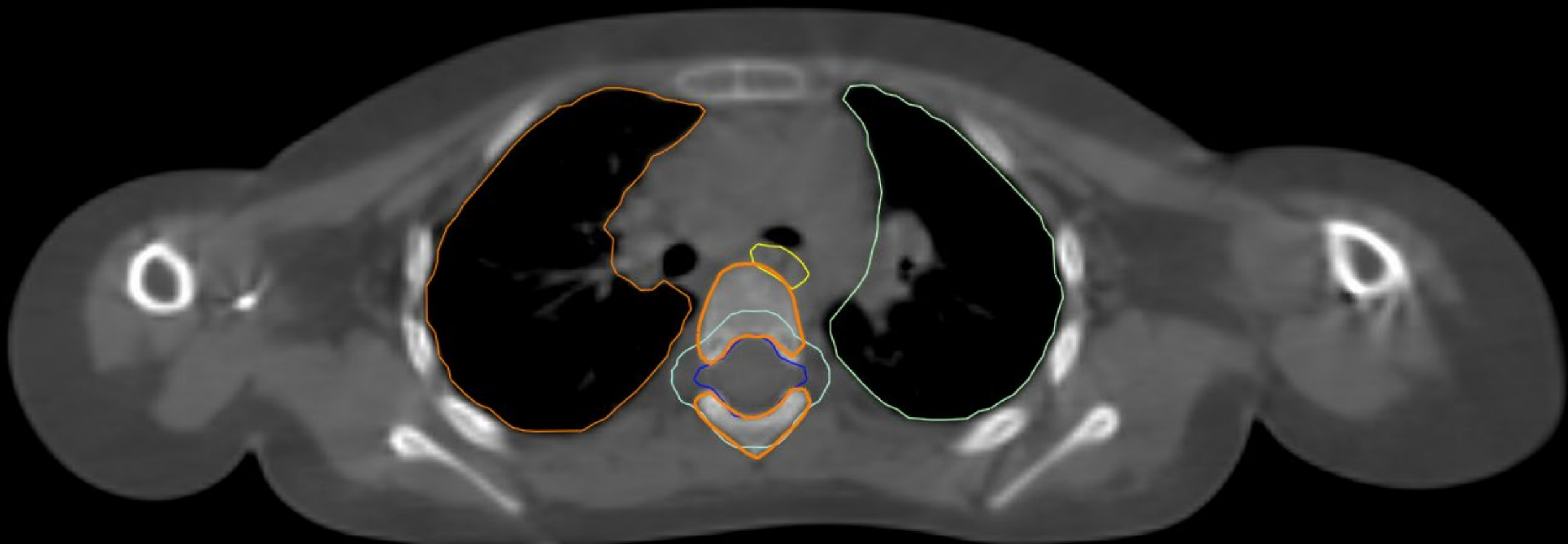
The CTV_spine is the subarachnoid space including the roots laterally







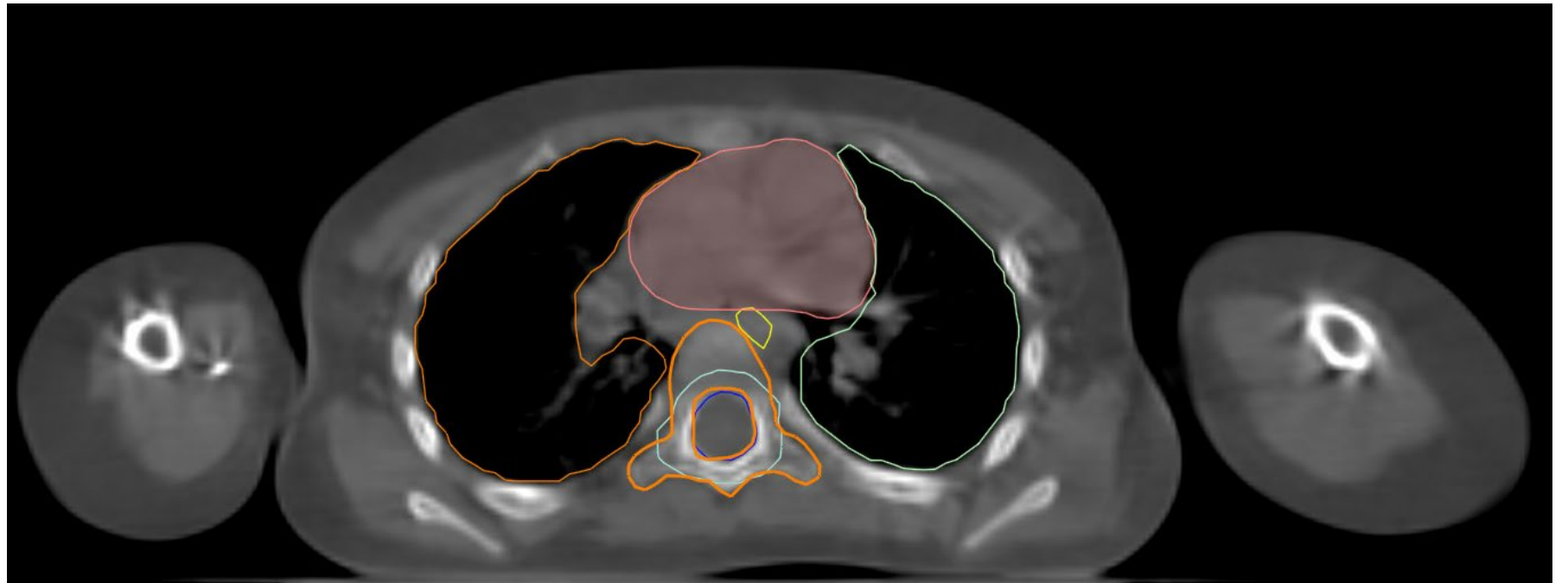




Vertebral Body Sparing

Heart- Pink

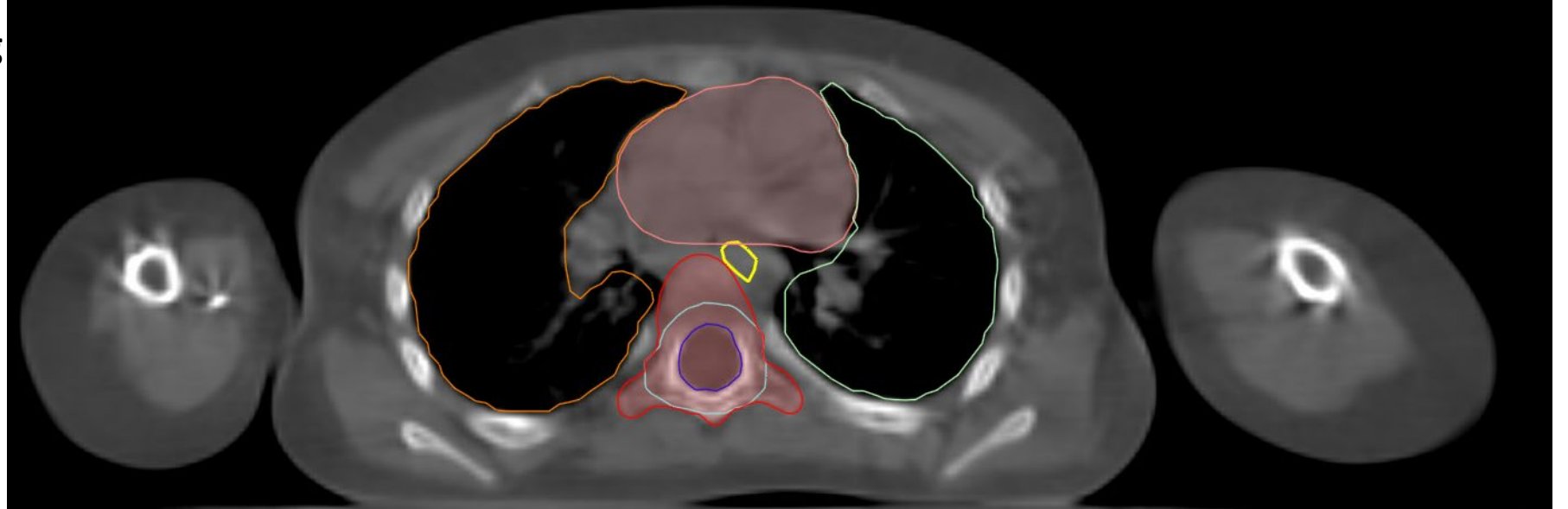
Right lung- Light Orange

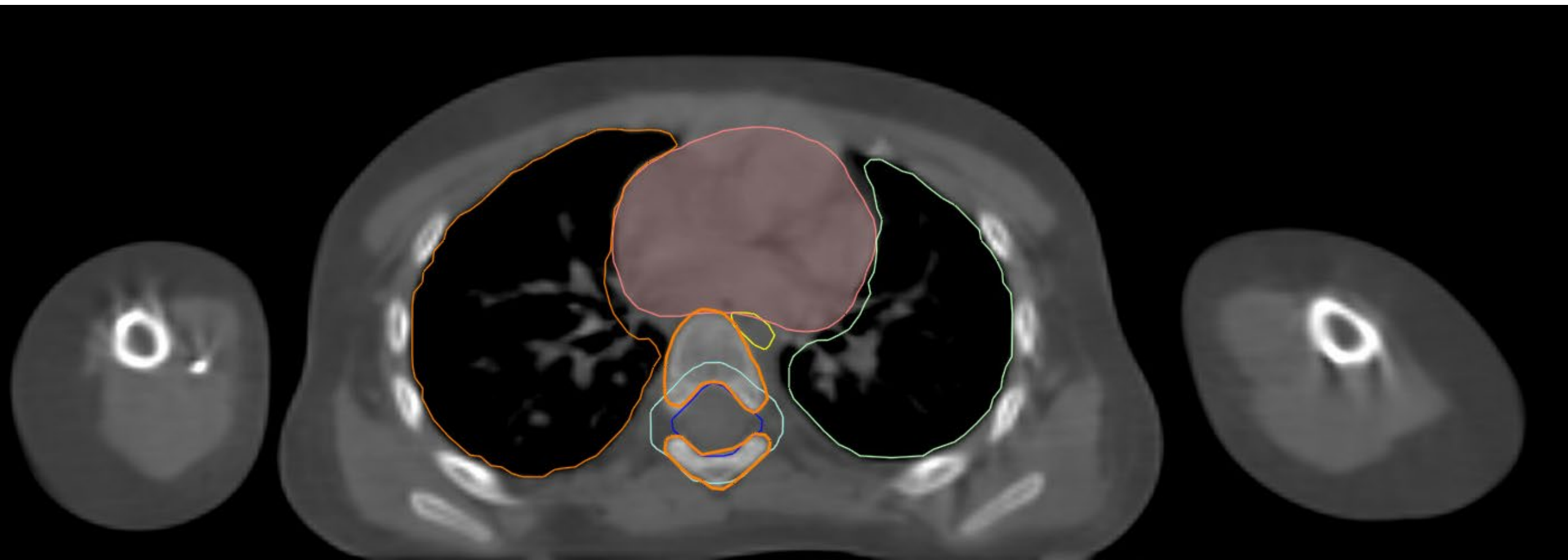


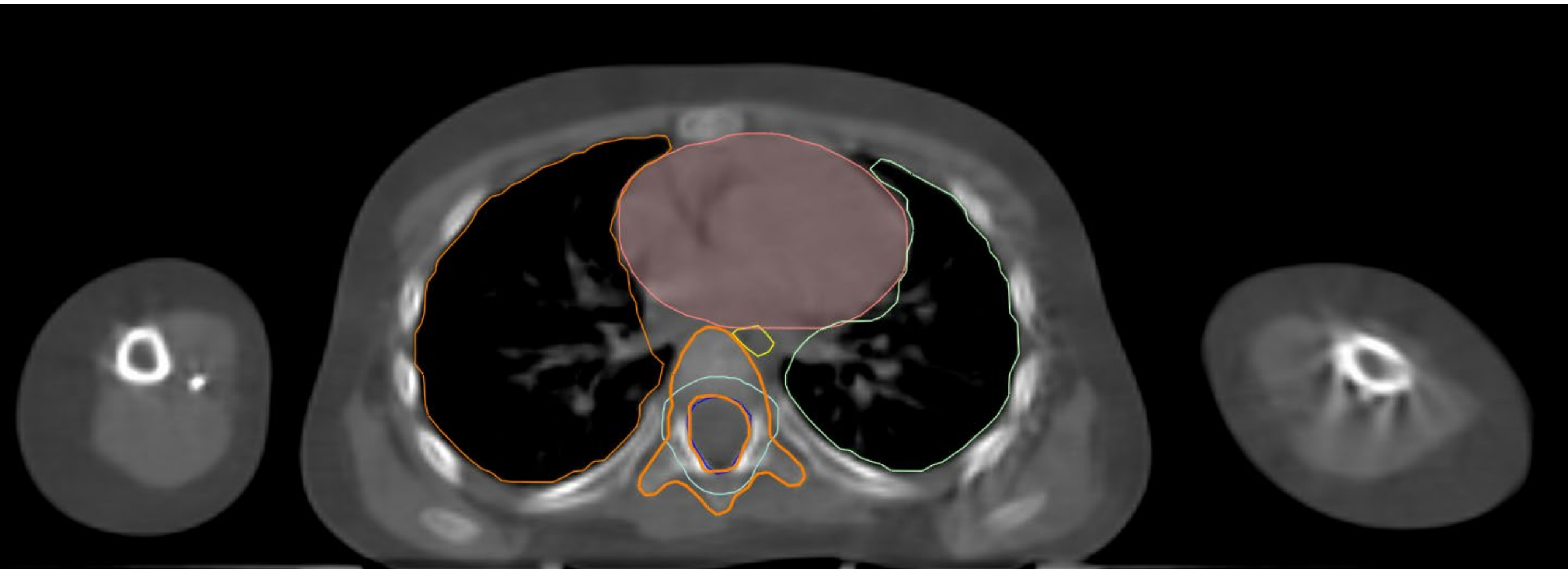
Left lung- Light green

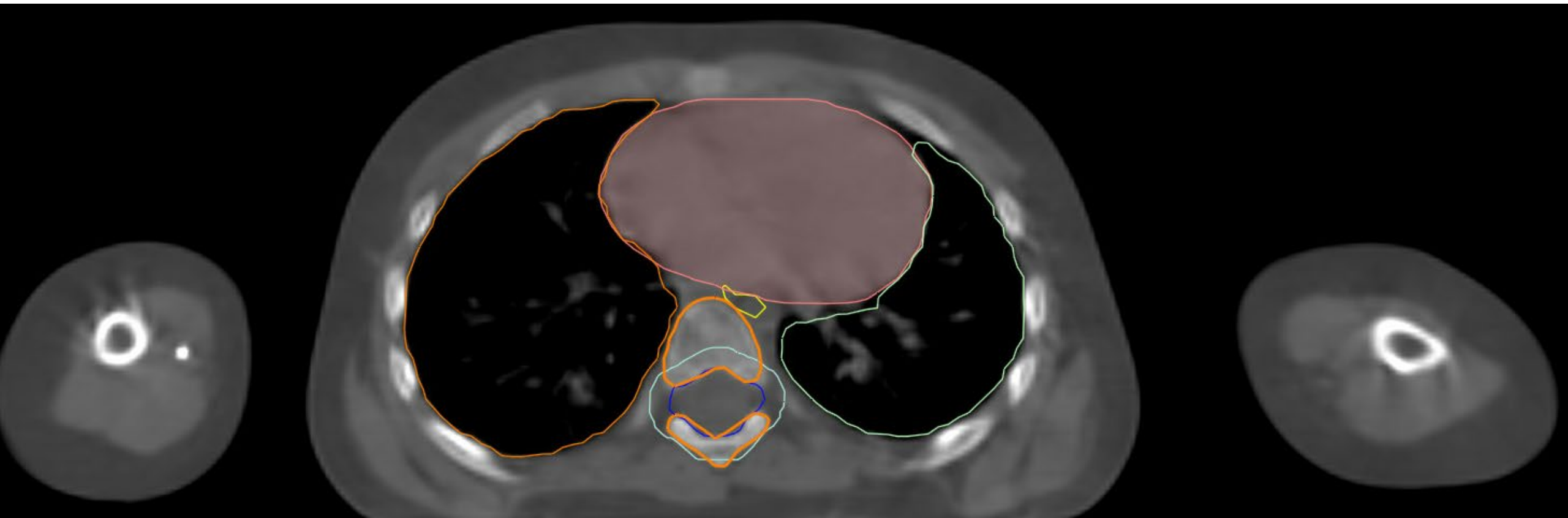Non- Vertebral Body Sparing

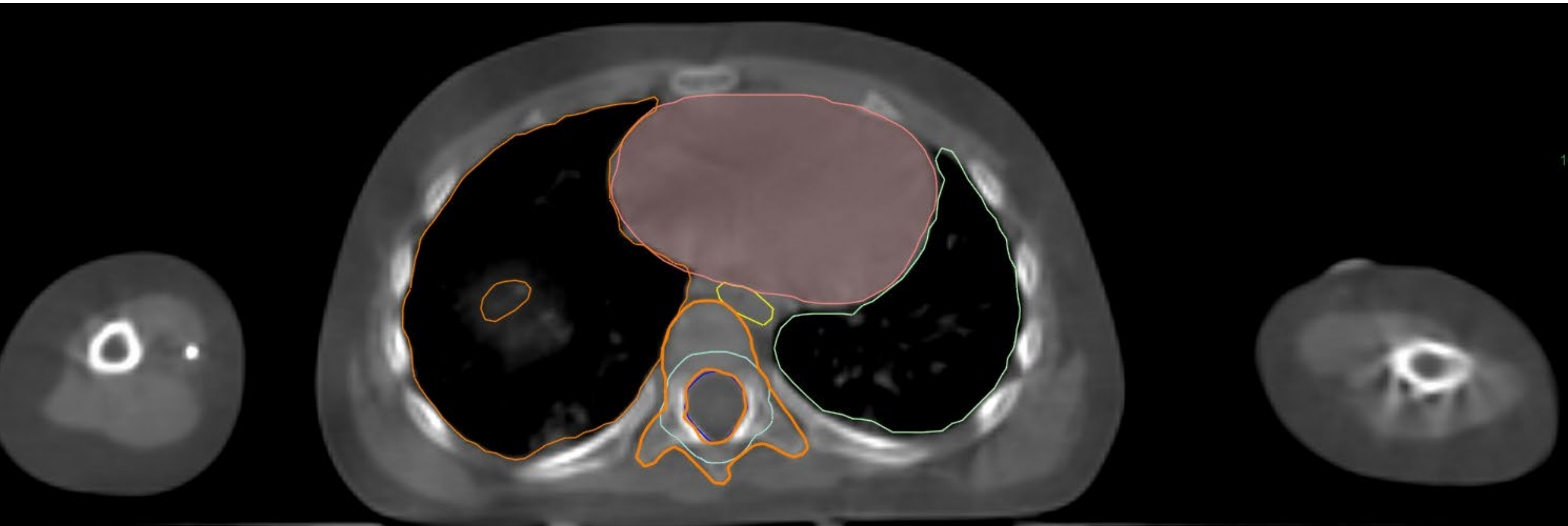Vertebral body (VB) contours- to be covered by 18 Gy for skeletally immature patients (<13 yo). PTV_CSI-2340 in cyan, VB_1800 in red





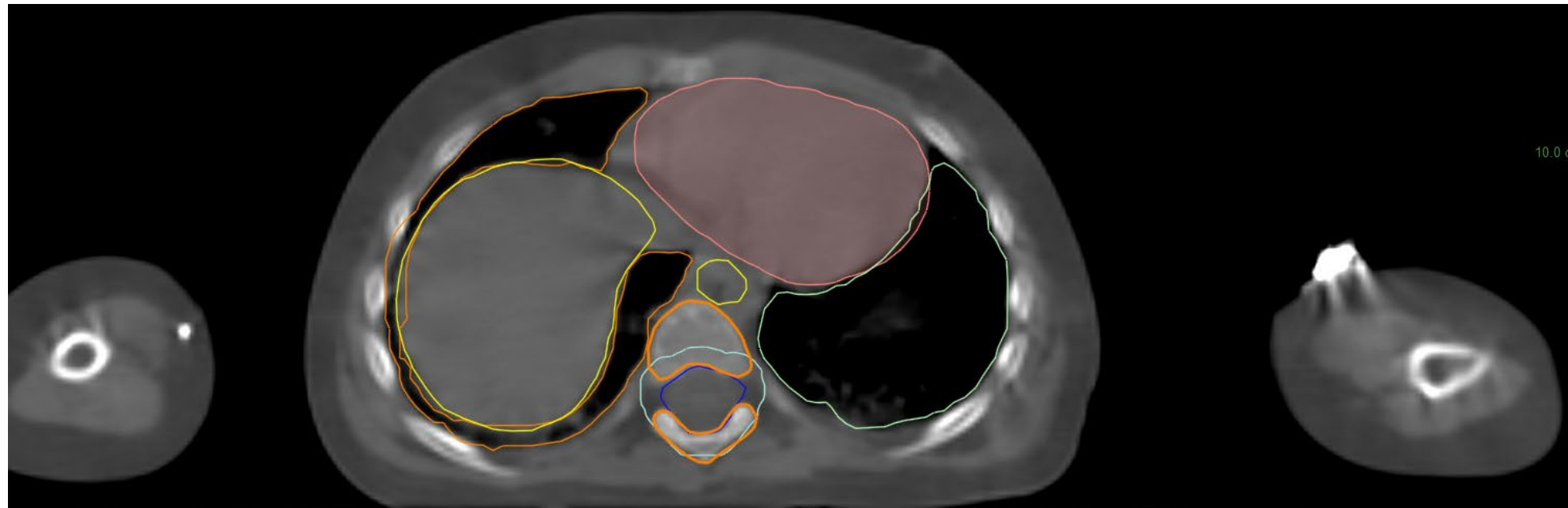






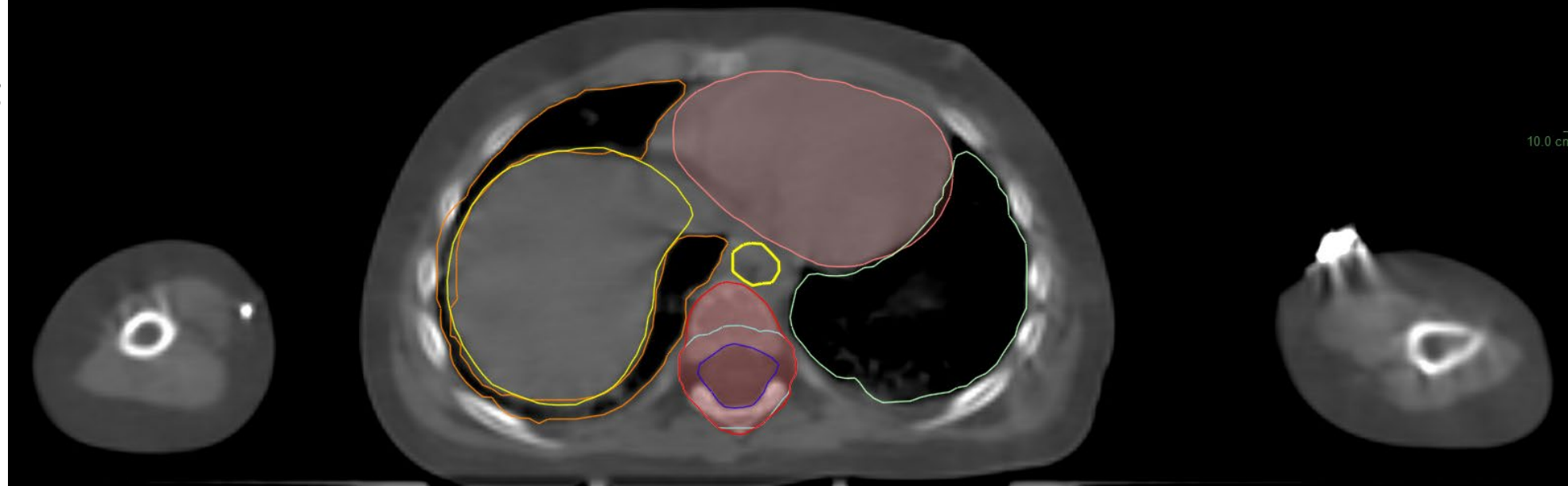Vertebral Body Sparing

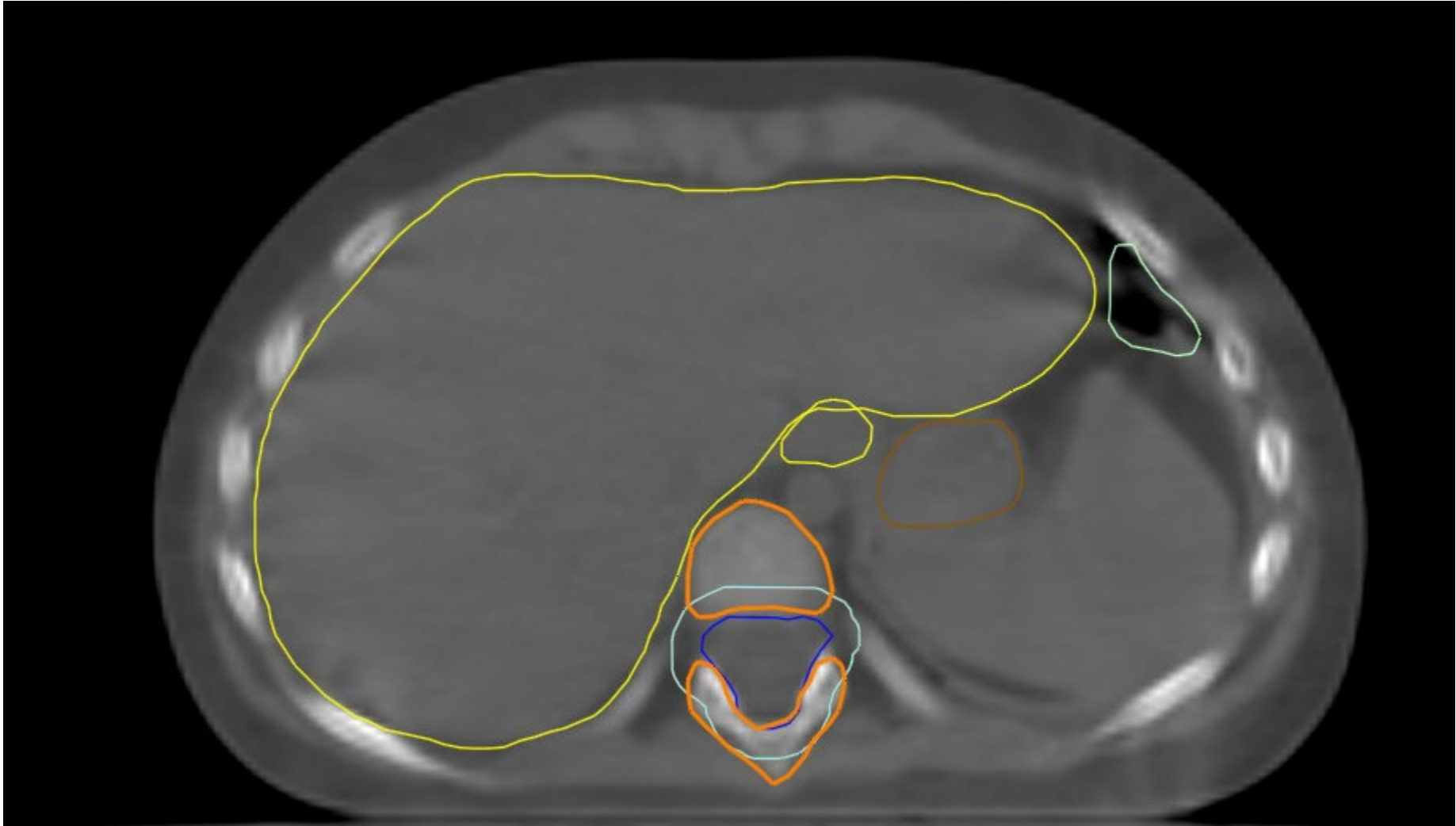
Liver- yellow



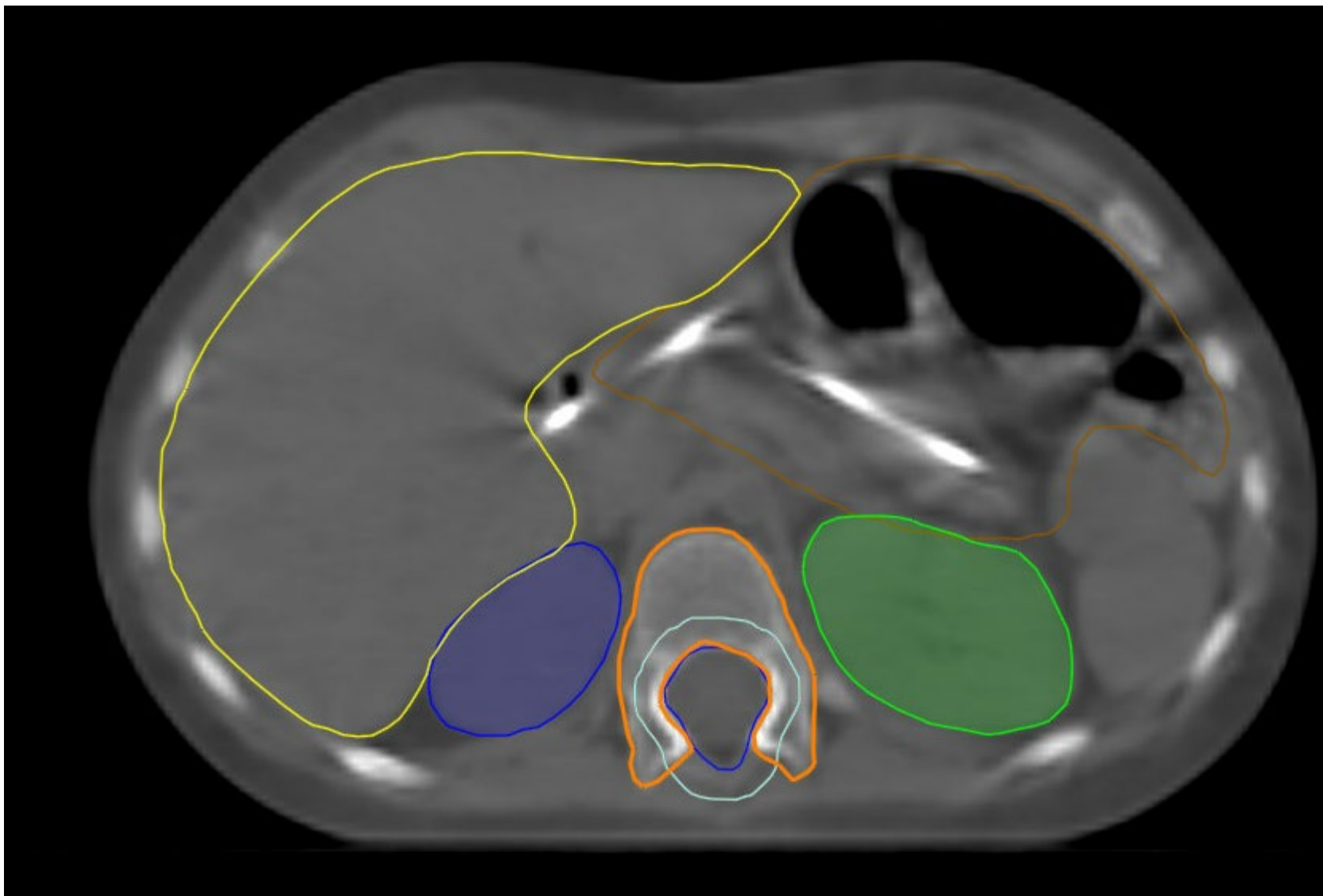
Non- Vertebral Body Sparing

Vertebral body (VB) contours- to be covered by 18 Gy for skeletally immature patients (<13 yo). PTV_CSI-2340 in cyan, VB_1800 in red



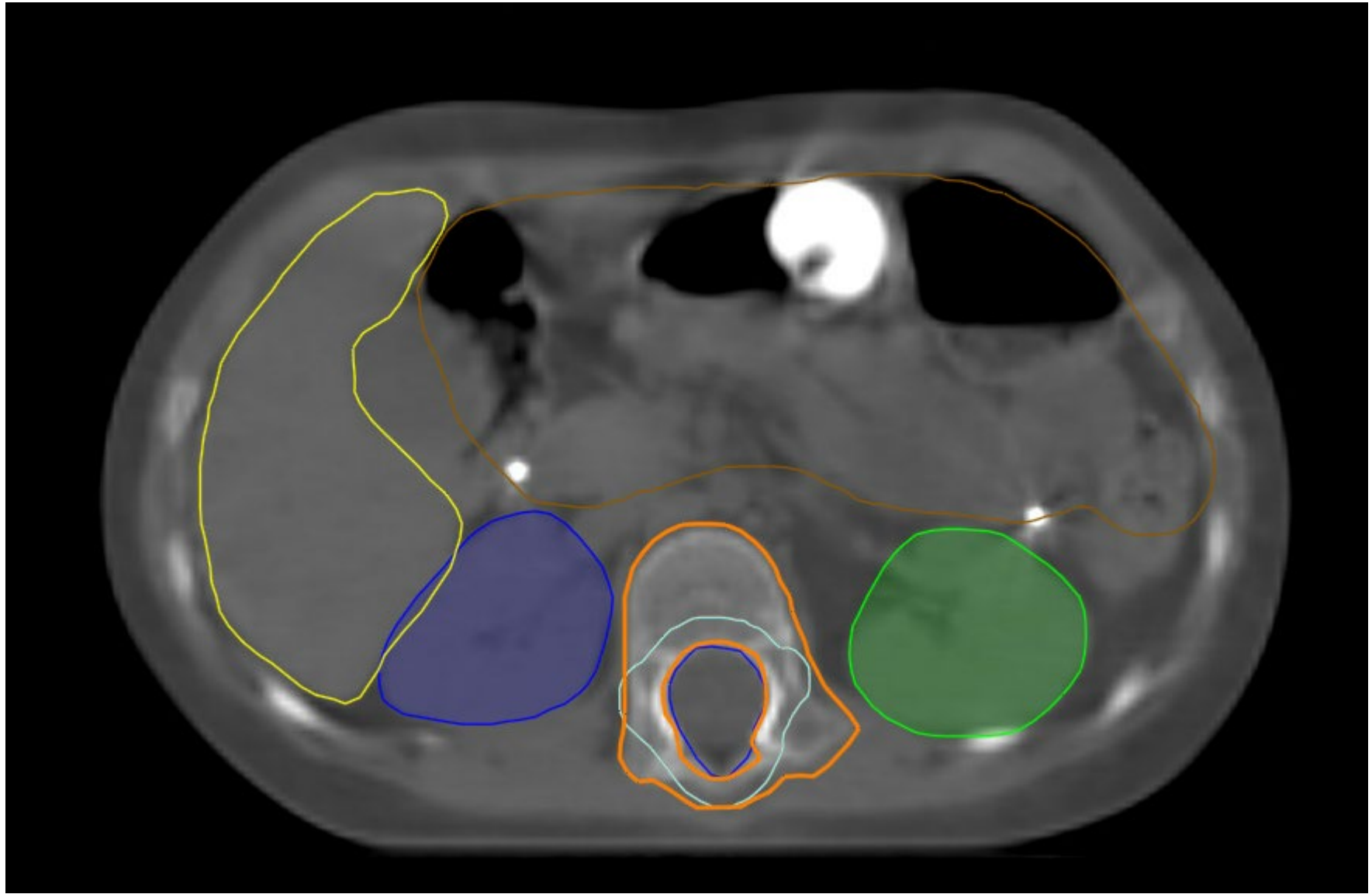


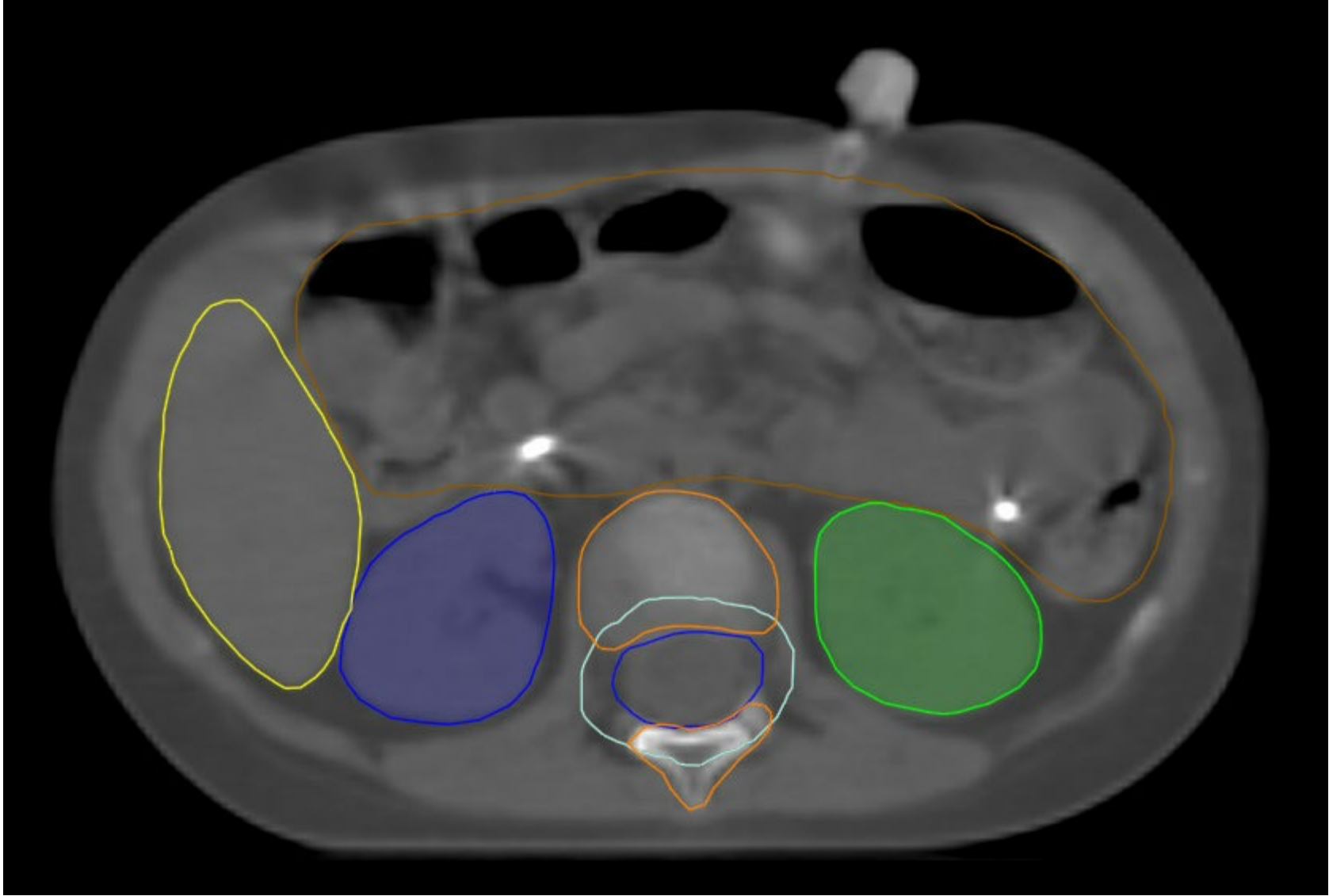
Right kidney- Blue



Bowel Bag-
Brown

Left kidney- Green

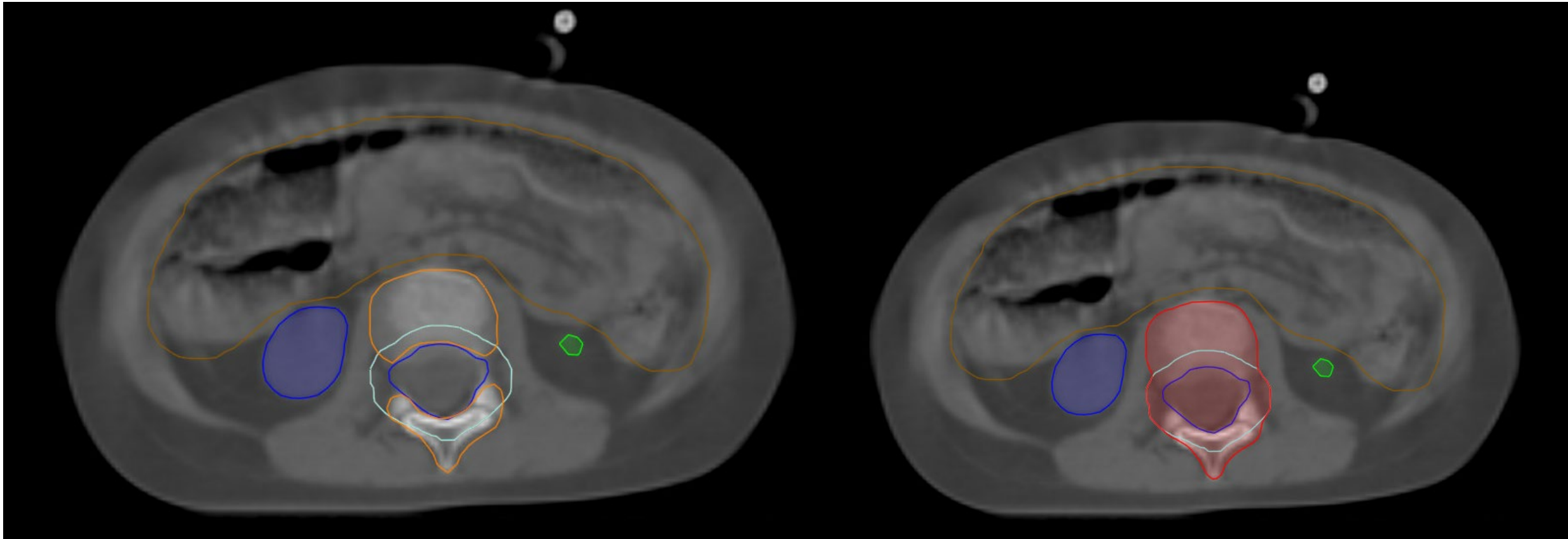


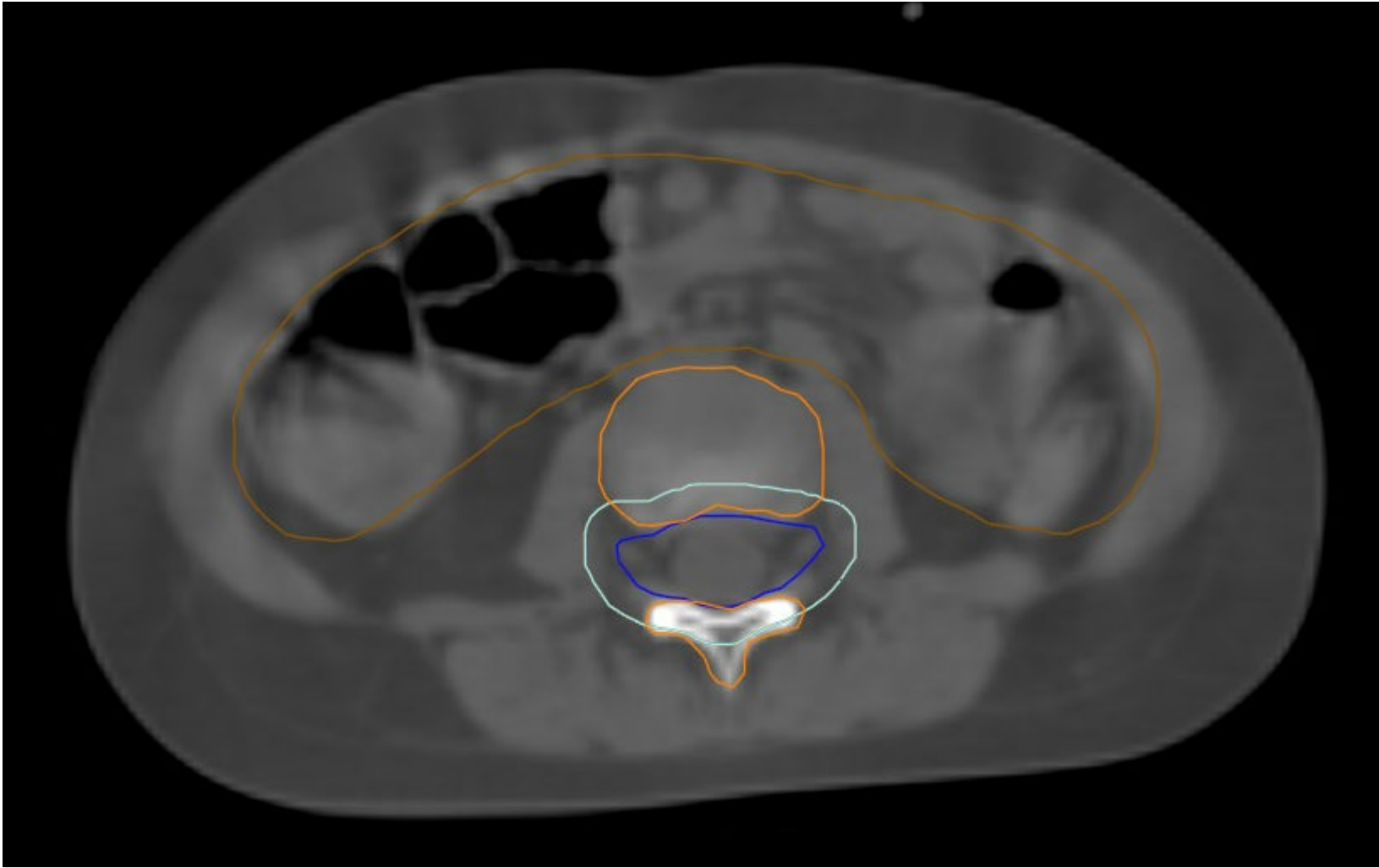


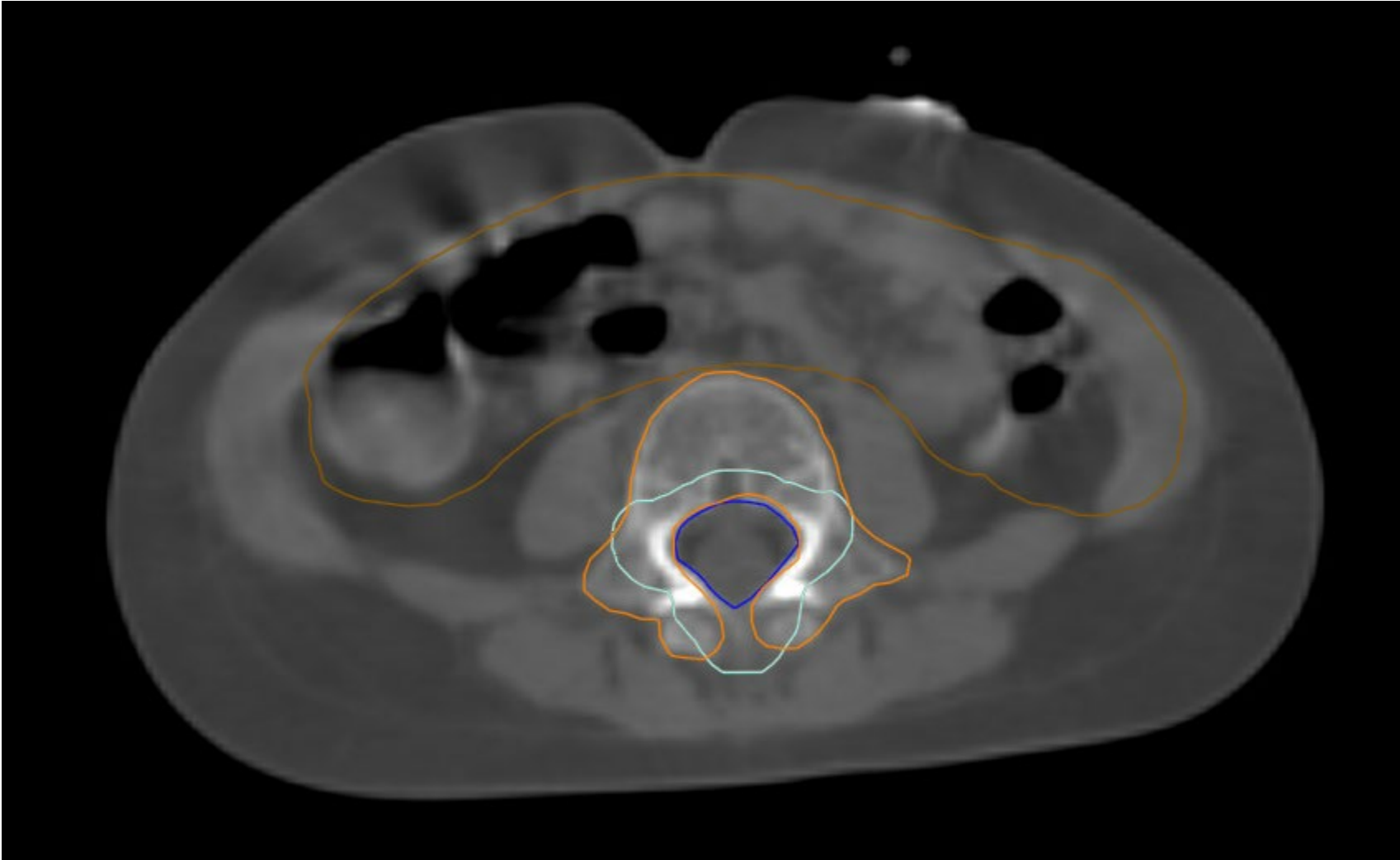
Vertebral Body Sparing

Non- Vertebral Body Sparing

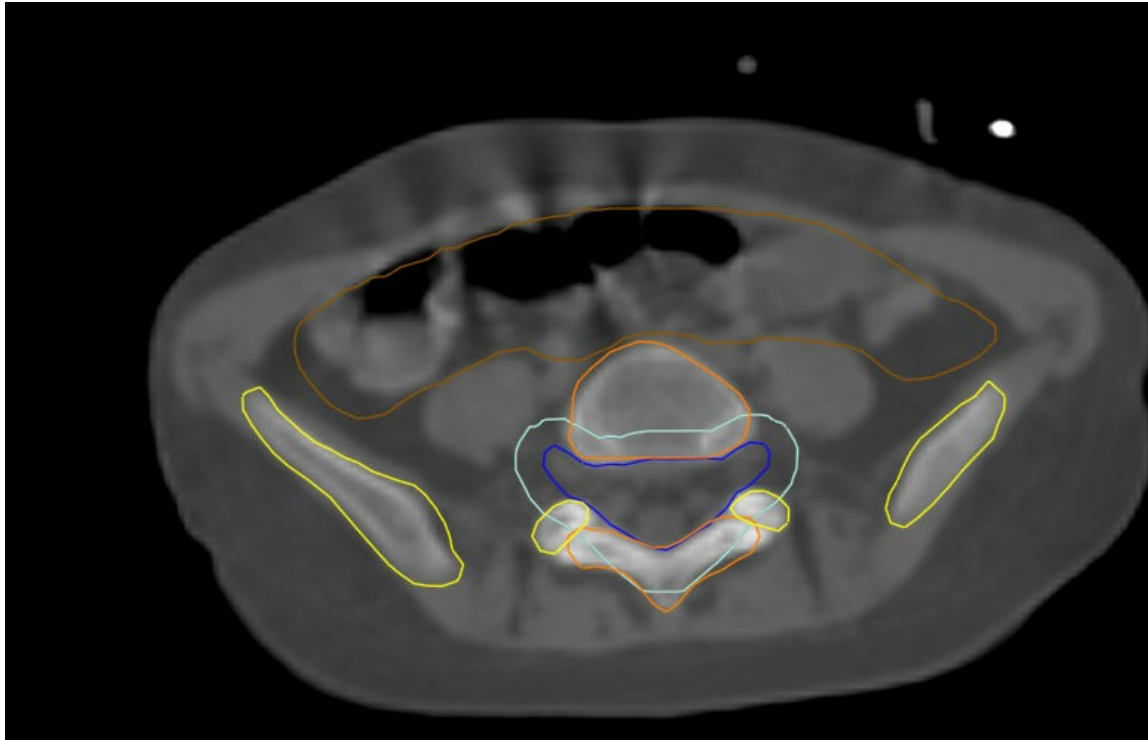
Vertebral body (VB) contours- to be covered by 18 Gy for skeletally immature patients (<13 yo). PTV_CSI-2340 in cyan, VB_1800 in red





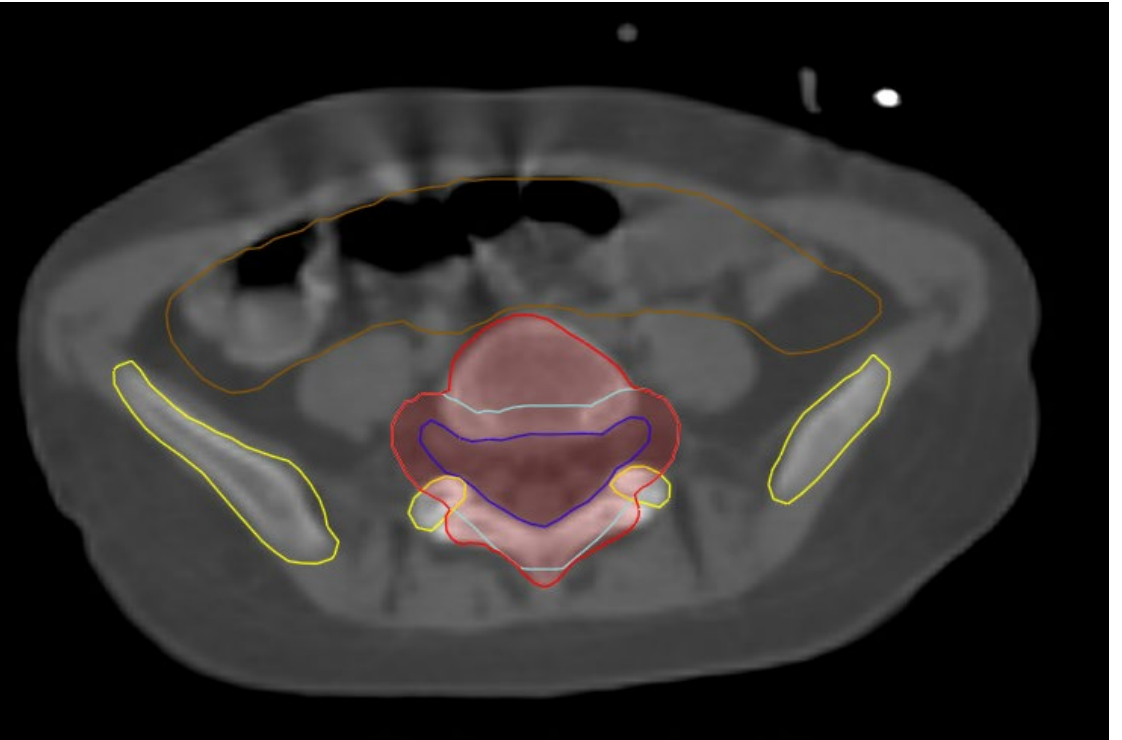


Vertebral Body Sparing

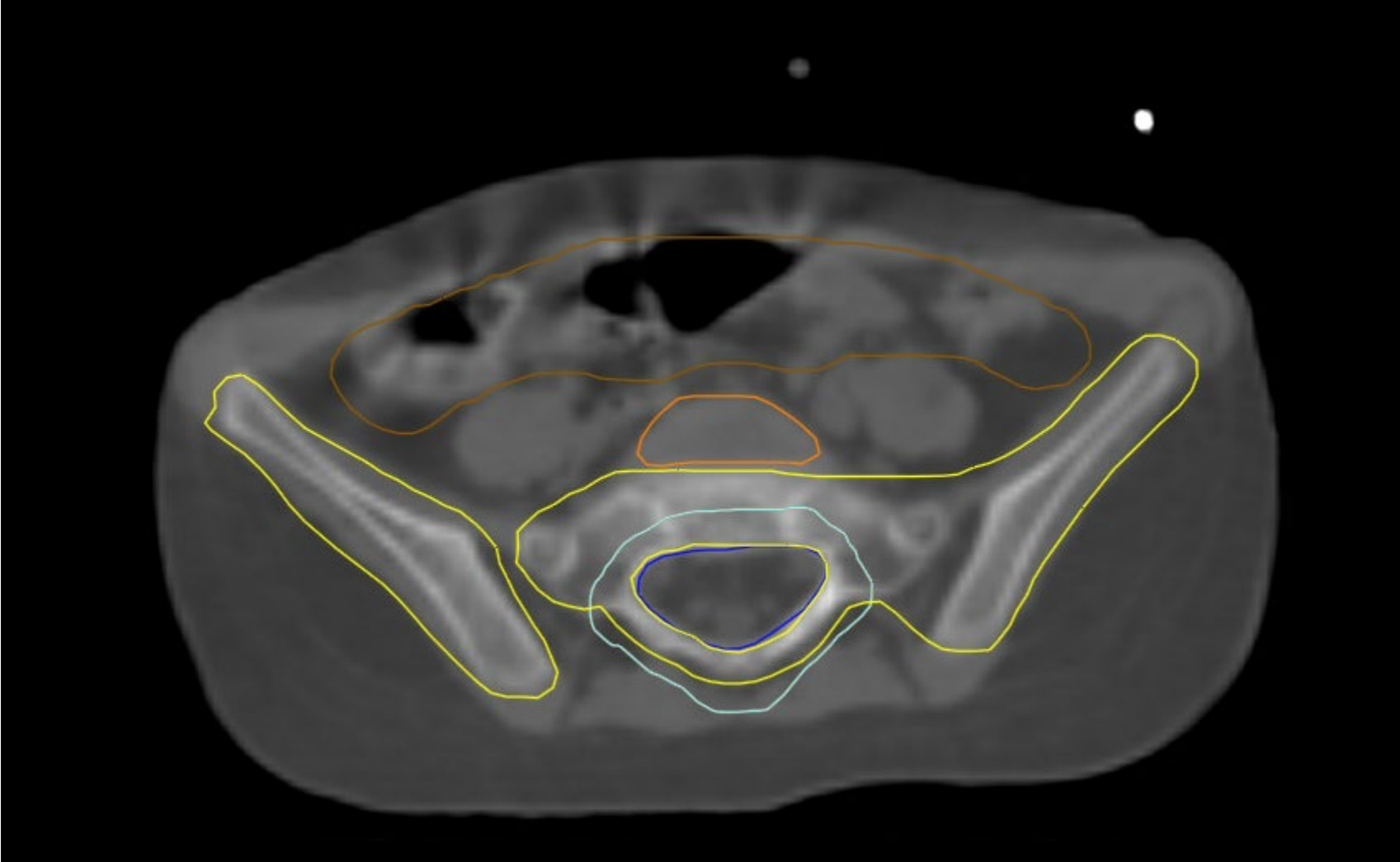


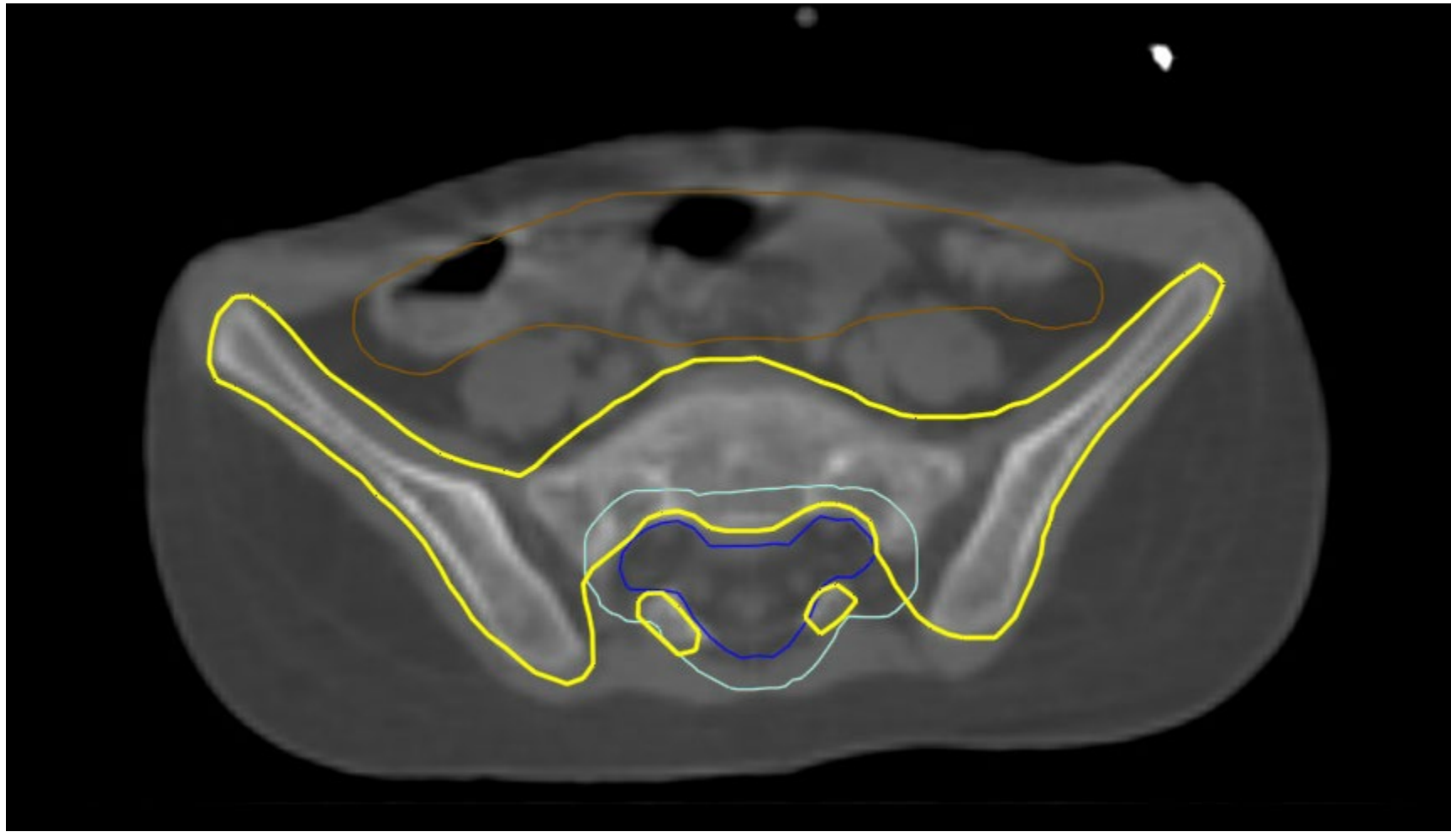
Non- Vertebral Body Sparing

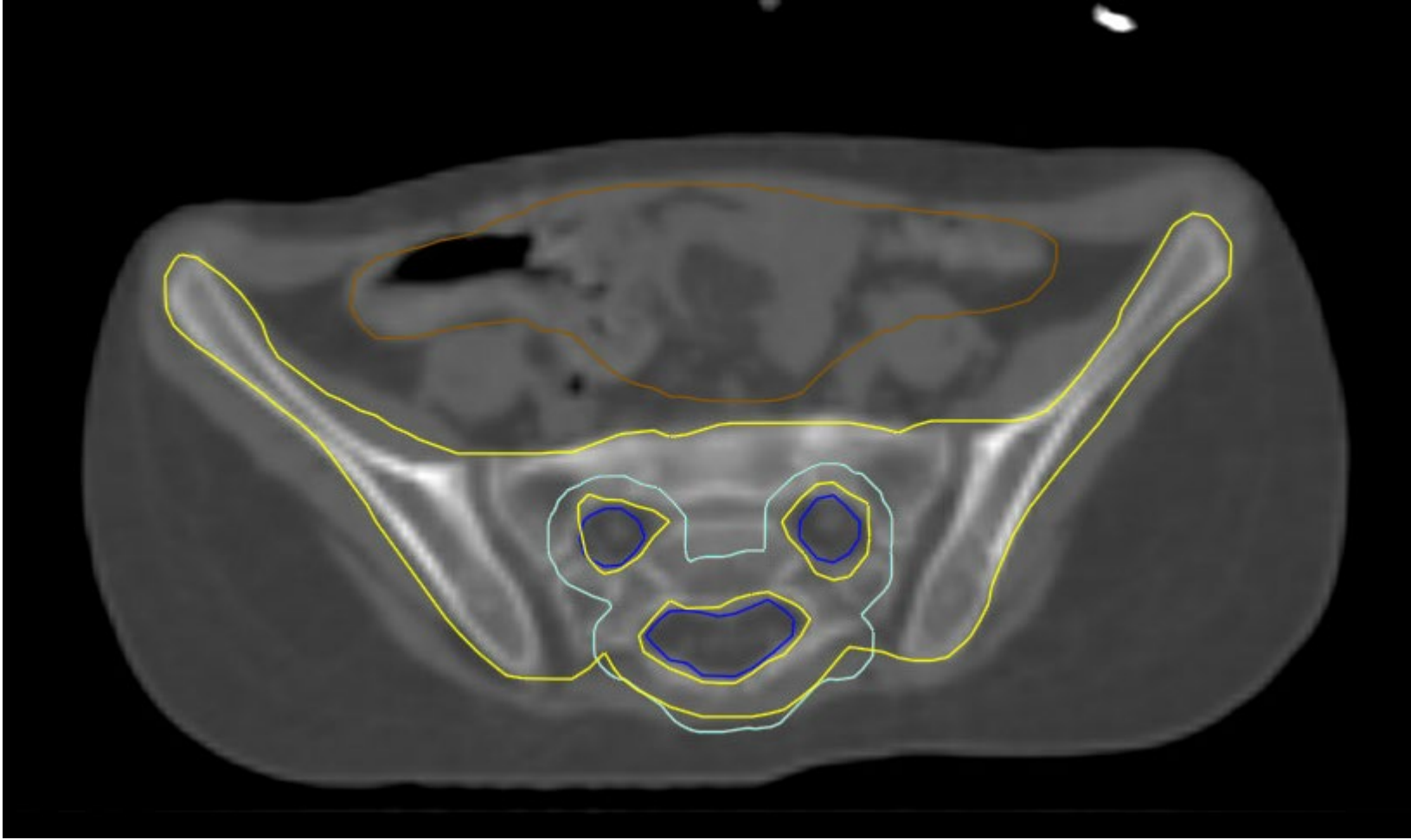
Vertebral body (VB) contours- to be covered by 18 Gy for skeletally immature patients (<13 yo). PTV_CSI-2340 in cyan, VB_1800 in red



Pelvic Bones- Yellow



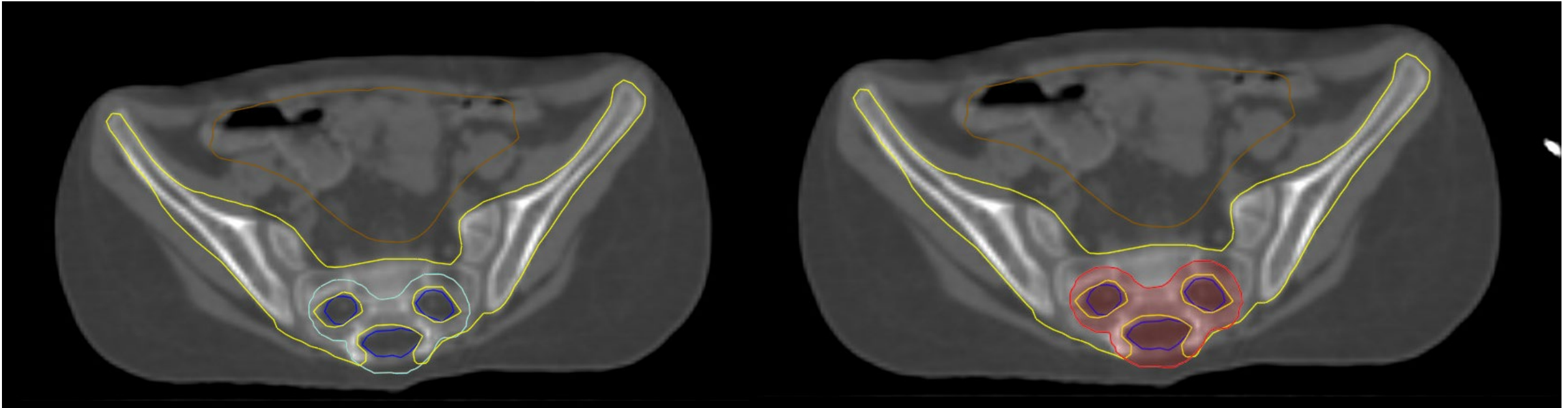


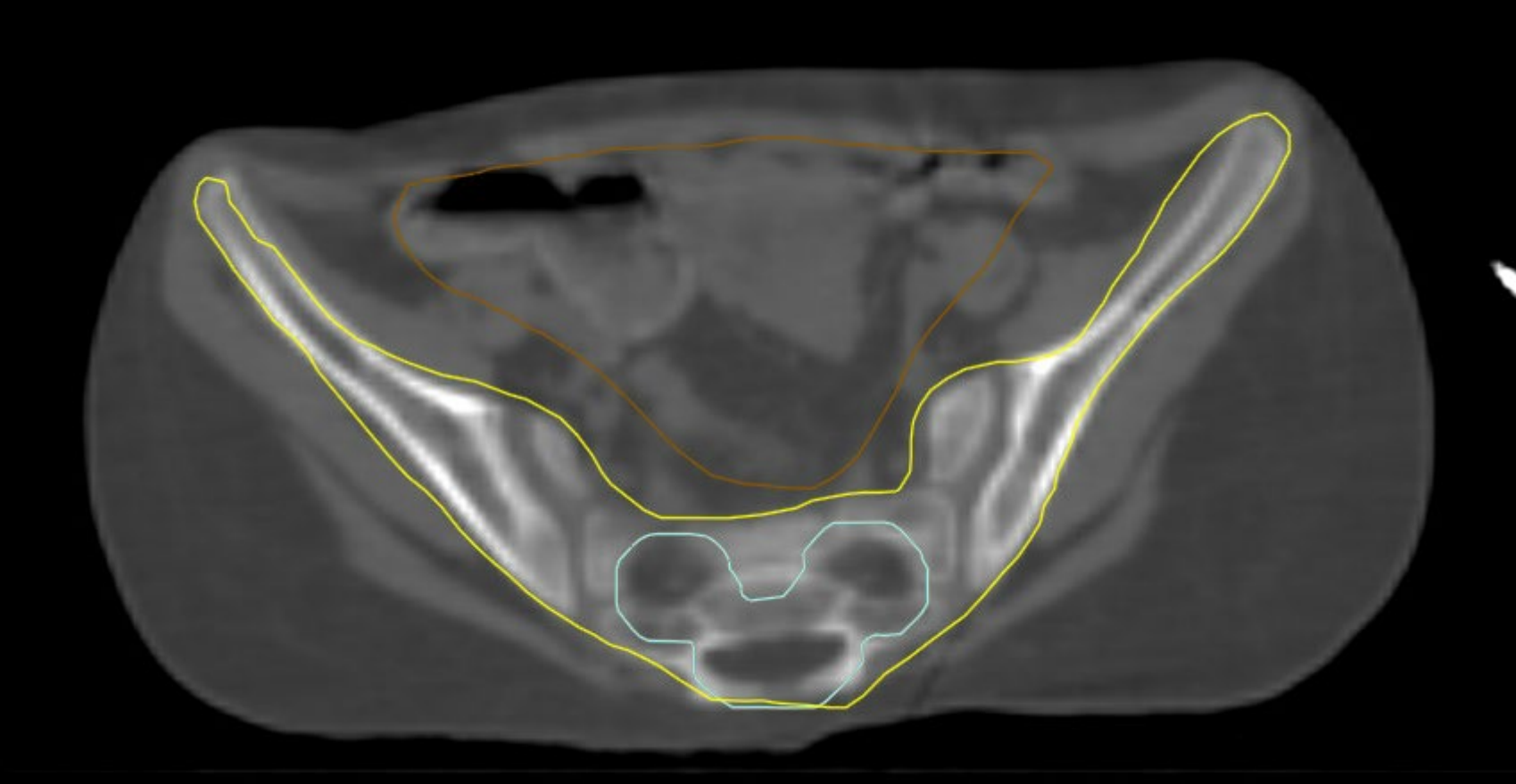


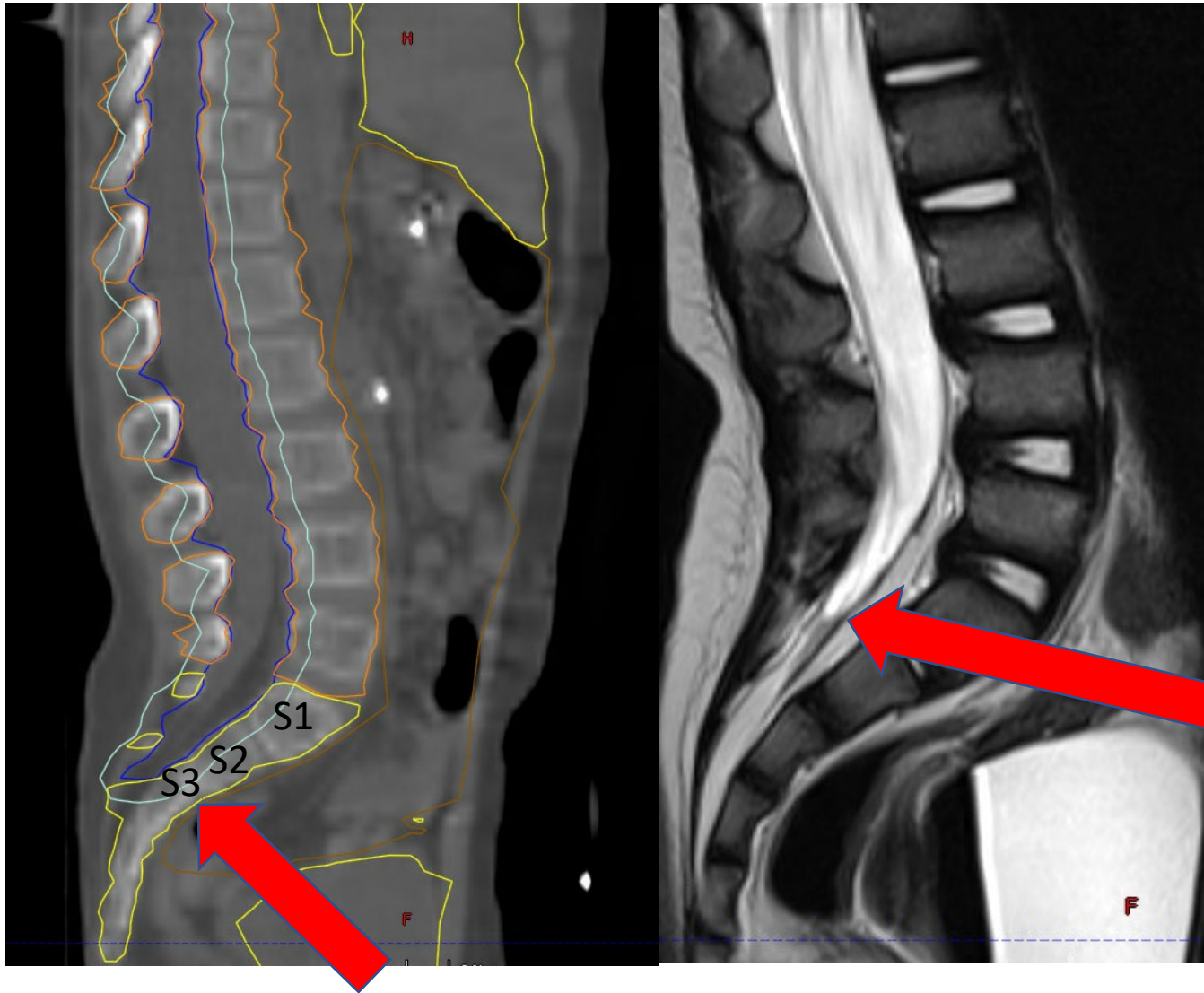
Vertebral Body Sparing

Non- Vertebral Body Sparing

Vertebral body (VB) contours- to be covered by 18 Gy for skeletally immature patients (<13 yo). PTV_CSI-2340 in cyan, VB_1800 in red







Inferior termination of the thecal sac (red arrow)

Best seen on Sagittal Lumbar spine T2 MRI (Right panel)

Inferior extent of CTV-spine (Red arrow) approximately 1.5 cm below the termination of the subdural space (thecal sac) usually S2/3 level