

Updates on Radiation Physics in Pediatric Tumors

Chia-ho Hua, PhD

Department of Radiation Oncology

St. Jude Children's Research Hospital, Memphis TN

Ken Ulin, PhD

University of Massachusetts Medical School, Worcester MA


IROC Rhode Island, Lincoln, RI

On behalf of Radiation Oncology Discipline Committee of
Children's Oncology Group, last updated on January 31, 2017

Disclosure

No conflict of interest.

Manufacturers and product names mentioned in this presentation are for illustration purpose only, not an endorsement of the products.



This educational slide set is divided into pediatric photon therapy physics and pediatric proton therapy physics, each with its own outline.



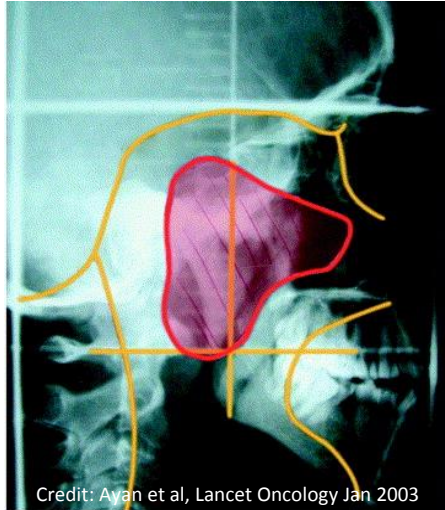
Pediatric Photon Therapy Physics

Outline for Pediatric Photon Therapy

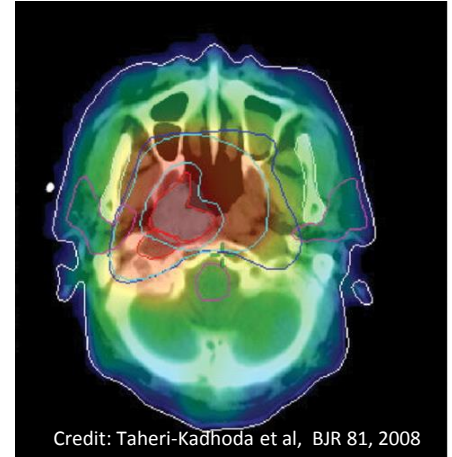
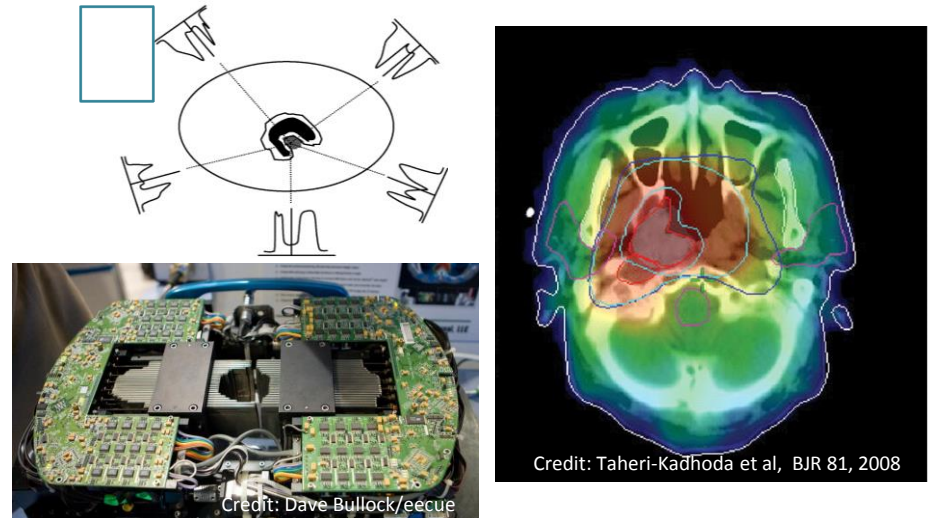
1. Radiation therapy techniques and contemporary delivery
2. Pediatric CT simulation – anesthesia, radiation exposure, respiratory motion
3. Pediatric MRI for RT planning
4. Pediatric RT planning – tradeoff and clinical trial guidelines
5. Image guidance for children receiving radiation therapy
6. Craniospinal Irradiation (CSI), Total Body Irradiation (TBI), and pediatric brachytherapy
7. VMAT for pediatric patients
8. Summary

Radiation Therapy Techniques

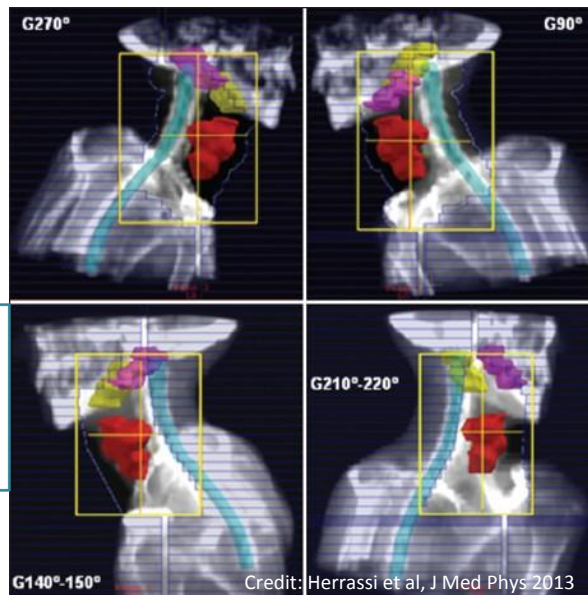
2D radiation therapy



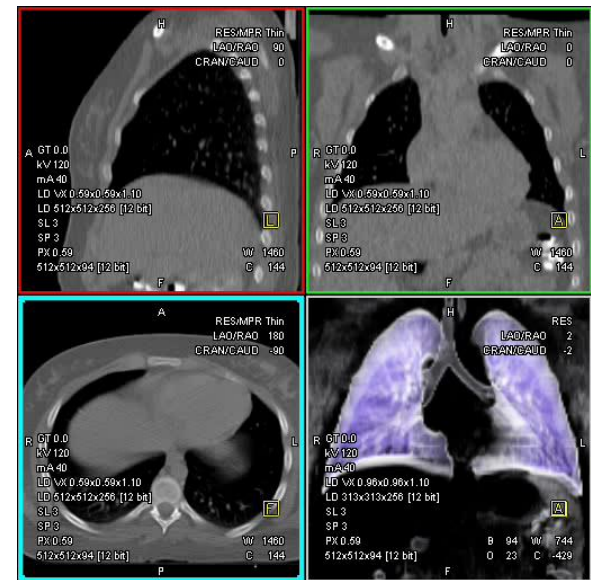
IMRT (Intensity Modulated) since early 2000



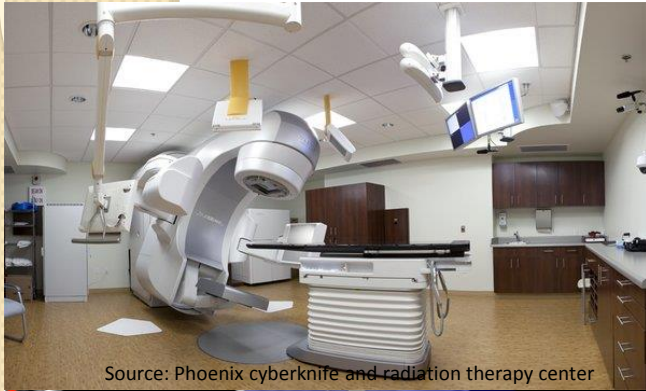3D conformal since 1990's



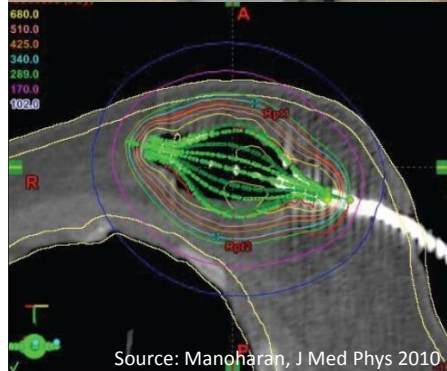
4D radiation therapy since 2000's



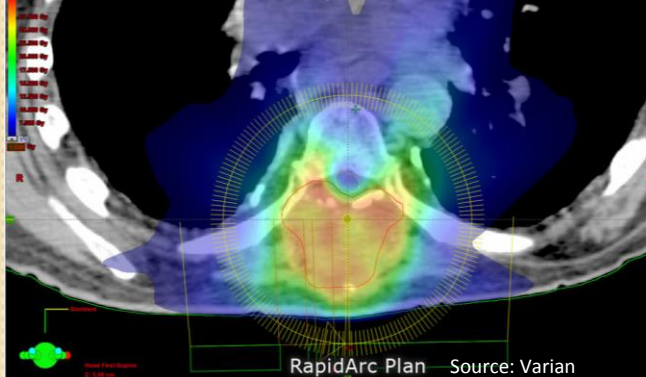
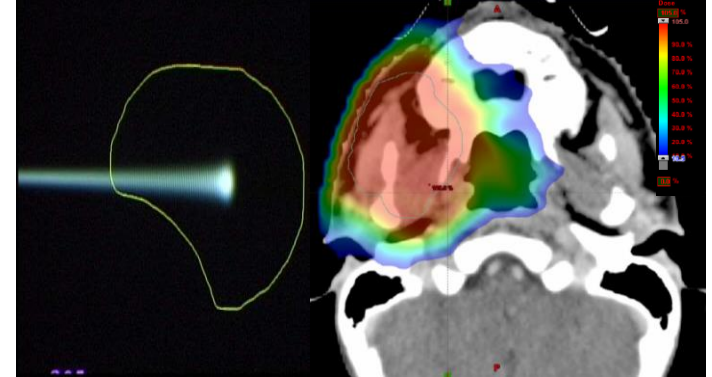

Contemporary Radiation Therapy Delivery



Source: Phoenix cyberknife and radiation therapy center



Source: Manoharan, J Med Phys 2010.

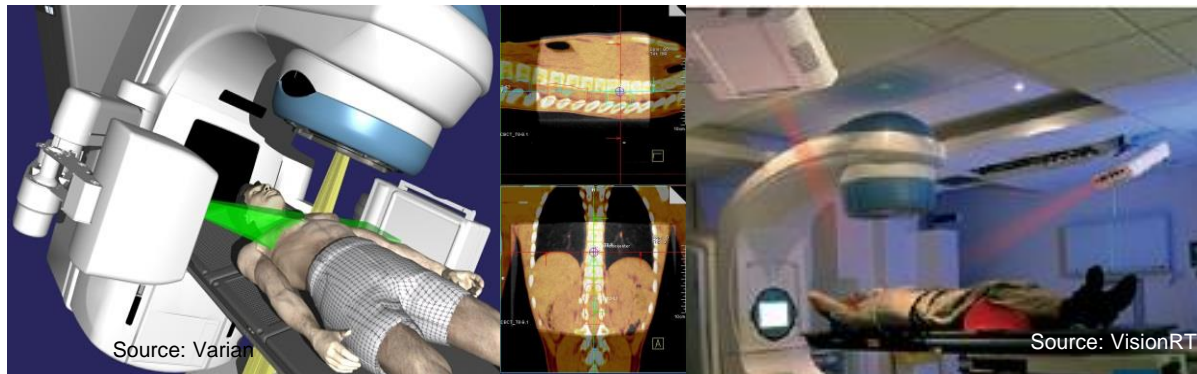


RapidArc Plan Source: Varian

External beam arc therapy

Brachytherapy

Intensity-modulated proton therapy (spot scanning)



Source: Varian

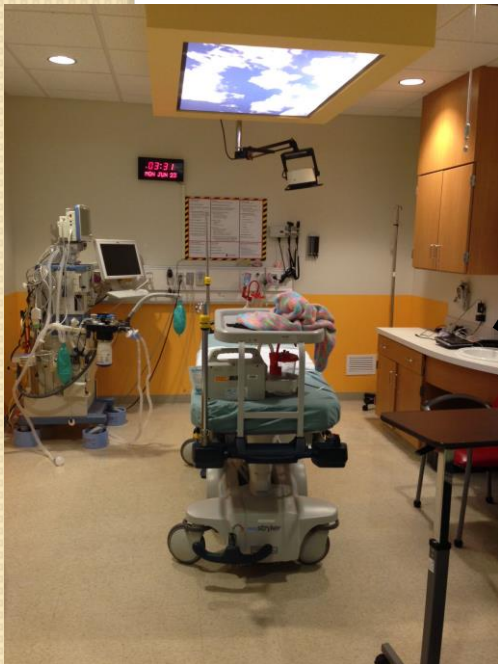Source: VisionRT

Image-guidance for patient setup and motion monitoring

Pediatric Simulation: Anesthesia

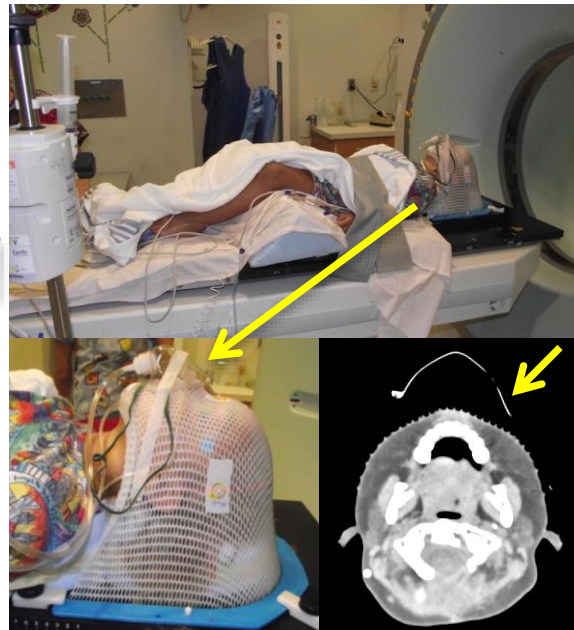
- General anesthesia with intravenous propofol to <7 years old and uncooperative older children at St. Jude Children's Research Hospital (~40% of treated children).
- Relevant publications – Anghelescu IJROBP 2008, Owusu-Agyemang Radiother Oncol 2014
- Longer simulation time (1-1.5 hr) and treatment time (30 min-1 hr), even when anesthetized outside.

Anesthesia induction room



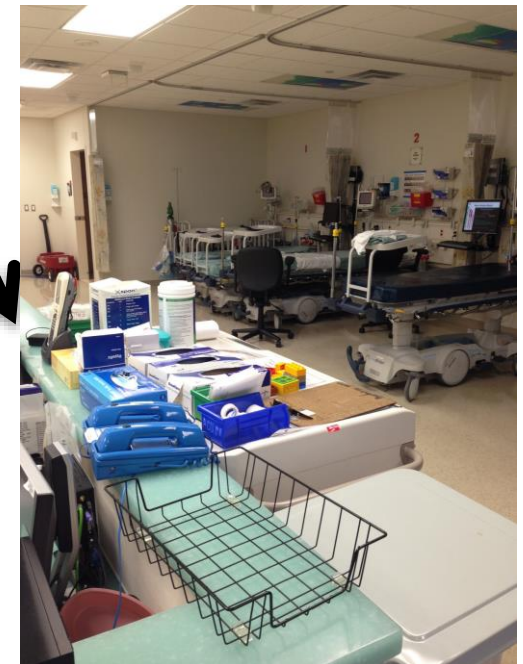
with parents/guardians present

CT sim

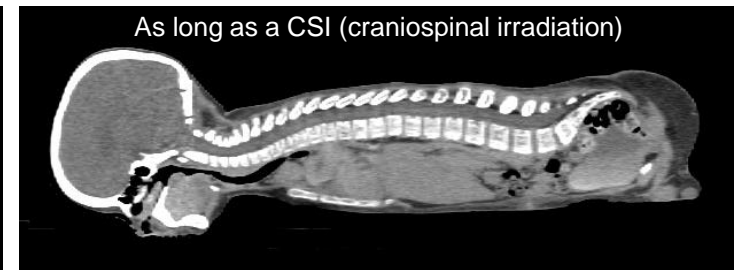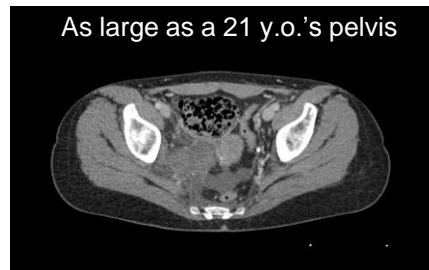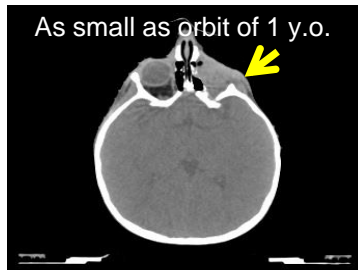


Supplemental oxygen is provided by face mask. Oxygen tubing is used for patients in prone position and for proton patients. In case of rare upper airway obstruction, oral airway or laryngeal mask airway are used, often affecting neck curvature.

Central anesthesia recovery



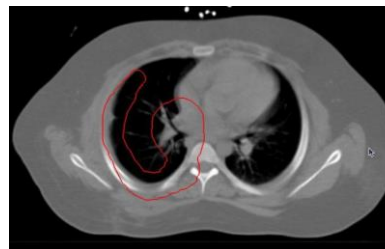
Pediatric Simulation: CT Sim



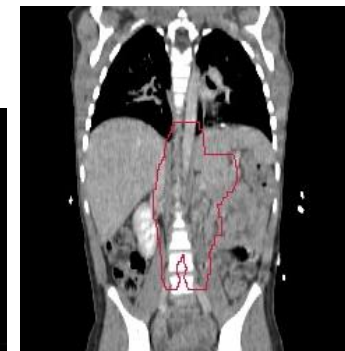- **Methods to reduce radiation exposure from CT scans for pediatric patients**
 - Select an appropriate scan protocol based on anatomical sites
 - Limit the body scanned to the smallest necessary area but cover enough to allow the use of non-coplanar beams
 - Use automatic exposure control such as tube current modulation (e.g. Siemens CARE Dose4D and Philips Dose-Right)
 - Statistical iterative reconstruction already commercially available
 - Be careful with changing kVp – affecting energy spectrum and calibration curve
- Consider tradeoff between radiation exposure and image quality for treatment planning. Having to repeat scans due to insufficient quality defeats the purpose.
- **Image gently** by The Alliance for Radiation Safety in Pediatric Imaging: What can I do as a physicist? <http://www.imagegently.org/WhatcanIdoasa/Physicist.aspx>
- AAPM SAM imaging course – Best practice in pediatric imaging MO-E-18A-1

Pediatric Simulation: Respiratory Motion

- Relevant to neuroblastoma, thoracic tumors and pulmonary mets
- Unlike high image contrast of adult pulmonary lesions, pediatric tumors often need surrogates (fiducials, OARs) to determine target motion.
- Adults 8-16 breaths/min, younger children 15-20 breaths/min, and infants much higher. Teenagers approach adult respiration rates and motion extent.



chest wall tumor



neuroblastoma

- Example: Adolescents showed a larger kidney motion in S/I than children but in general <10 mm.

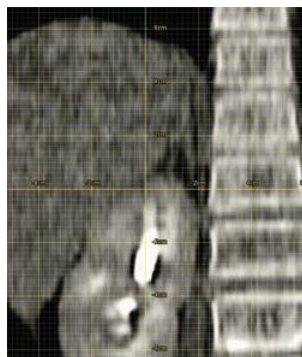


Table 1. Descriptive statistics of renal motion in pediatric patients grouped by age

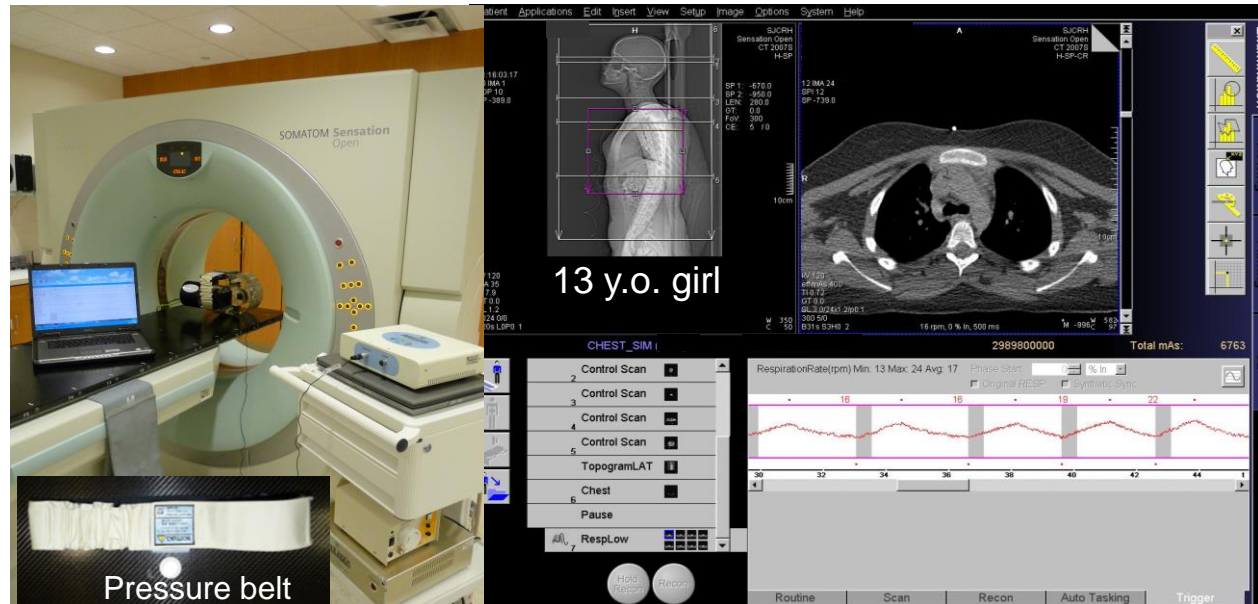
Patient group	n	Variable	Mean	SD	Med	Min	Max	Lower 95% CI*	Upper 95% CI*	
Young (2–8 years)	11	Age (years)	4.08	2.11	3.00	2.00	8.00	2.74	5.42	
		Height (cm)	101.91	20.52	97.00	79.00	152.10	88.87	114.94	
		Movement (mm)								
		Diaphragm	5.08	1.88	4.50	3.00	10.00	3.89	6.28	
		R kidney ML	0.69	0.23	0.70	0.40	1.20	0.54	0.85	
		L kidney ML	0.67	0.30	0.60	0.30	1.40	0.47	0.87	
		R kidney AP	0.70	0.39	0.50	0.30	1.70	0.44	0.96	
		L kidney AP	0.92	0.30	0.80	0.50	1.40	0.72	1.12	
		R kidney SI	1.91	0.93	2.00	0.60	3.70	1.28	2.54	
		L kidney SI	1.72	0.81	1.60	0.70	3.40	1.17	2.26	
Old (9–18 years)	9	Age (years)	12.33	3.35	12.00	9.00	18.00	9.76	14.91	
		Height (cm)	151.20	14.11	149.00	132.10	175.50	140.36	162.04	
		Movement (mm)								
		Diaphragm	9.56	3.57	8.00	7.00	17.00	6.81	12.30	
		R kidney ML	1.14	0.52	1.10	0.60	2.20	0.74	1.55	
		L kidney ML	0.86	0.48	0.70	0.50	2.10	0.49	1.22	
		R kidney AP	1.36	0.44	1.40	0.90	2.30	1.02	1.69	
		L kidney AP	0.94	0.43	0.90	0.40	1.70	0.62	1.27	
		R kidney SI	3.90	1.71	3.60	1.50	6.30	2.59	5.21	
		L kidney SI	3.07	1.24	3.40	0.80	4.60	2.11	4.02	

Abbreviations: AP = anteroposterior; CI = confidence interval; L = left; ML = mediolateral; Max = maximum; Med = median; Min = minimum; R = right; SD = standard deviation; SI = superoinferior.

* Lower and upper limits of the 95% confidence interval are shown.

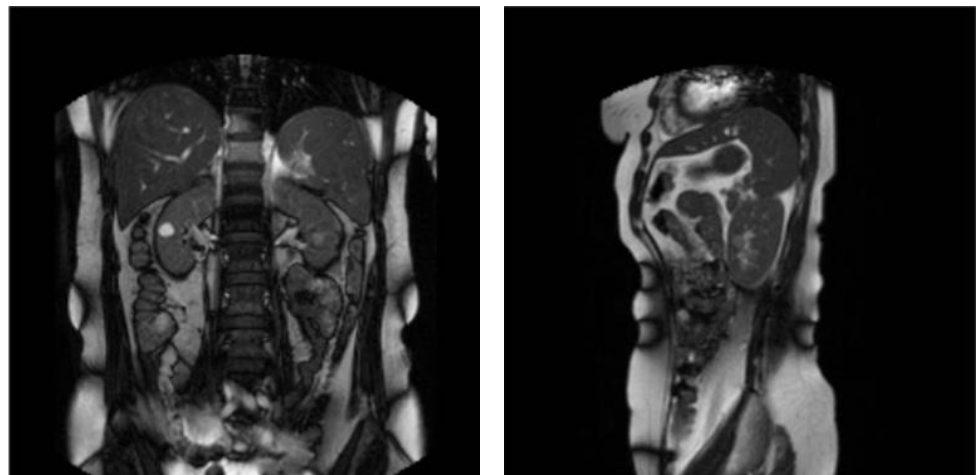
Pediatric Simulation: Respiratory Motion

- St Jude 4DCT protocol:
measured CTDI of 33 mGy (32cm diameter plastic body phantom).
120 KV, 400 effective mAs,
0.5-1s rotation
0.1 pitch, 3mm slice,
1.2 mm collimation



Hua et al, Med Phys 2009;36:2726

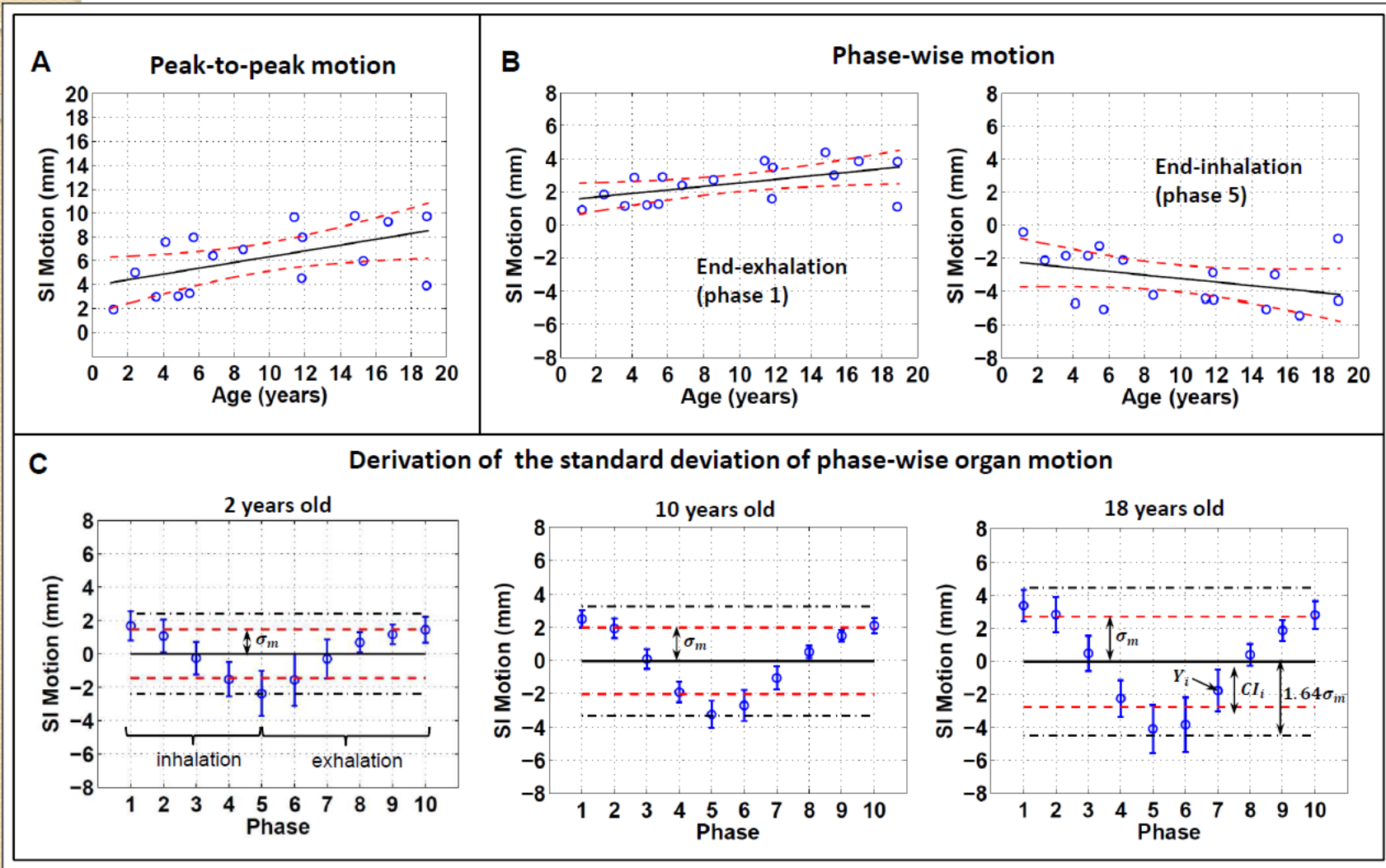
- 2D cine MRI or 4D MRI may be a good alternative for assessing the motion extent due to no radiation exposure to children and better soft tissue contrast. But motion could be out of 2D plane and pixel resolution is often lower than CT.



Stam et al, Phys Med Biol 2013;58:2235-2245

Pediatric Organ Motion Measured with 4D MRI

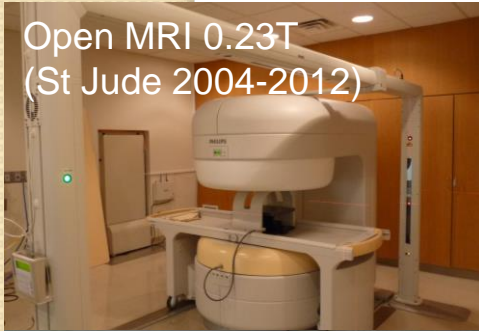Liver dome (diaphragm) motion



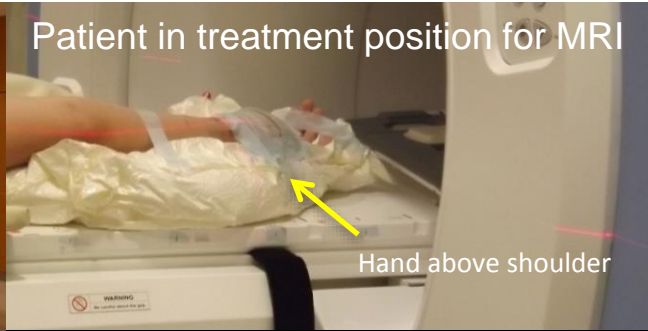Pediatric MRI for RT

- MRI is essential for delineating CNS tumors and the majority of solid tumors.
- MRI is helpful for critical organ delineation in children (e.g., ovary, thyroid).
- MRI in treatment position is preferable for registration.
- More RO department now have dedicated MR scanners with lasers and flat table top.
- Vendors start to offer radiation oncology configurations with RF coils to accommodate immobilization devices although not specifically designed for children.

Open MRI 0.23T
(St Jude 2004-2012)

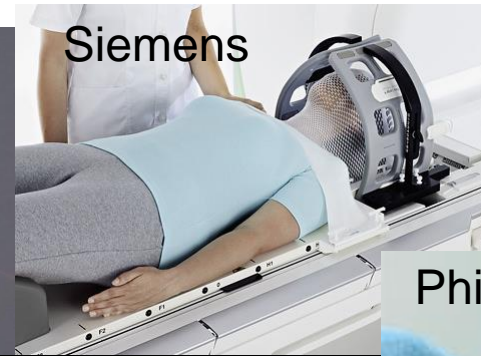

Patient in treatment position for MRI



Hand above shoulder

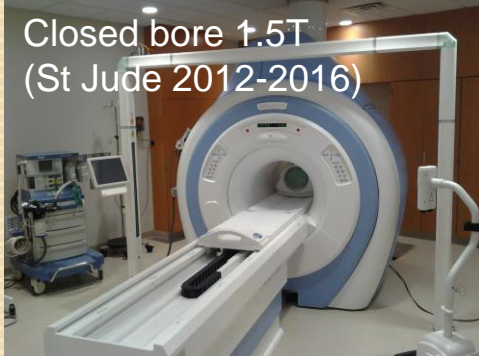Siemens



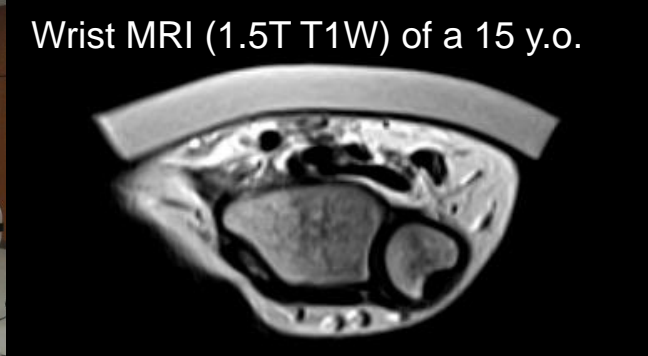
Philips




Closed bore 1.5T
(St Jude 2012-2016)



Wrist MRI (1.5T T1W) of a 15 y.o.



GE



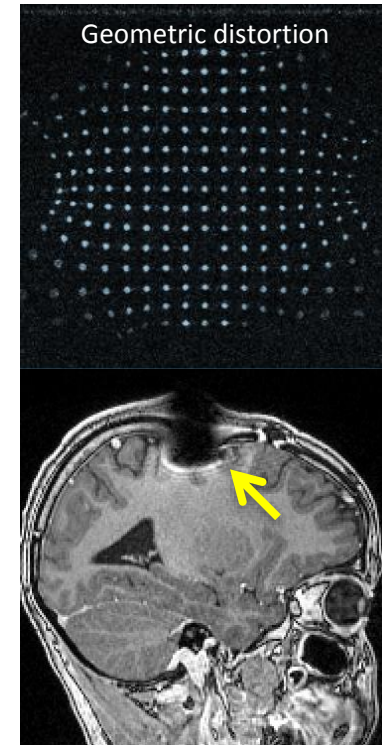
Pediatric MRI for RT

- **Watch out for spatial distortion**

- ❑ Position target within the high homogeneity region of the magnet (important for tumors in extremity, shoulder, skin surface)
- ❑ Paramagnetic objects causing local distortion (orthodontic braces, CSF shunts – common in children)
- ❑ Focus on target region when registering MRI to CT
- ❑ Monitor the spatial distortion regularly with QA

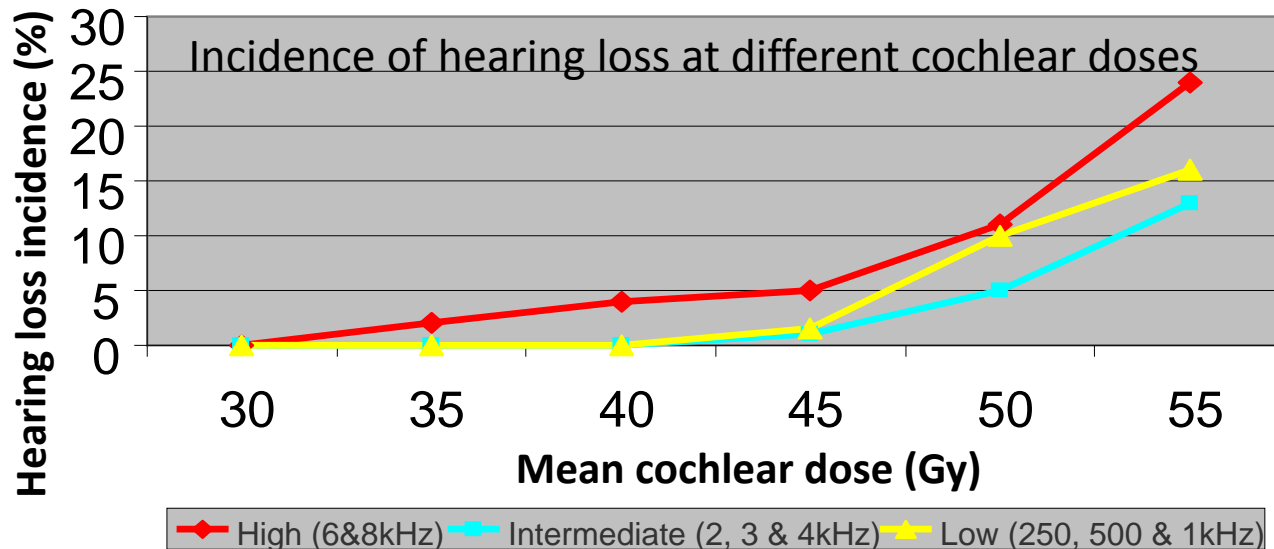
- **MRI pulse sequences for pediatric MR sim**

- ❑ Perform important sequences first and keep them short in case unsedated children becoming agitated after a few minutes
- ❑ Isotropic high resolution 3D imaging (e.g. 1mm T1W MPRAGE) good for reformatting
- ❑ Fast sequences to minimize motion artifacts in thorax and abdomen (e.g. BLADE)
- ❑ Sequences to reduce artifacts from blood vessel and CSF pulsations often seen in children (e.g. in posterior fossa region of the brain)
- ❑ Close monitoring for increased heating from high SAR sequences in young children

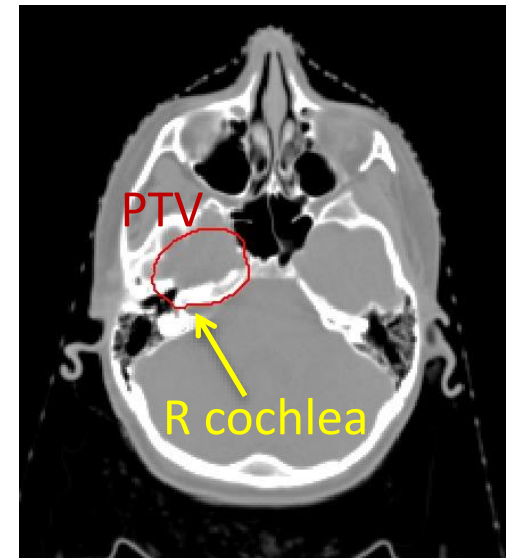


RT Planning: Normal Tissue Sparing Vs. Tumor Coverage

Normal tissue sparing is important but don't over protect at the expense of tumor coverage.
Example: Currently a conservative planning constraint of Dmean to cochlea <35Gy is often recommended for preserving hearing after RT.



Hua et al, IJROBP vol 72, p892-899, 2008



RT Planning: PENTEC Reports

Adults

QUANTEC (QUantitative Analysis of Normal Tissue Effects in the Clinic) reports, published in 2010, reviewed dose-volume-outcome data of normal tissues in adults and recommended dose/volume constraints for treatment planning.



Children and Adolescents

PENTEC (PEdiatric Normal Tissue Effects in the Clinic) group has been formed to achieve the same goals for pediatric cancer patients receiving radiation therapy. Treatment planning guidelines will be provided for a variety of pediatric organs. (2014 AAPM presentation MO-D-BRF-1)

Handouts are available on AAPM website:

<http://www.aapm.org/meetings/2014am/PRAbs.asp?mid=90&aid=25219>

RT Planning: Clinical Trial Guidelines

- Many pediatric patients are enrolled on clinical trials (COG, PBTC, other consortia, institutional trials) and treated per guidelines. The best resource is in the section of radiation therapy guidelines of the protocol.
- Different trials may have different RT guidelines (allowed treatment techniques, target definition and dose, OAR constraints, data reporting) due to principal investigator's preference and difference in treatment regimens.

e.g. ARAR0331 for childhood nasopharyngeal carcinoma (61.2-66.6 Gy)

High priority

Spinal cord	max dose 45 Gy or 1 cc can not exceed 50 Gy
Mandible/TM joint	no more than 1 cc exceeding 77 Gy
Temporal lobes	max dose 65 Gy, no more than 1 cc exceeding 60 Gy
Brainstem	max dose 60 Gy, no more than 1 cc exceeding 54 Gy
Optic nerve and chiasm	max dose 60 Gy, no more than 1 cc exceeding 54 Gy

Low priority

Parotid	mean dose \leq 26 Gy to at least one gland
Oral cavity	mean dose \leq 40 Gy, no more than 1 cc exceeding 70 Gy
Cochlea	mean dose $<$ 40 Gy
and glottic larynx, eyes, lens, pituitary, unspecified tissues	

Image Guidance: Approaches and Imaging Frequency

- Pediatric IGRT approaches – implanted fiducials, EPID/2D orthogonal X-rays, CBCT, CT on rail, optical tracking/surface imaging, and MRI.
- **IGRT practice for children**
 - ❑ Survey of 80 COG member institutions in 2004 – 88% performed portal imaging once per week (Olch et al IJROBP 2004).
 - ❑ Survey of 9 international institutions with dedicated pediatric expertise – IGRT was used daily in 45% and weekly in 35% of pediatric patients. >50% CNS patients had daily IGRT. All photon institutions equip kV CBCT (Alcorn et al PROS 2014).
 - ❑ St. Jude performs daily CBCT for all patients except TBI, TLI and CSI (3mm PTV margin for brain cases, 3-5 mm for body). Higher imaging dose than weekly but allow tighter margins and occasionally detect anatomy changes.

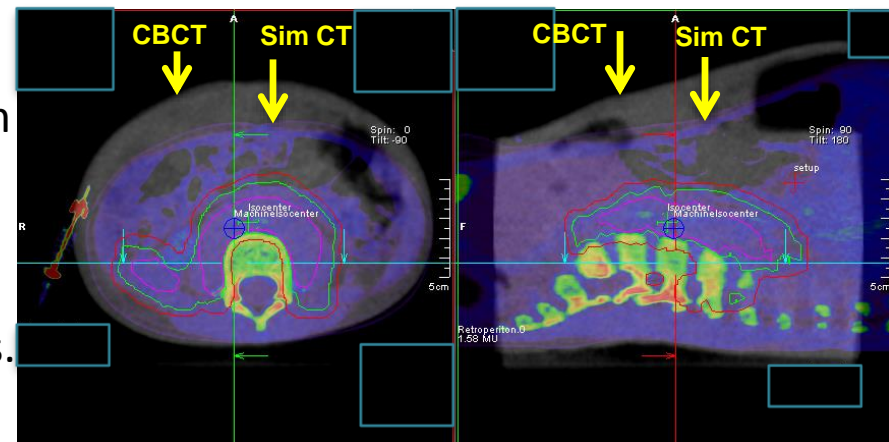
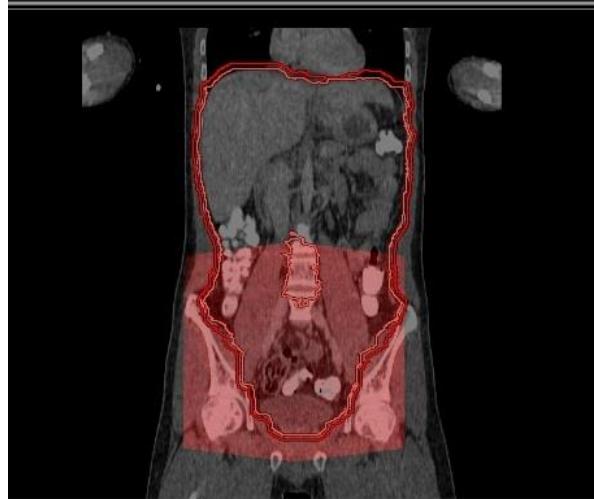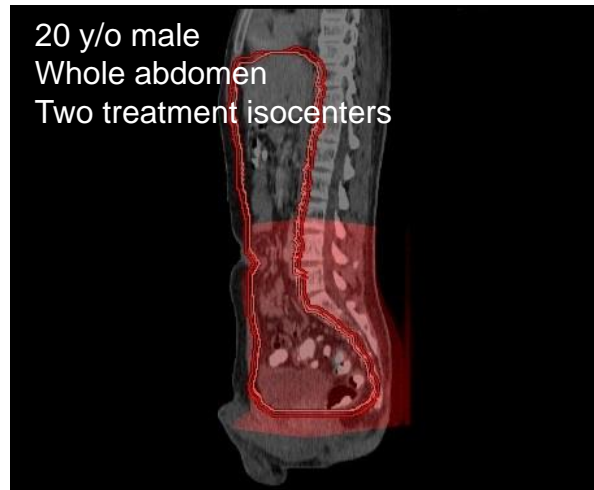


Image Guidance: Variation in Target Volume and Location

St. Jude example CBCT cases (w Siemens in-line KView CBCT)

As large as whole abdomen



As small as a finger

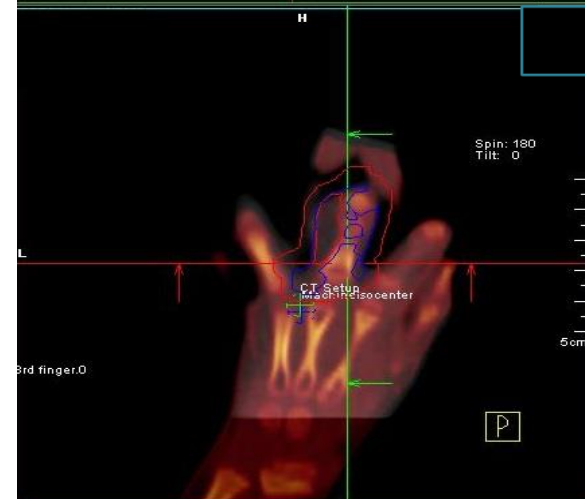
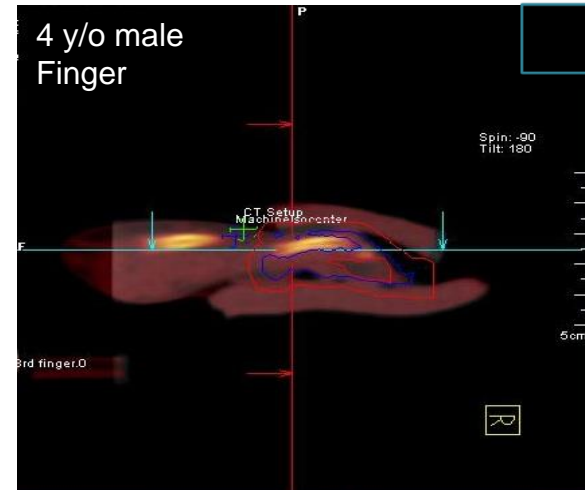


Image Guidance: CBCT Dose Reduction

KV CBCT dose has been reported to be as low as 2-3 mGy for pediatric head in recent versions. Bones and surface doses are higher.

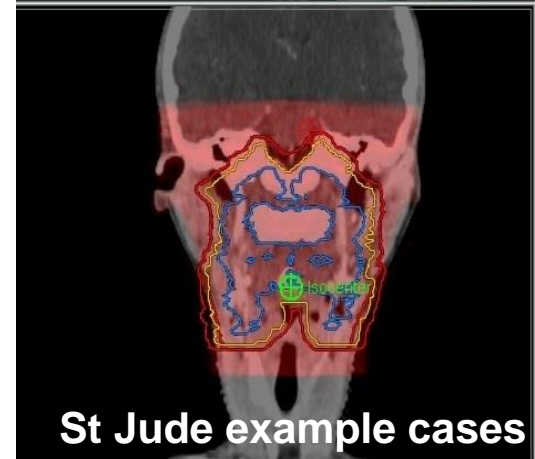
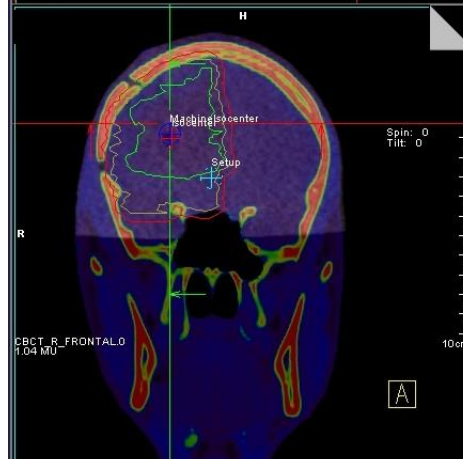
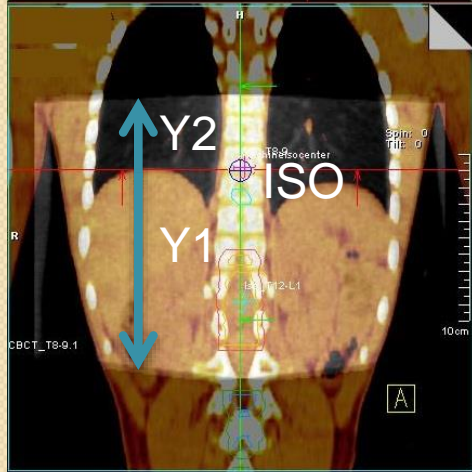
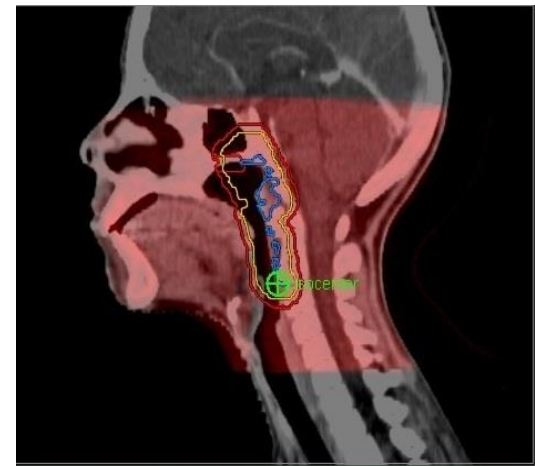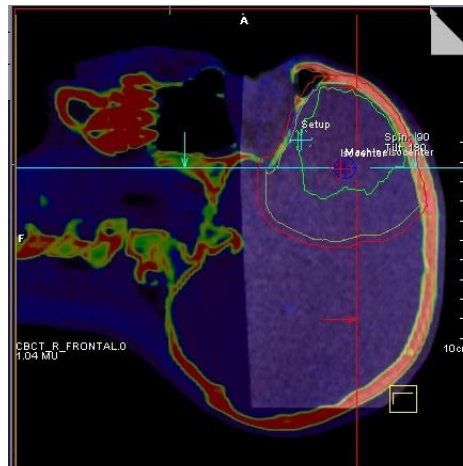
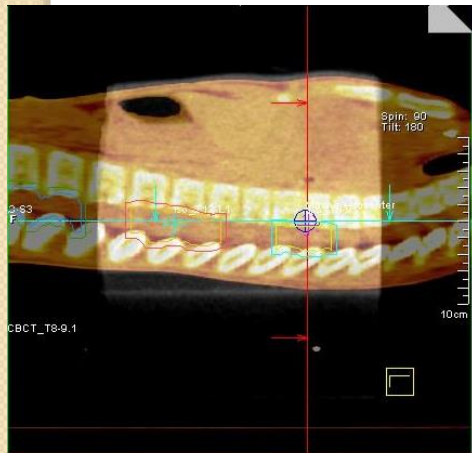
Dose Reduction Strategies

- Increasing beam hardening by adding the copper/aluminum filter at the source side
- Reducing the length of the patient being irradiated by adjusting the collimator blades for each individual patient
- Using the X-ray technique that best matches the clinical task – reducing beam current and exposure time per projection for smaller patients
- Selecting the direction of the KV beam to avoid sensitive structures – partial arc acquisition
- Using bow-tie filters to reduce skin dose in large patients
- Low-dose protocols may be sufficient for verification purposes

Image Guidance: Collimation to Reduce Scan Length and Dose

Longitudinal asymmetric collimation is needed for pediatric CBCT

- To minimize exposure to thyroid, lens, testes, heart, and previously irradiated spinal cord
- To include additional anatomic landmarks (orbit, vertebral body) for improved image registration
- To cover two neighboring targets with one CBCT while using one treatment isocenter as the imaging isocenter

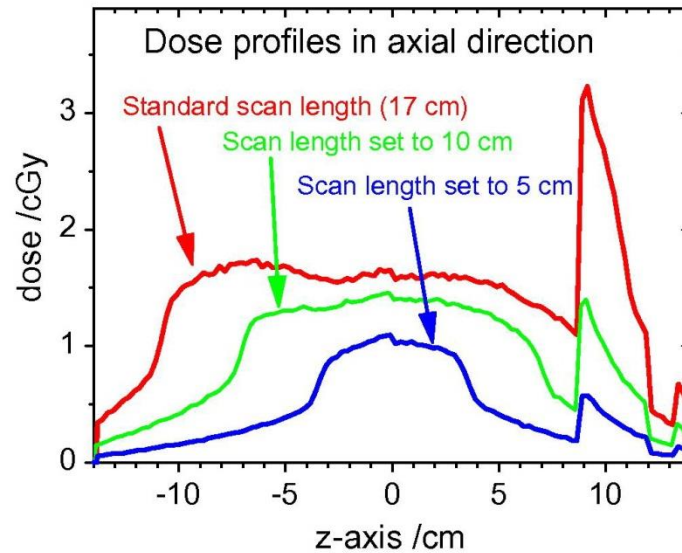
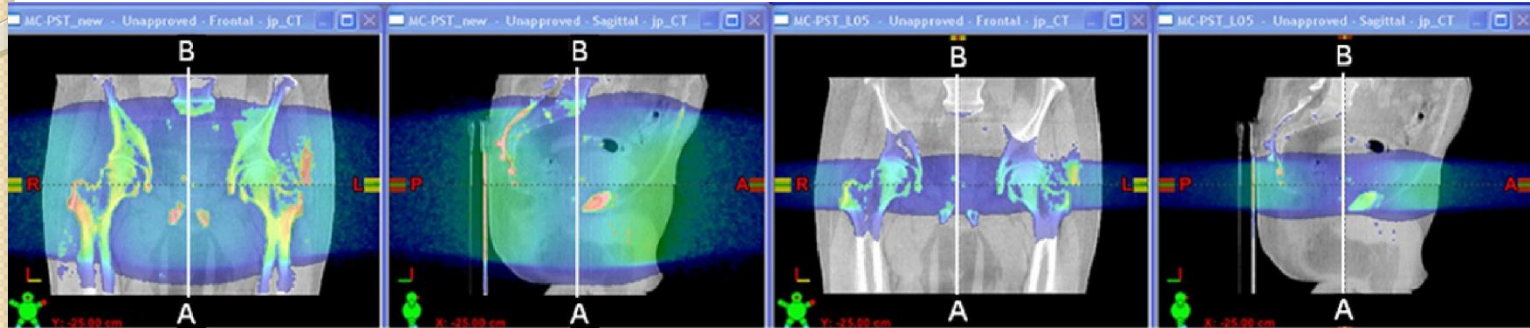


St Jude example cases

Image Guidance: Collimation to Reduce Scan Length and Dose

Length=16cm

Length=5cm



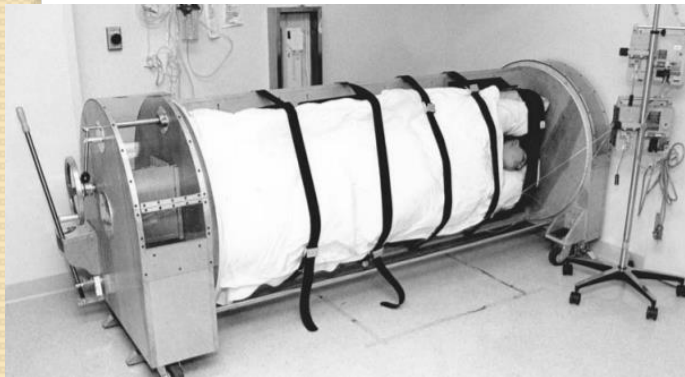
Craniospinal Irradiation (CSI)

- CSI typically consists of irradiating the whole brain and the entire spine in multiple fields with the patient in either supine or prone position. Prone was preferred for direct visualization of light field but supine is getting popular due to easy airway access, patient comfort, and the advent of image guidance.
- CSI of 18-39.6Gy is mostly delivered to patients with medulloblastoma and selected brain tumors. Coverage of cribriform plate region and sparing of optical lens are important in treatment planning.
- Traditionally CSI was delivered with 3D CRT but VMAT and Tomotherapy has become popular as well as proton therapy. Descriptions and comparisons of different techniques (photon vs. electron, VMAT, Tomotherapy) can be found in these articles and slides.

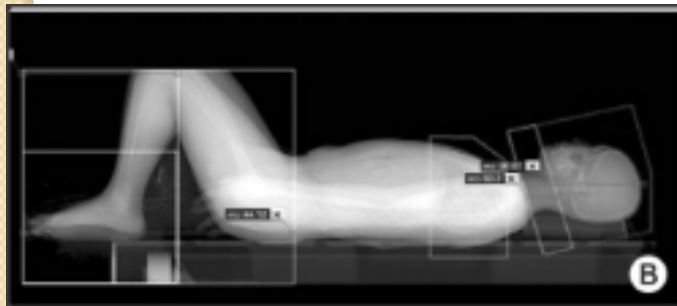
Verma et al (supine vs. prone, MDACC) *Prac Radiat Oncol* 2015,
Chojnacka et al (electron vs. photon) *Rep Pract Oncol Radiother* 2010,
Burkeen et al (Johns Hopkins review) ASTRO & ARRO education slides 2014 at
https://www.astro.org/uploadedFiles/_MAIN_SITE/Affiliate/ARRO/Resident_Resources/Educational_Resources/Content_Pieces/MedulloblastomaAJW.pdf
Landry et al (VMAT) medical dosimetry <http://pubs.medicaldosimetry.org/pub/2570d6bd-de0a-46fc-9e24-0bac2d38f55e>
Myers et al (3D CRT, VMAT, Tomotherapy) *Technol Cancer Res Treat* 2015
Barra et al (3D CRT vs. Tomotherapy) *Tumori* 2016
Mesbah et al (Tomotherapy for pediatric RT) *Radiat Oncol* 2011
Bedford et al (helical VMAT) *Int J Radiat Oncol Biol Phys* 2012
Hansen et al (noncoplanar IMRT vs. VMAT) *Med Dosim* 2015

Total Body Irradiation (TBI)

- TBI is mostly given to patients with acute lymphoblastic leukemia (ALL) before stem cell (bone marrow) transplant.
- TBI can be given with patients either standing or lying down on the floor or table. Radiation can be delivered in AP/PA or opposed lateral beams.
- Lungs are the sensitive organs, may or may not be protected with partial transmission blocks.



Rotating TBI bed, St Jude Children's Research Hospital



Park et al. Radiation Oncology Journal 2014

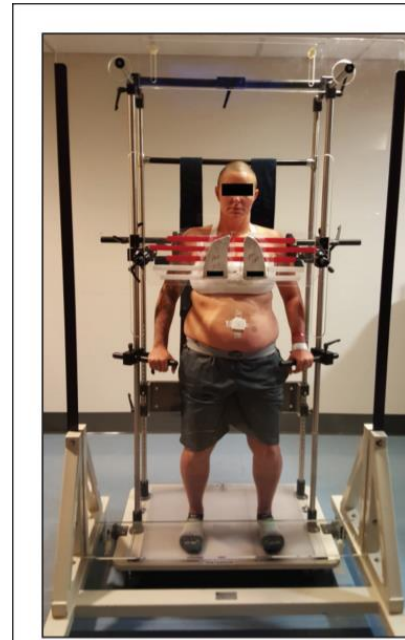


FIGURE 1. This patient is in the upright position with a bicycle seat for support. Lung blocks are suspended in front of the patient, with positioning confirmed by plain films. A plexiglass beam spoiler is positioned in front of the patient.

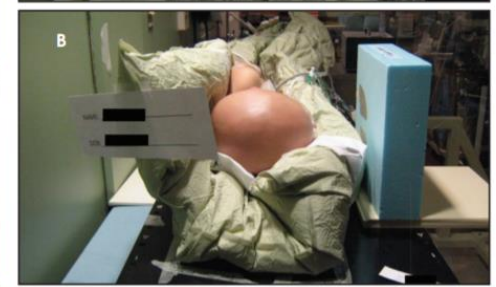
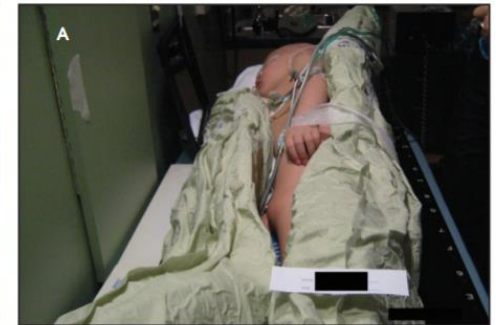
FIGURE 2. (A) In this setup, used exclusively in small children, a patient under general anesthesia can still be treated with anterior-posterior and poster-anterior fields by placing the patient on his side within a vacuum bag. (B) The same patient with lung blocks within a blue Styrofoam block in place for the anterior-posterior beam.

Carson et al, Applied Radiation Oncology, 2016

Total Body Irradiation (TBI)

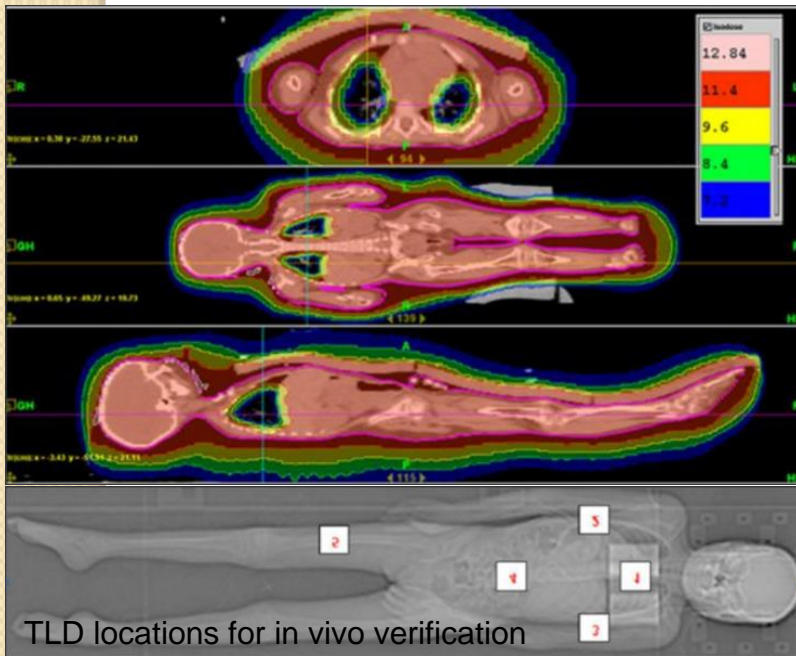
Although TBI has been traditionally delivered in children and young adults with linacs, Tomotherapy (helical mode or static mode) is another viable option.

Helical Tomotherapy

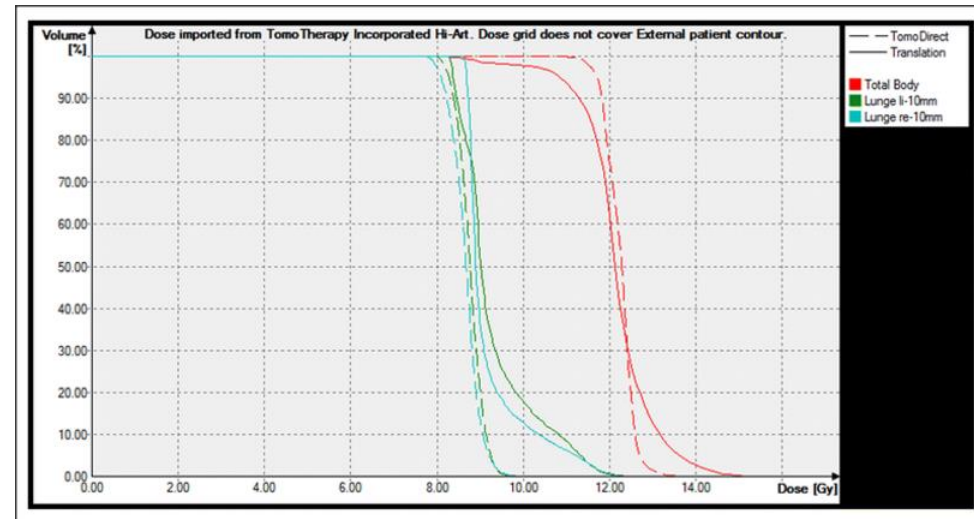
Supine position, head support and vacuum cradle
 CT head-toe, planning structures of reduced body and lung volumes
 Constraints: 95% PTV by 95% of prescribed dose (12Gy)
 Constraints: mean lung dose <10Gy and Dmin=8Gy
 Ion chamber and TLD measurements for QA
 Pre-treatment MVCTs for image guidance

Static Tomotherapy (TomoDirect)

Supine position, vacuum cushion
 CT planning
 PTV=body without 5mm skin
 If having to split treatment into two parts, an overlap region is created with a gradual dose gradient
 Constraints: median lung dose <9Gy and V8Gy>90%
 TLD and Delta4 phantom measurements for QA
 Pre-treatment MVCTs for image guidance



Gruen et al. Radiat Oncol, 2013:8:92



Higher homogeneity in target and lower max dose in lungs when compared to conventional translational methods with lung blocks.

Salz et al. Radiat Oncol, 2015:10:58

VMAT for Pediatric Patients

- VMAT (rotational therapy) is a variant of IMRT.
- Traditional IMRT and VMAT have been routinely used to treat complex pediatric tumors.
- Reported advantages of VMAT are the reduced treatment MU and time when compared to IMRT delivered with multi-fields with MLC. Long-term effect of low dose bath is often the concern in pediatric patients.
- VMAT has been applied to many pediatric tumors, including tumors in CNS, thorax, extremity, total marrow irradiation, and CSI.

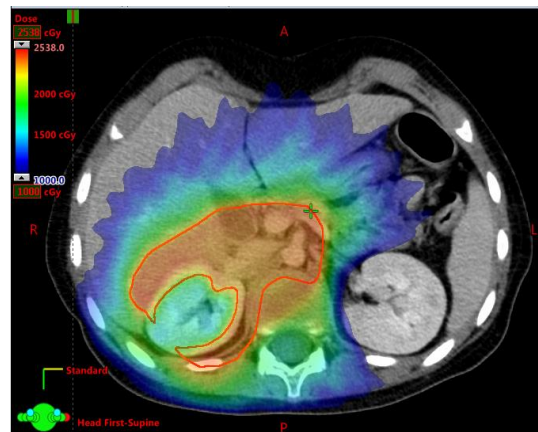
Normal tissue dose in pediatric VMAT

Piotr Zygmanski

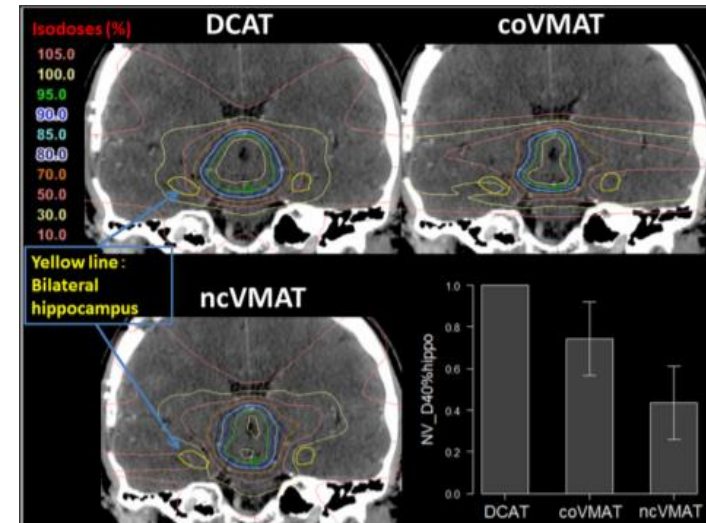
Department of Radiation Oncology
Brigham and Women's Hospital



http://chapter.aapm.org/NE/DOCUMENTS/Presentations/2010WinterMeeting/VMAT_NEAAPM_2010.pdf



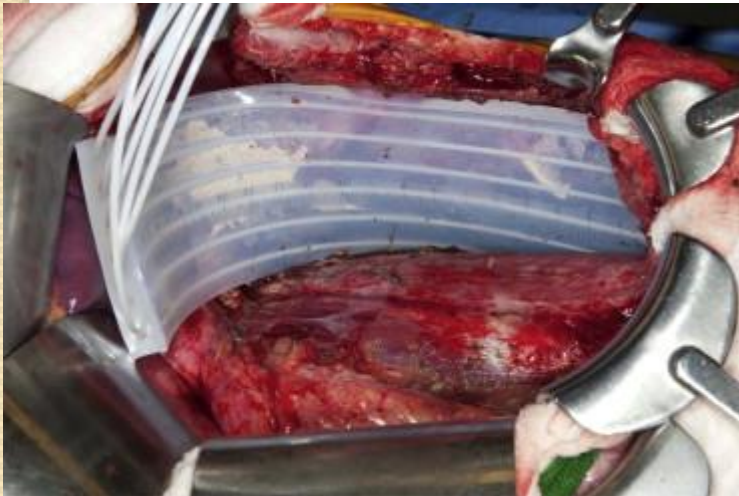
Example kidney-sparing neuroblastoma RT with VMAT, <25% of kidney receiving >18Gy, courtesy of Dr. Olch at CHLA



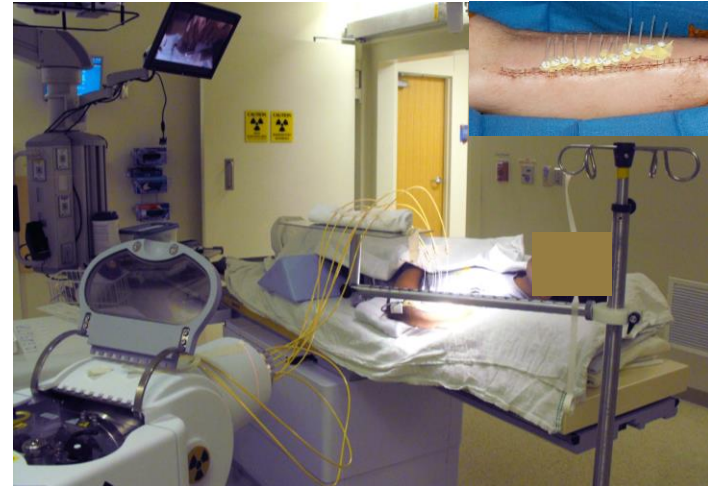Noncoplanar VMAT can achieve better bilateral hippocampal sparing than coplanar VMAT and dynamic conformal arc. Uto et al, Radiat Oncol 2016

Pediatric Brachytherapy

- Soft tissue sarcoma – HDR with interstitial catheters (multiple fractions) or IORT with HAM applicator on tumor bed after surgical resection (single fraction)
- Retinoblastoma – episcleral plaque brachytherapy with I-125 or Pd-103
- Neuroblastoma – EBRT is mainstay but HDR-IORT has been performed
- Brain tumors – EBRT is mainstay but intracavitary brachytherapy with P-32 has been performed for craniopharyngioma and I-125 for low grade glioma



MSKCC HDR+HAM applicator, Folkert et al, IJROBP, 2014



St Jude sarcoma HDR treatment setup with interstitial catheters

Relevant publications: HDR-IORT techniques and planning for pediatric sarcoma – please see Folkert et al, IJROBP 2014
ABS consensus guidelines for retinoblastoma plaque brachytherapy – Brachytherapy 13(1), 2014
RT for retinoblastoma MDACC experience – Agarwal et al, IJPT, March 2016
Chapter of pediatric brachytherapy in the book “Brachytherapy, 2nd edition, applications and techniques”

Summary for Pediatric Photon Therapy

- ❑ CT and MR simulation for pediatric patients should tailor CT scan protocols and MR pulse sequences to different anatomical sites and patient size.
- ❑ Efforts to reduce radiation exposure from CT Sim and CBCT imaging should be made.
- ❑ Radiotherapy guidelines in clinical trials are currently the best resources for setting normal tissue planning constraints. PENTEC reports will be published for treatment planning guidance.
- ❑ New delivery techniques have been applied for pediatric malignancies with complex shapes, such as Tomotherapy and VMAT for craniospinal irradiation and total body irradiation.

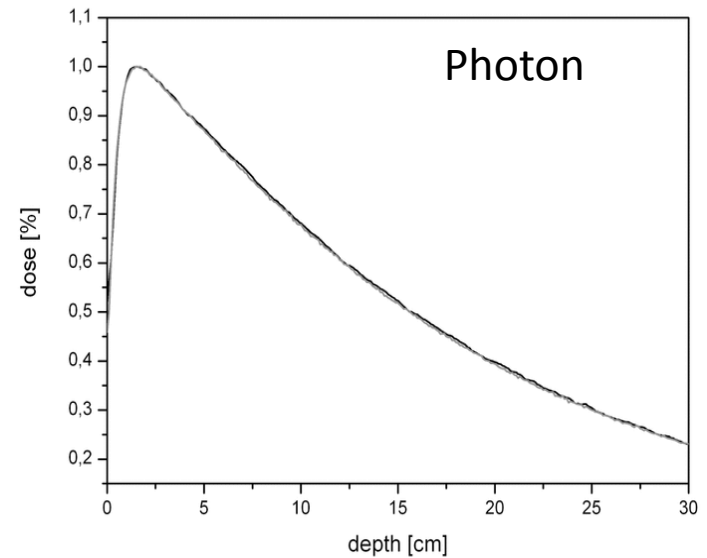
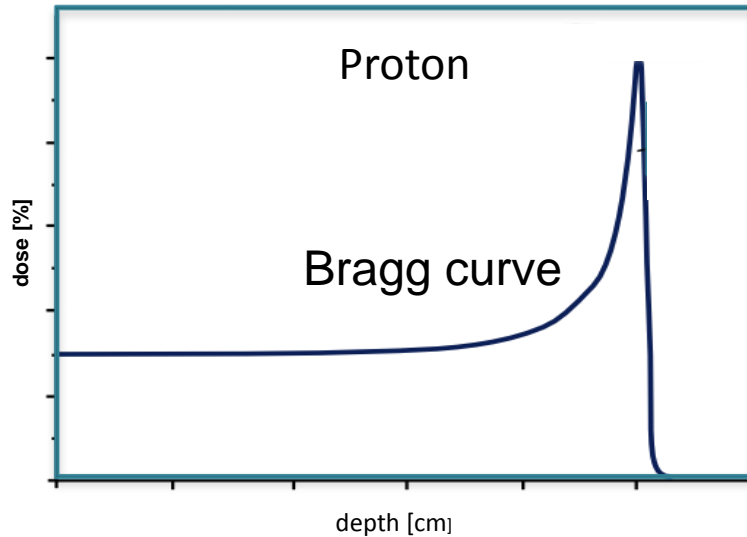


Pediatric Proton Therapy Physics

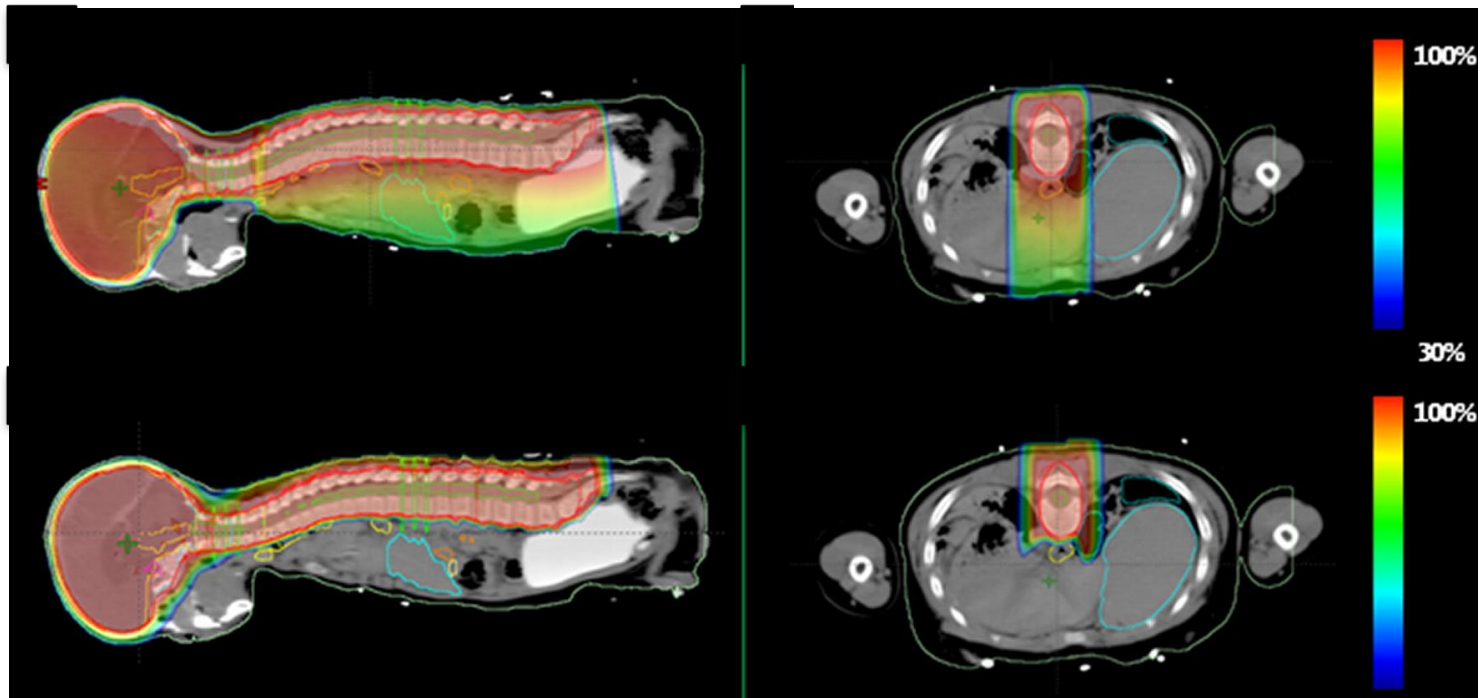
Outline for Pediatric Proton Therapy

1. General proton therapy physics
2. Scanning beams vs. scatter beams
3. Proton therapy facilities
4. Volumetric image guidance for proton therapy
5. Pediatric proton therapy: patterns of care
6. Proton dosimetric advantages and predictions of radiation necrosis and second cancer risk
7. Challenges in pediatric proton therapy
8. Proton techniques for pediatric CSI
9. Proton techniques for pediatric Hodgkin lymphoma
10. Controversy on brainstem necrosis in children
11. Bowel gas, metal artifact, beam hardening
12. Summary

General Proton Therapy Physics



Photon

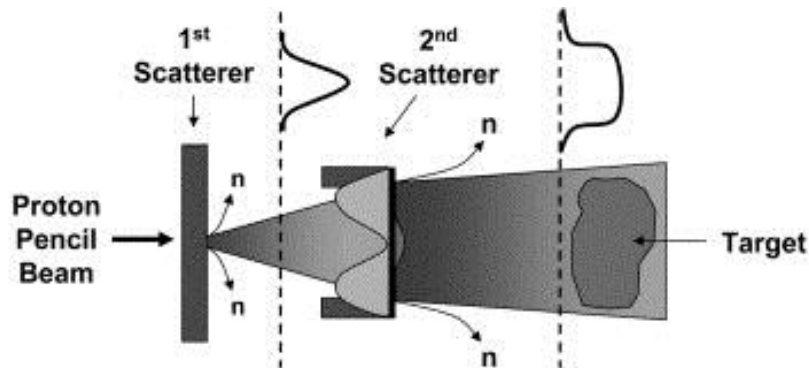


Proton

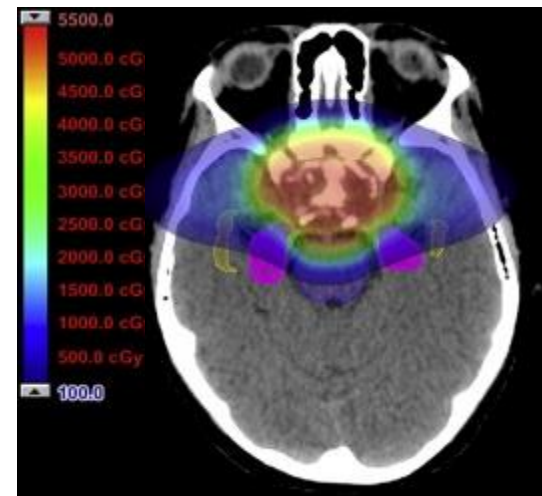
Two Types of Beam Delivery Nozzles (Scattering vs. Scanning)

Passive scattering is the traditional technology.

Passive Scattering

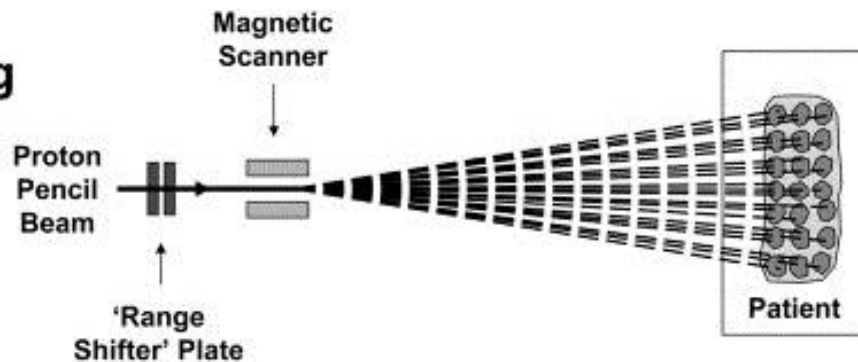


3D conformal proton plan

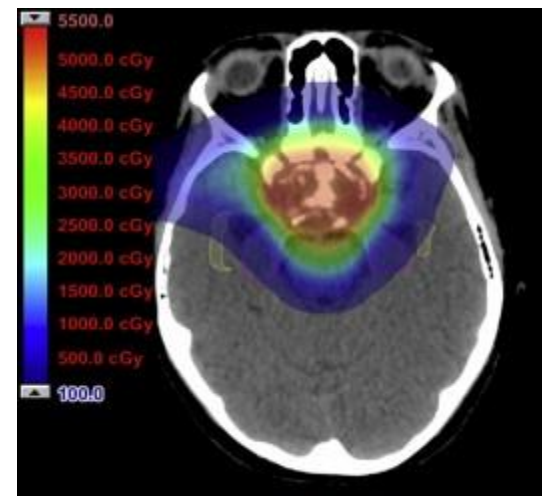


State of the art technology is scanning beam.

Active Scanning



Intensity modulated proton plan



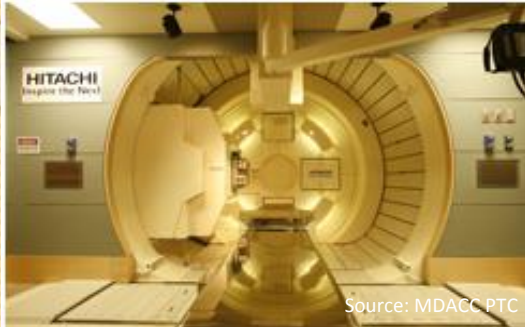Source: Hall, IJROBP 2006 vol 65

(a.k.a. pencil beam scanning, spot scanning)

Source: Boehling et al, IJROBP 2012 vol 82

Proton Therapy Facilities

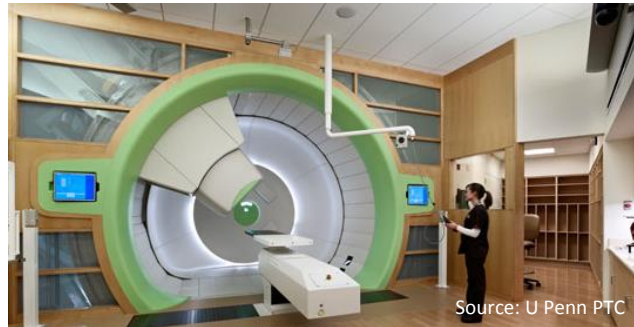HITACHI



Source: MDACC PTC

National Cancer Center Japan, MD Anderson, Nagoya City Hospital, Hokkaido University, Mayo Clinic, St. Jude Children's Research Hospital, Johns Hopkins, etc

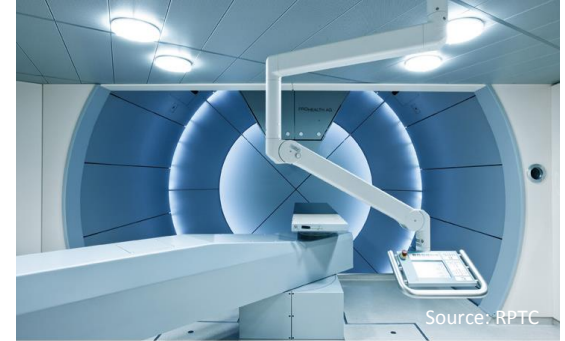IBA



Source: U Penn PTC

MGH, U Florida, Procure, U Penn, Indiana, Hampton U, Korean NCC, Wanjie, WPE, PTC Czech, Apollo PTC, etc

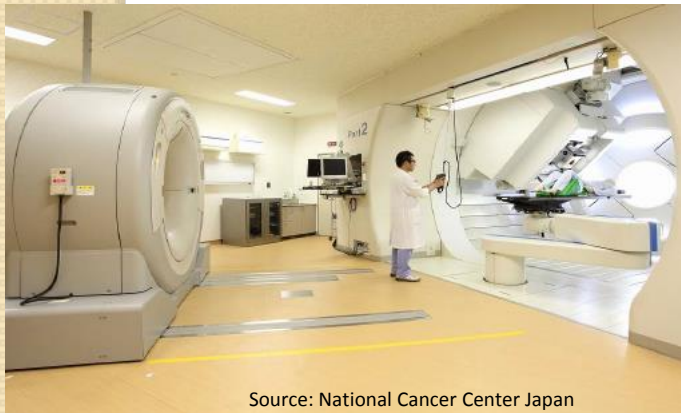Varian (former ACCEL)



Source: RPTC

RPTC (Rinecker), Scripps, PSI (by ACCEL), Maryland PTC, Emory University, etc

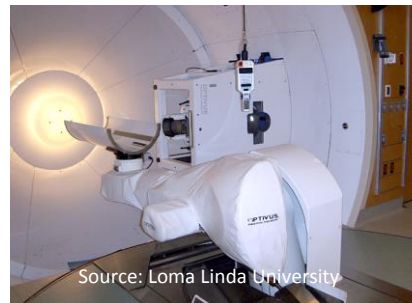Sumitomo



Source: National Cancer Center Japan

National Cancer Center Japan
Aizawa hospital Japan, Chang Gung hospital Taiwan
Sansung medical center Korea

Optivus



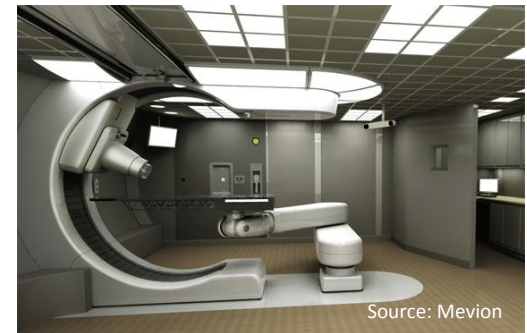Source: Loma Linda University

MITSUBISHI



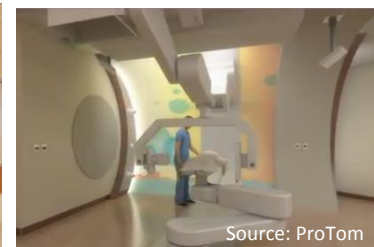Source: MITSUBISHI

Mevion



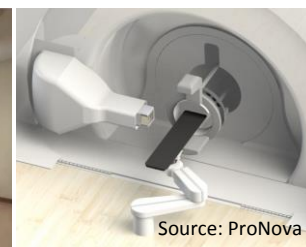Source: Mevion

ProTom



Source: ProTom

ProNova

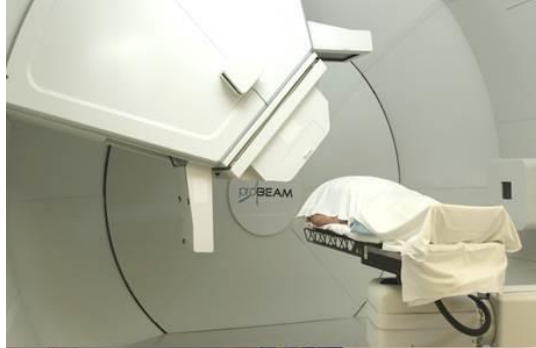

Source: ProNova

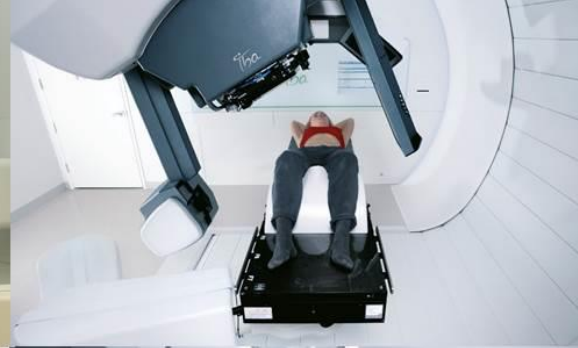Volumetric image guidance for proton therapy

Used to rely on 2D orthogonal imaging for verifying patient positions. But the era of volumetric image guidance with CBCT and CT-on-rails has arrived.

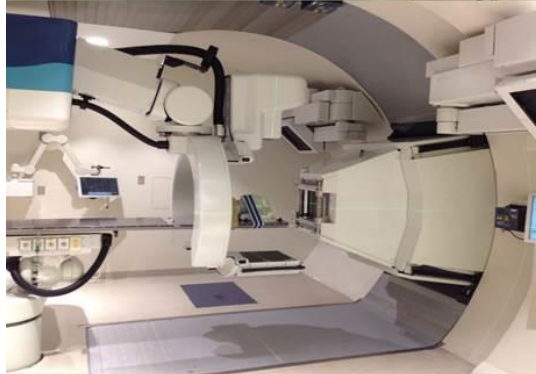
Gantry mounted
CBCT



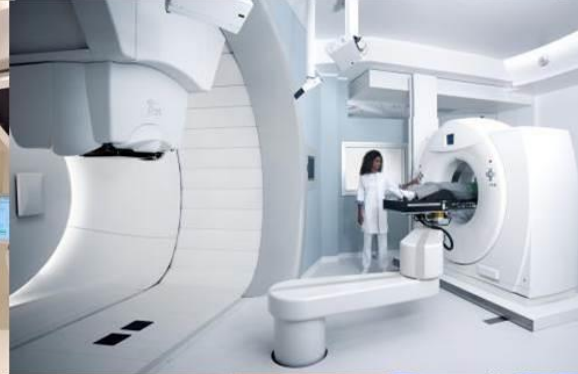Nozzle mounted
CBCT



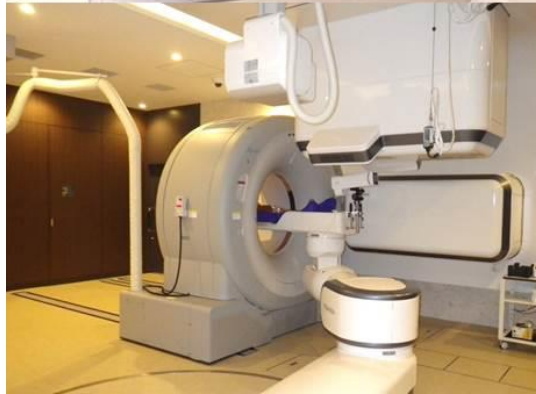C-arm mounted
CBCT



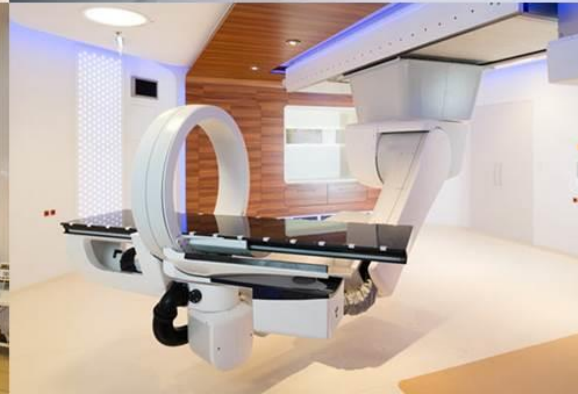In-room CT
on rails



In-room CT
on rails



Couch mounted
CBCT



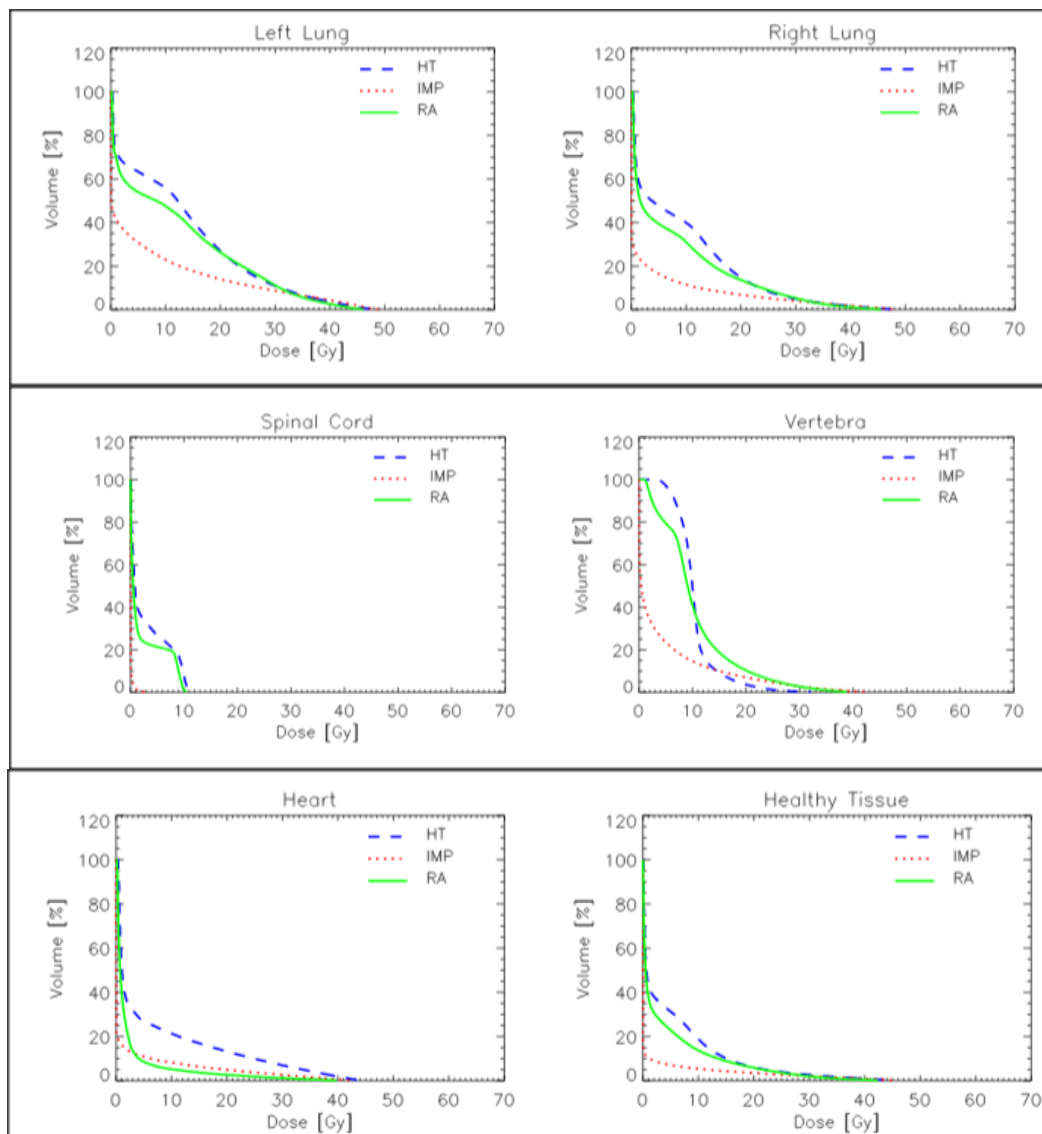
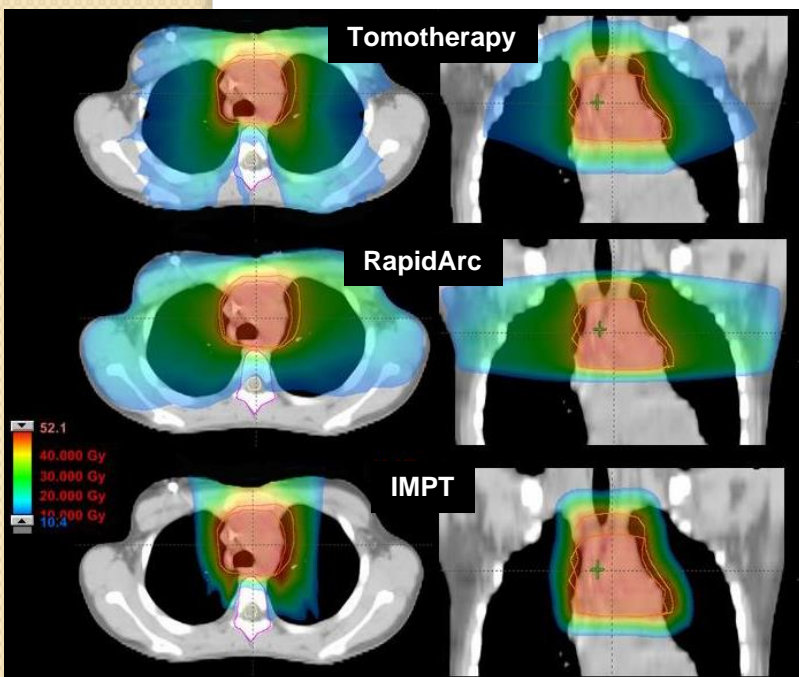
Pediatric Proton Therapy: Patterns of Care

- ❑ Estimated 15,700 children/adolescents are diagnosed with cancer each year in US (~10,000 excluding leukemias) (CureSearch website). Approximately 3000 require RT as part of frontline management (Siegel 2012 CA).
- ❑ # of proton patients in US ↑ from 613 to 722 (from 2011 to 2013).
- ❑ Survey on 11 operating proton centers in 2013 (Chang & Indelicato 2013 IJPT)
 - 99% with curable intent
 - Medulloblastoma** is the most common, followed by ependymoma, low grade glioma, rhabdomyosarcoma, craniopharyngioma, and Ewing's sarcoma.
 - Majority were enrolled on single/multi-institution registry studies or therapeutic trials
- ❑ Multi-room centers were the only option in the past but single room facilities have become popular
- ❑ Majority have passively scattered beams due to limited access to scanning beams and large spot sizes. IMPT with spot scanning of small sizes has been increasing, especially in new centers.

Pediatric Proton Therapy: Dosimetric Advantages in Critical Organs

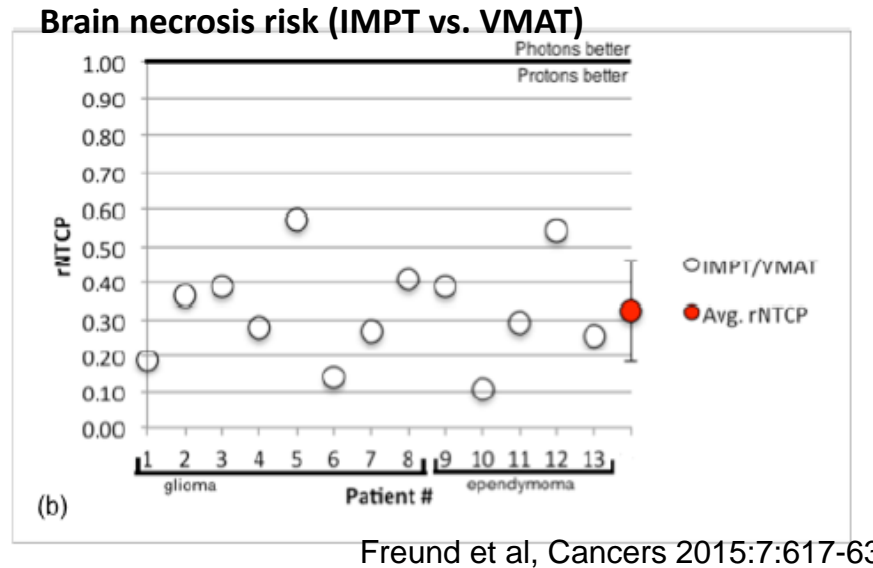
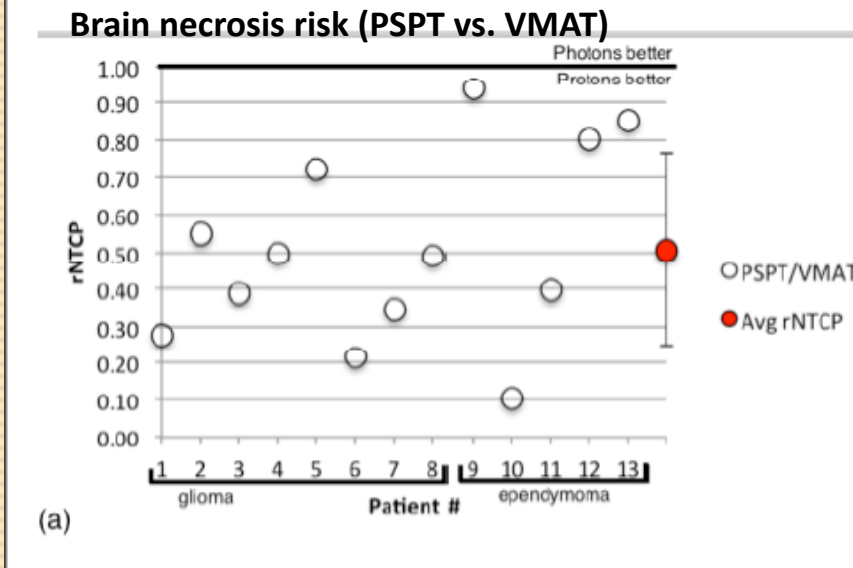
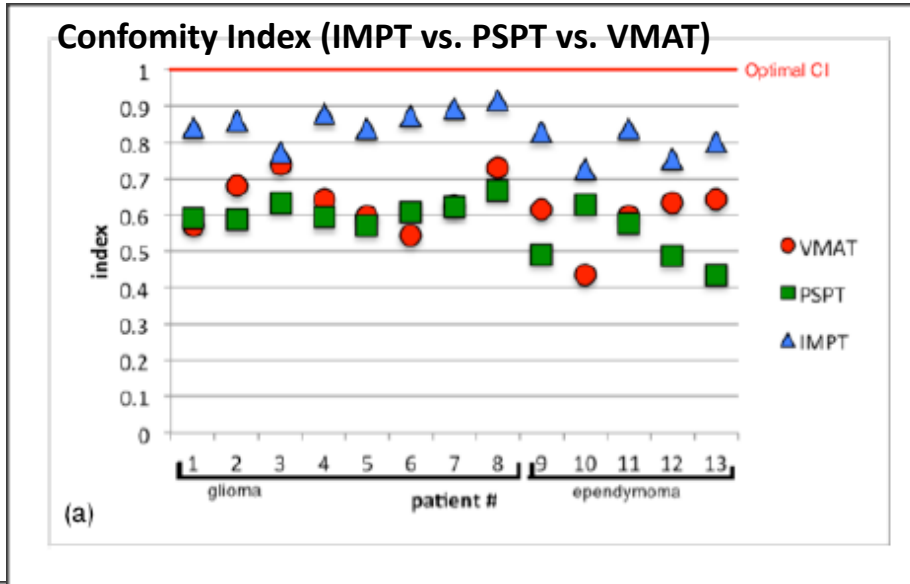
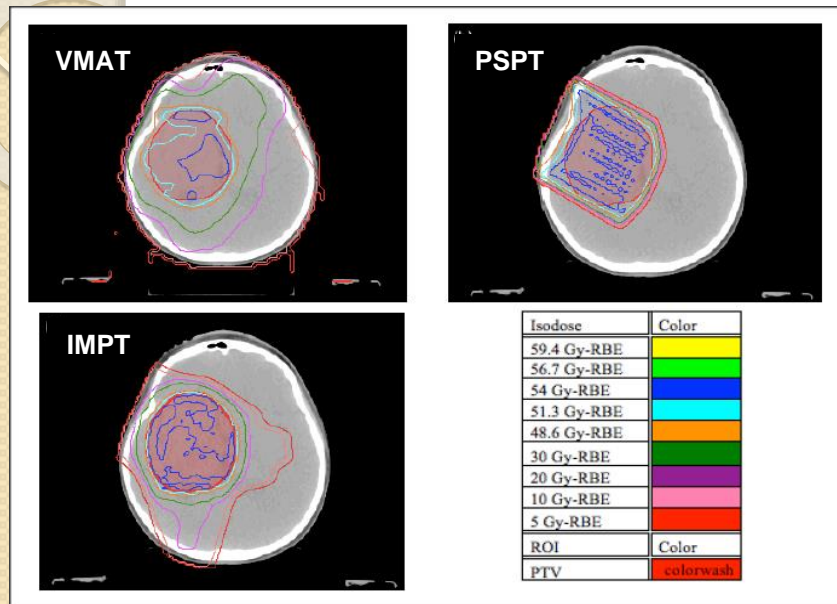
IMPT produced the best healthy tissue sparing and the lowest integral dose compared to helical Tomotherapy and RapidArc although all techniques were satisfactory.

Rhabdomyosarcoma in mediastinum



Pediatric Proton Therapy: Necrosis Risk

IMPT and PSPT plans resulted in a significant lower predicted risk of necrosis than VMAT plans.

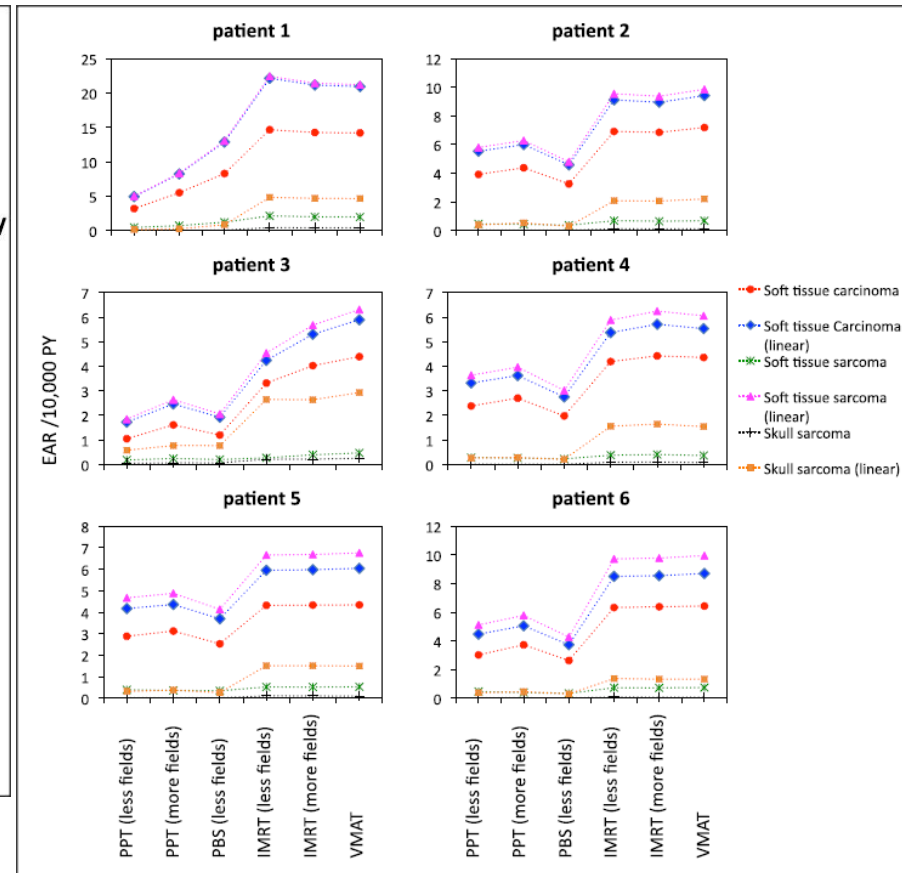
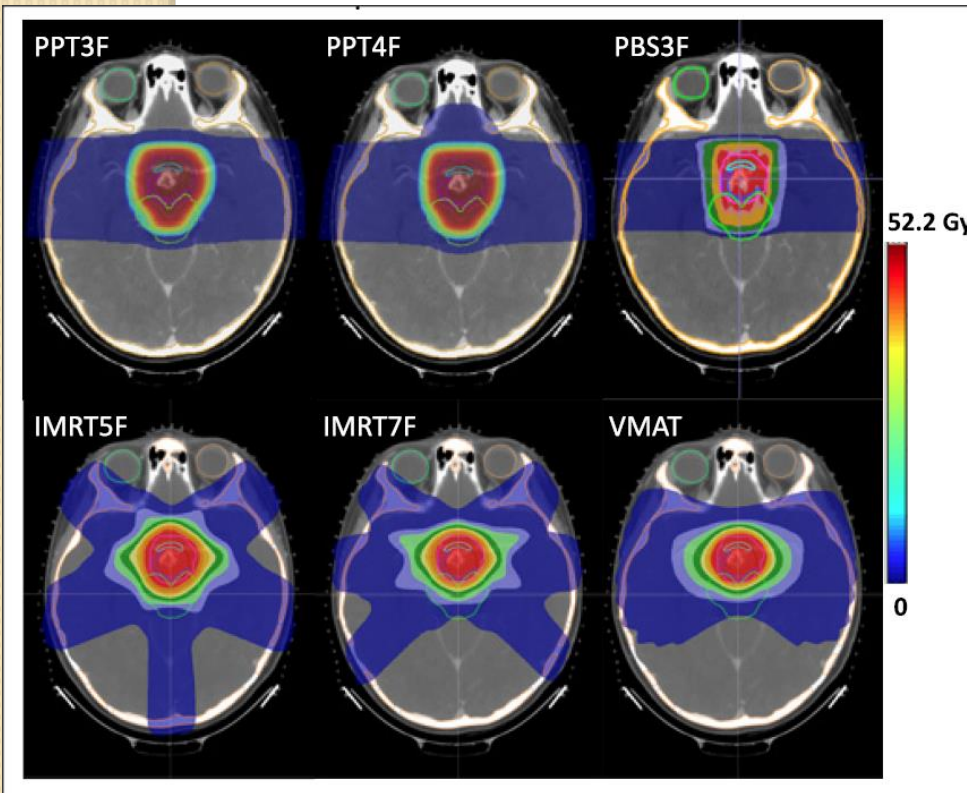


Pediatric Proton Therapy: Second Cancer Risk Prediction

In general, protons irradiated smaller volumes of healthy tissue than IMRT and VMAT. Proton therapy was particularly superior at the lower-dose end of the DVH curves.

IMRT and VMAT lead to higher risk of developing second malignancies compared to PPT and PBS for pediatric patients with brain/head and neck tumors.

Excess absolute risk of proton vs. photon



Pediatric Proton Therapy: Challenges

Biology and clinical

- ❑ Limited knowledge on in-vivo biological effect. Uncertain RBE effect at distal edge
- ❑ Concerns about brain and brainstem necrosis in treatment of posterior fossa tumors
- ❑ Limited data on clinical outcomes and normal tissue tolerance. Demonstrate clinical significance.

Physics and technical

- ❑ Range uncertainty (e.g. requiring margin of 3.5% × tumor depth)
- ❑ Larger spot sizes at lower energies (conformity of shallow target in small children)
- ❑ Limited options for beam angle (avoid going through bowel gas and high heterogeneous tissues)
- ❑ Motion interplay effects with proton scanning (mitigation strategies were proposed)

Workflow and application

- ❑ Longer wait for beam ready after patient setup (motion while beam switching from room to room)
- ❑ Longer delivery time (dose rate, layer switching, longer scanning with larger volume, SBRT-type?)
- ❑ Is proton (especially scanning beams) better for SIB or reirradiation?
- ❑ Fiscal challenges (referral, more staff and room time, affordability, financial burden on centers)

Proton Craniospinal Irradiation for Children

- ❑ Dose reduction in mandible, parotid gland, thyroid gland, lung, kidney, heart, ovary, uterine, and other non-target intracranial structures (St Clair 2004 IJROBP, Lee 2005 IJROBP, Howell 2012 IJROBP).
- ❑ IMPT achieves better OAR sparing than passive scattered beams while maintaining cribriform plate coverage (Dinh 2013 RO).

Table 4 Organs at risk		36Gy(RBE) prescribed CSI dose, Passive Scatter vs. IMPT		
Index	PSW (Gy(RBE))	PSWO (Gy(RBE))	IMPT (Gy(RBE))	
Left cochlea (mean)	36.4 ± 1.3	36.7 ± 1.0	28.6 ± 3.3 [†]	
Right cochlea (mean)	36.4 ± 1.4	36.7 ± 0.9	27.4 ± 1.5 [†]	
Left lens (max)	22.2 ± 5.5	24.8 ± 6.1*	12.5 ± 4.0 [†]	
Right lens (max)	22.8 ± 5.2	25.2 ± 5.9*	12.9 ± 5.0 [†]	
Brainstem (max)	39.3 ± 2.0	38.8 ± 2.0*	38.4 ± 0.5	

*Abbreviations: PSW passive scatter with compensator; PSWO passive scatter without compensator; IMPT intensity modulated proton therapy; Data presented as mean ± standard deviation; *significant vs. PSW, [†]significant vs. PSW or PWO, (p < 0.05), Student's t-test with Bonferroni correction for multiple comparisons.*

Dinh et al, Radiat Oncol 2013;8:289

- ❑ **Models predict lower risk** of second cancer, lower rate of pneumonitis, cardiac failure, xerostomia, blindness, hypothyroidism, and ototoxicity (Mirabell 2002 IJROBP, Newhauser 2009 PMB, Thaddei 2010 PMB, Brodin 2011 Acta Oncol, Zhang 2013 PMB).

23.4 Gy(RBE) CSI to 4 y.o. → predicted life time risk of second cancer is 24.6% for passive scatter proton CSI risk for photon CSI is 5.6 times higher (Zhang 2013 PMB)

Proton Craniospinal Irradiation for Children

Current clinical techniques:

- ❑ Supine position is common. Many centers require all fields to be set up and filmed prior to treatment of the first field.
- ❑ More common to treat with scattered beams but will change with the advent of scanning beams.
- ❑ Two posterior oblique beams for whole brain are common for lens sparing (Cochran 2008 IJROBP, Mahajan 2014 IJPT). Single PA spot scanning beam for uniform dose to the whole brain is feasible. Use one or more PA beams to cover spinal targets.
- ❑ Compensator use for passive scattered beams increased heterogeneity within the brain (Jin 2011 JACMP, Dinh 2013 RO). Many do not use compensators for whole brain.

Clinical outcomes

- ❑ No published data yet on long term effects of proton CSI
- ❑ Acute toxicity is mild – 40% experienced nausea requiring antiemetic for nausea prophylaxis and most patients experienced some degree of alopecia and dry skin (Mahajan 2014 IJPT).

Proton CSI setup

Indiana University Setup

- ❑ In house short and long CSI carbon fiber boards
- ❑ Indexed, homogeneous, torso-length
- ❑ No sharp thickness changes

MDACC Setup

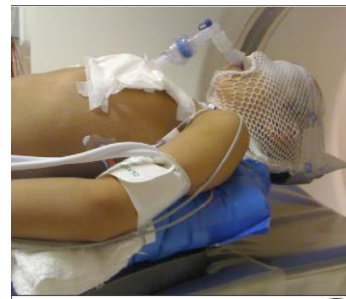
- ❑ Neutral head position and straight cervical spine/back
- ❑ 10cm thick styrofoam to elevate patient to prevent the posterior oblique whole brain fields from intersecting the couch edges.

Mass General Hospital Setup

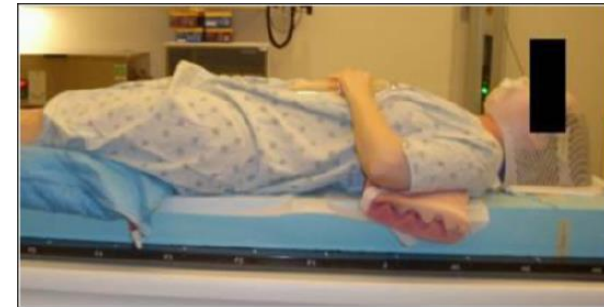- ❑ Prone head holder with chin and forehead pads
- ❑ Anterior face mask

Commercial BOS (base of skull) couch inserts

- ❑ Allow aperture to get close to patient to minimize penumbra
- ❑ No flat base so more freedom to choose beam angles



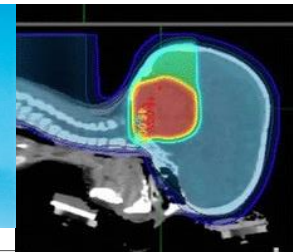
Buchsbaum et al, Med Dosim 2013;38:70-76




Giebler et al, Radiat Oncol 2013;8:32



www.civco.com



Min et al, Radiat Oncol 2014;9:220



www.qfix.com

Proton CSI: Whole Brain Techniques

MGH patient treatment (Cochran 2008 IJROBP)

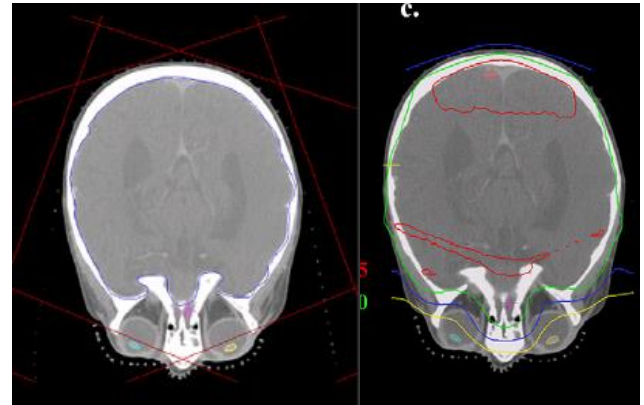
Posterior oblique beams (20° in the posterior direction) spare lens more than opposed laterals for **passive scattered** beams.

MDACC IMPT paper study (Stoker 2014 IJROBP)

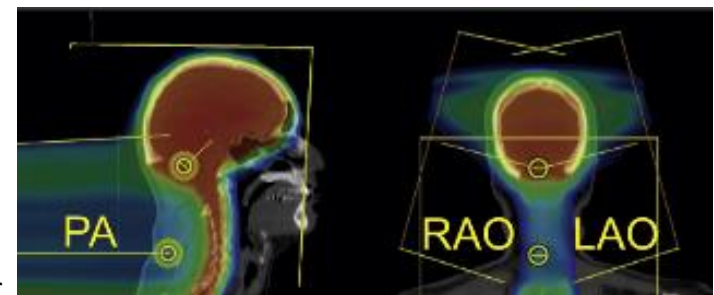
2 cranial fields-mirrored **anterior oblique** beams, angled 75° laterally with S-I rotation to prevent the ipsilateral eye from eclipsing the target.

PSI and Scripps patient treatment (Timmermann 2007 Strahlenther Onkol, Chang PTCOG meeting 2015)


A **single PA** beam of **spot scanning** for whole brain and spinal axis. Allow for a precise individual conformation of dose to the frontal subarachnoid space (Timmermann 2007 Strahlenther Onkol).



Cochran et al, Int J Radiat Oncol Biol Phys 2008;70:1336-1342



Stoker et al, Int J Radiat Oncol Biol Phys 2014;90:637-644



Timmermann et al, Strahlenther Onkol 2007;112:685-688

Proton CSI: Low Gradients Across Spine Field Junction to Remove Junction Changes

U Penn patient treatment (Lin 2014 IJROBP)

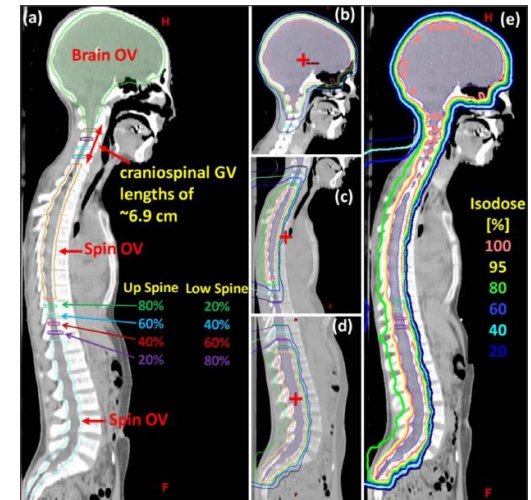
- ❑ No junction change. 5-8 cm overlap region between fields
- ❑ 4 equally spaced “gradient volumes” optimized to achieve low dose-gradient junctions

Scripps patient treatment (Chang 2015 PTCOG meeting)

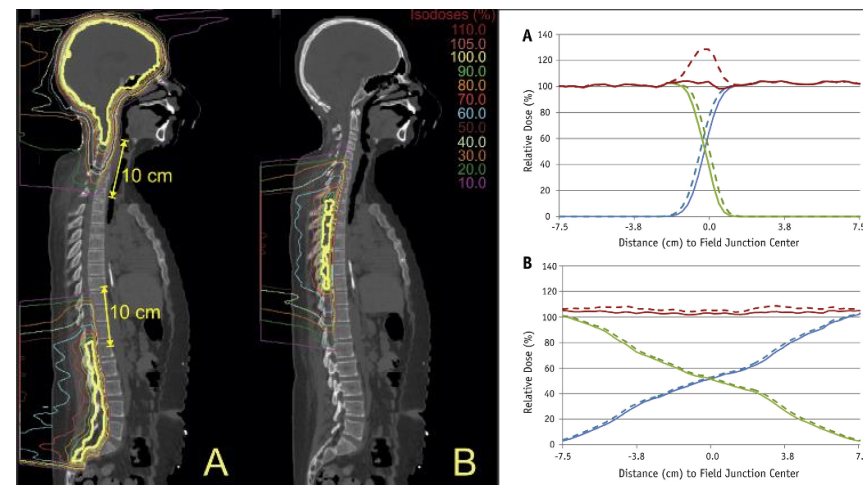
- ❑ Two isocenters for entire CSI and two fields overlap 5-6 cm
- ❑ Overlaps in high thoracic region to avoid thyroid & esophagus
- ❑ Commercial IMPT TPS to create 2%/mm smooth dose gradients

MDACC paper study (Stoker 2014 IJROBP):

- ❑ 10-cm overlap region between fields
- ❑ Target divided along the cranio-caudal axis into 4 to 10 equally sized tapering segments
- ❑ 3 staged IMPT optimization
- ❑ OAR sparing as good or better than passive scattered plans



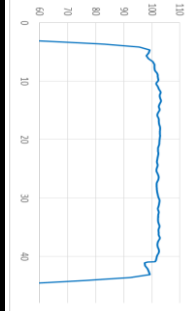
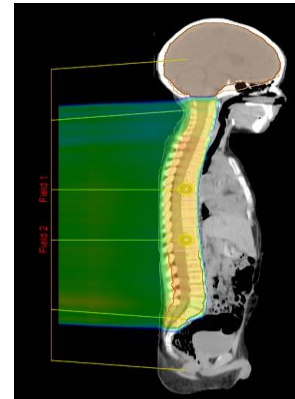
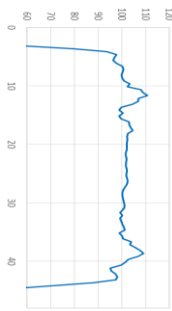
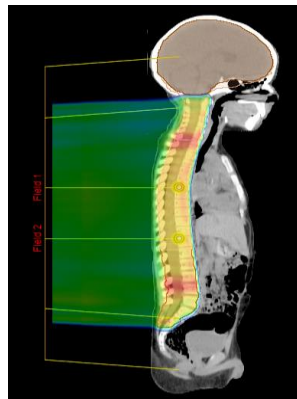
Lin et al, Int J Radiat Oncol Biol Phys 2014;90:71-78



Stoker et al, Int J Radiat Oncol Biol Phys 2014;90:637-644

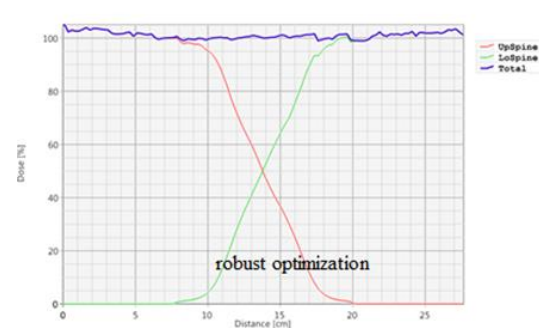
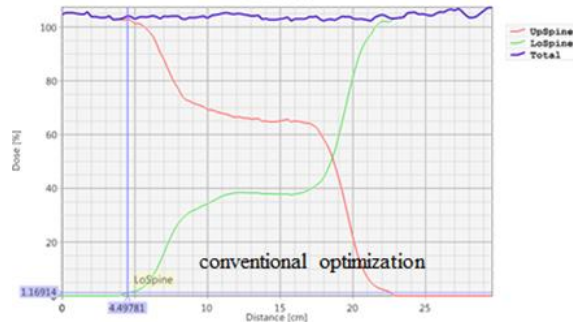
Pediatric Proton CSI without Junction Changes Via Robust Optimization

- ❑ Robust optimized IMPT plan can achieve a low dose gradient in overlapped junctions, is less sensitive to junction mismatch, and may eliminate the need for junction shifts.
- ❑ 10 cm overlap is needed to achieve max 5% dose variations applying a 3mm shift.



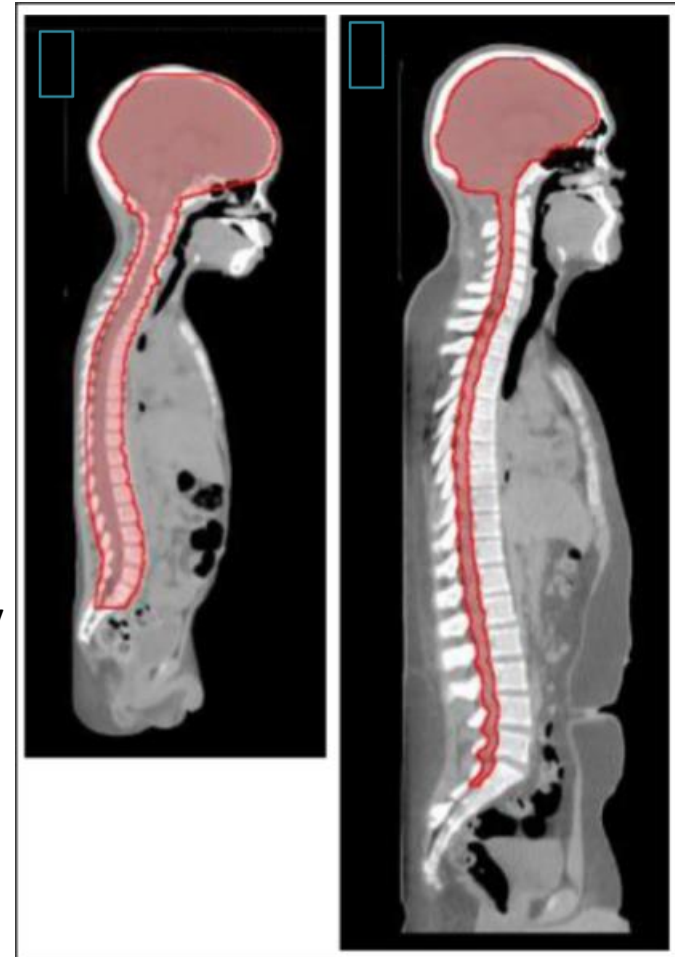
Conventional MFO optimization applying 3mm intra-fractional junction shift

Robust optimization applying 3mm intra-fractional junction



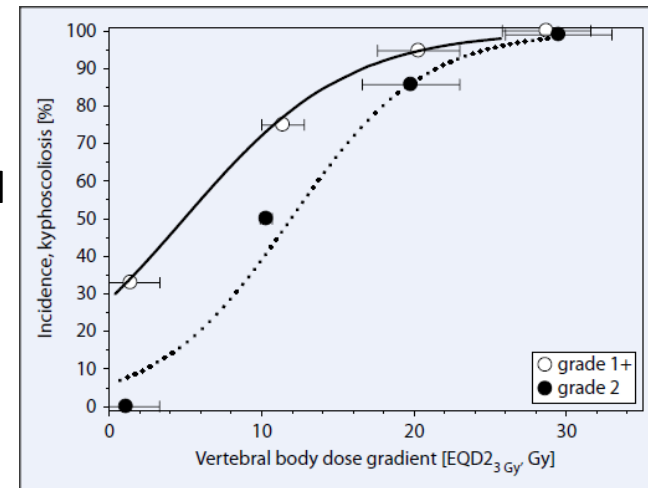
Pediatric Proton CSI: Vertebral Body Inclusion (Symmetric Bone Growth Vs. Bone Marrow Sparing)

- ❑ Common practice is to include the entire vertebral body for irradiation for younger children (**prepubertal**, not yet reaching the skeletal maturity, often <15 y.o.) to prevent differential growth of the spine (Krejcarek 2007 IJROBP, Giebeler 2013 Radiat Oncol, Lin 2014 IJROBP). But spare esophagus and thyroid.
- ❑ For older children (**postpubertal**), spare the vertebral body and the bone marrow inside. Allow for better tolerance of chemotherapy. Typically only the spinal canal is included with a few mm extension into the vertebral bodies to account for distal range uncertainty (Krejcarek 2007 IJROBP, Giebeler 2013 Radiat Oncol).
- ❑ May decide based on evidence of wrist epiphyseal closure on plain film (McMullen 2013 Pract Radiat Oncol)

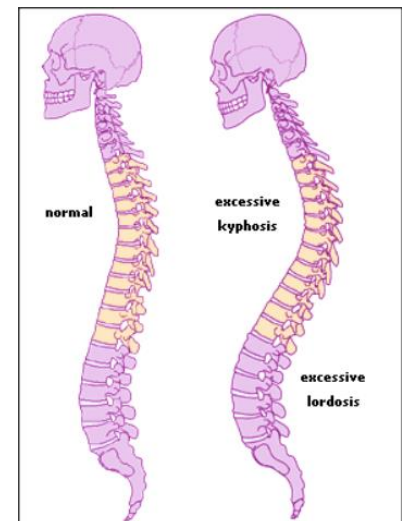


Pediatric Proton CSI: Vertebral Body Inclusion (Bone Tolerance Dose)

- ❑ The exact proton tolerance for pediatric growing bone is yet to be determined.
- ❑ For photon, **20 Gy tolerance** in children < 6 y.o. and **35 Gy** for older children (scoliosis, kyphosis, bony hypoplasia). Recommended a homogeneous dose profile within the vertebral bodies in younger children (Dorr 2013 Strahlenther Onkol).
- ❑ Lower CSI dose (18-23.4Gy) creates a dilemma regarding vertebral body coverage.
- ❑ St Jude photon data showed **lumbar spine (L1-L5)** was more affected by radiation than cervical or thoracic spine. Radiation insult to the more rapidly growing posterior components of the lumbar spine could contribute to greater lumbar lordosis (Hartley 2008 IJROBP).



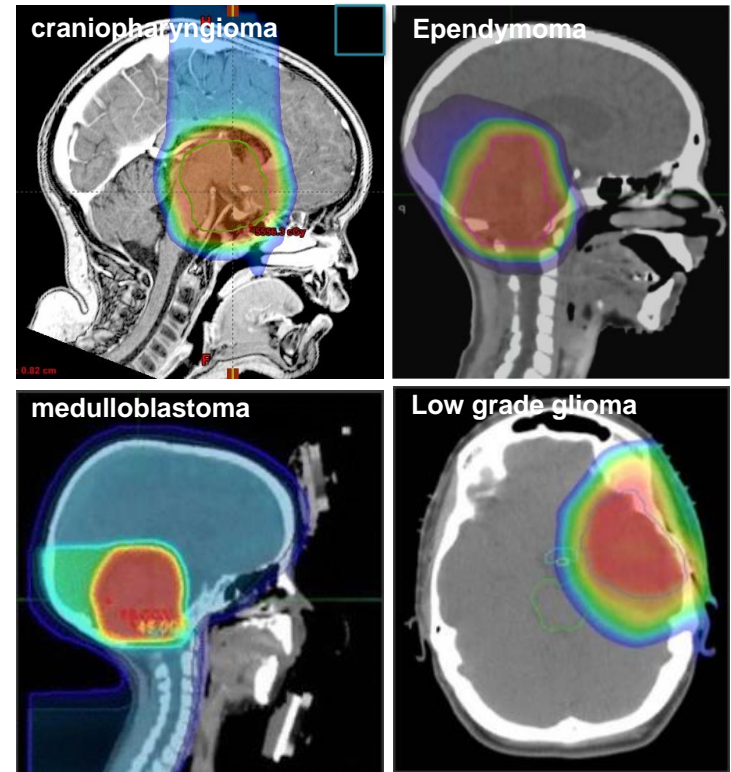
Dorr et al, Strahlenther Onkol 2013;189:529-534



Source: <http://www.spinalstenosis.org>

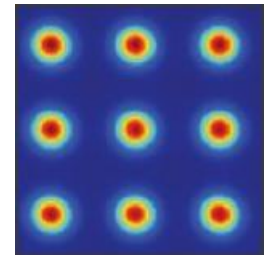
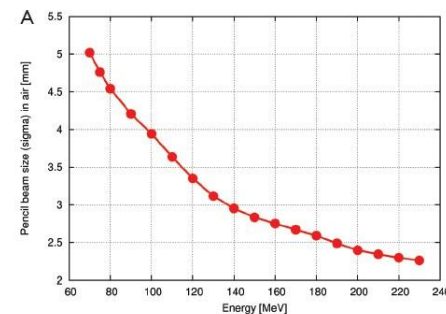
Proton Therapy for Pediatric Brain Tumors

- ❑ Commonly – medullo/PNET, ependymoma, craniopharyngioma, and low grade glioma.
- ❑ RT late effects – vision (chiasm, lens, optic nerve), hearing (cochlea, auditory nerve), endocrine (hypothalamus, pituitary), neurocognition (brain, medial temporal lobe).
- ❑ IMPT with MFO produces better target conformity and OAR sparing than SFUD (SFO) and passively scattered plans (Yeung 2014 *Pediatr Blood Cancer*)
- ❑ For IMPT, smaller spot sizes result in better plan quality. But pediatric brain tumors, typically 5-10cm deep, require lower beam energies which have larger spot sizes. The use of range shifter to treat <4cm deep tumors further degrade the spot sizes.



Min et al, *Radiat Oncol*, 2014;9:220

Shih et al, *Cancer*, 2015; 121:1712-1719



Safai et al, *Transl Cancer Res*, 2012;1:196-206

Proton Therapy for Pediatric Brain Tumors

❑ Common planning rules

- Avoid beams passing bony anatomy that could drastically change WEPL with a small rotation setup error, e.g. sinus cavities
- Avoid partially clipping couch corners or small high density setup devices
- Avoid stopping all distal edges within OAR
- Be aware of device inhomogeneity and stability over time (e.g. head cushion, head rest)

❑ Be aware of skin dose for single proton beam (permanent alopecia reported with concurrent chemo)

❑ Be aware of anatomy and tumor changes during proton course – steroid use, tumor growth, early response, cyst changes, CSF shunting. Repeat MRI/CT may be needed for surveillance and replanning.


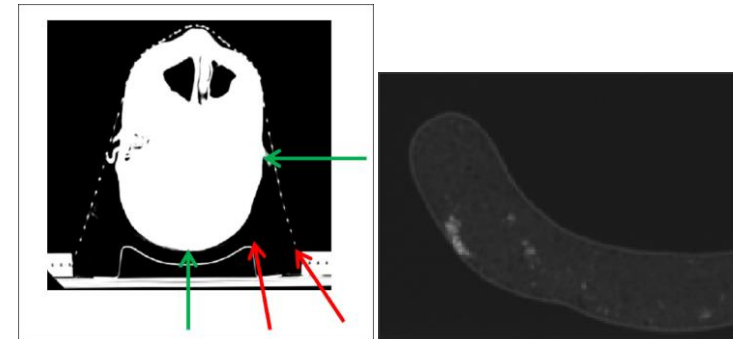
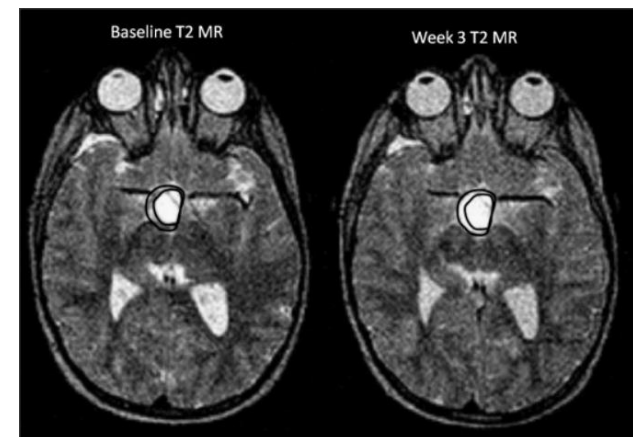


Figure 10: CT images of the MoldCare cushion system 0, 6 and 24 hours (left to right) after activation. Note that changes in shape are not a result of the curing process, but rather from imaging different positions in the cushion.

Wroe et al, Technol Cancer Res Treat, 2014;13:217-226

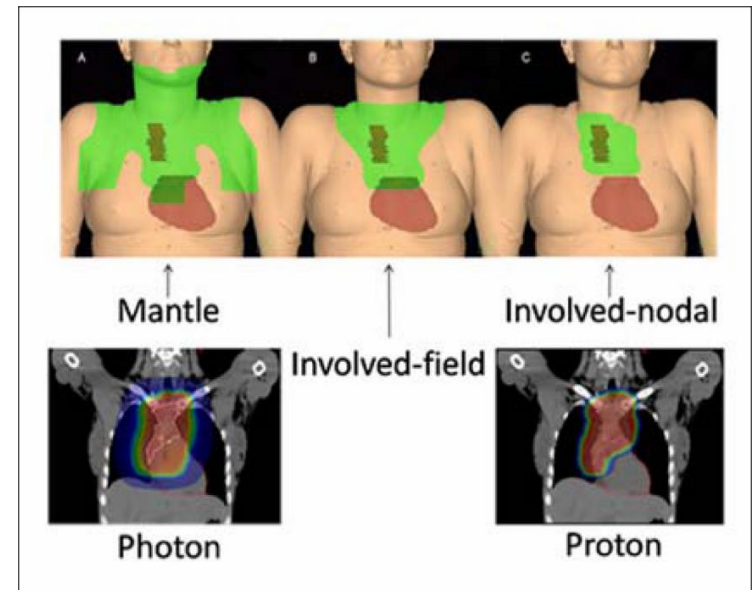


Beltran et al, Int J Radiat Oncol Biol Phys, 2012;82:e281-e287

Therapeutic Trends for Pediatric Hodgkin Lymphoma

- ❑ Late toxicities of pediatric Hodgkin treatment continue to emerge as patients survive longer (heart disease, second cancers). (review paper by Hodgson 2011 Hematology)
- ❑ 2 most recent thrusts within the RT community (Hoppe 2014 IJROBP).
 - treat a minimal target volume, the “involved node” or “involved site” as defined by volumetric and PET imaging
 - modify **radiation doses** based on chemotherapy response (response-adapted)
- ❑ Proton therapy is expected to further reduce the integral dose and late effects.

Conventional to contemporary targeting

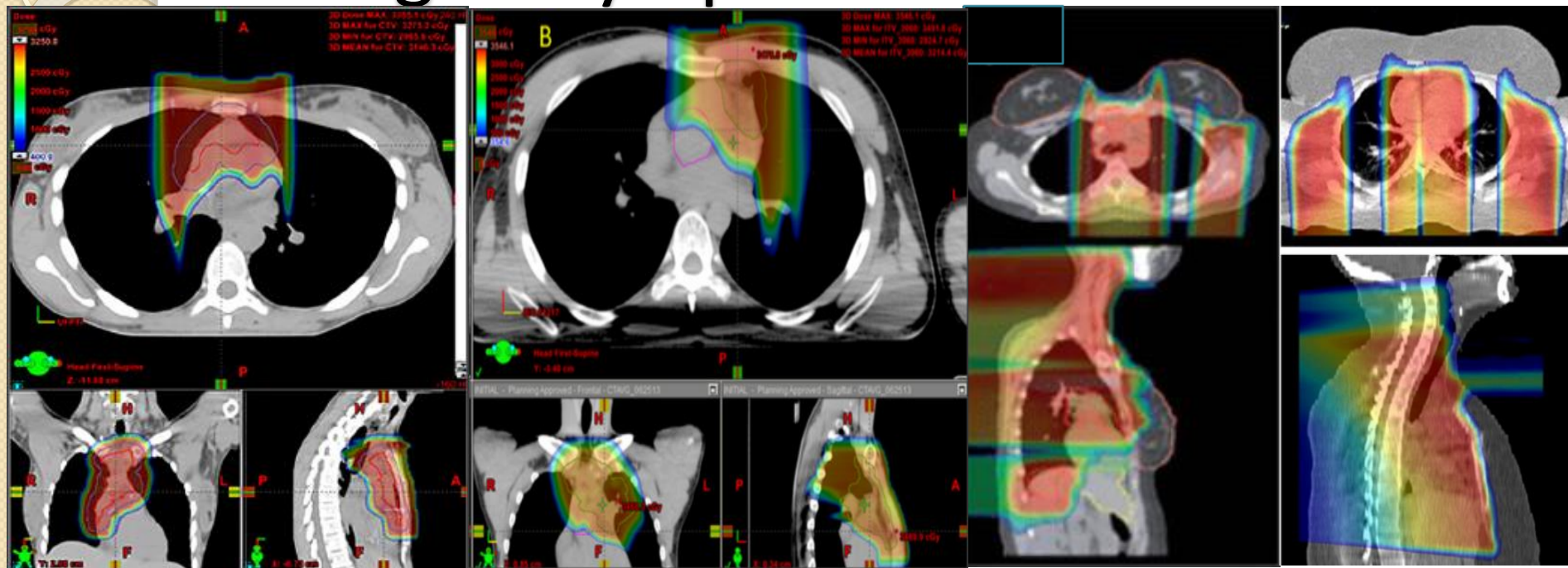


Merchant, Semin Radiat Oncol, 2013;23:97-108

Structure	3DCRT		IMRT		PT	
	Mean	±SD	Mean	±SD	Mean	±SD
Integral dose (joules)	122.9	62.3	103.8	48.6	53.6	32.0
Heart (Gy)	16.5	7.6	12.3	6.2	8.9	5.1
Lung (Gy)	11.6	3.7	9.8	2.8	7.1	2.5
Breast (Gy)	6.3	3.5	6.0	3.4	4.3	3.0
Thyroid (Gy)	19.3	10.1	17.7	9.3	15.8	9.7
Esophagus (Gy)	20.3	4.8	16.4	3.9	13.4	5.6

Hoppe et al, Int J Radiat Oncol Biol Phys, 2014;89;1053-1059

Proton Techniques for Pediatric Hodgkin Lymphoma



Hoppe et al, IJROBP, 2014:89:1053-1059

Plastaras et al, Semin Oncol, 2014:41:807-819

Holtzman, Acta Oncologica, 2013:52:592-594

Andolino et al, IJROBP, 2014:81:e667-e671

- ❑ Unless pre-chemo FDG PET can be performed in RT position, usually have to position RT patients to match pre-chemo imaging position for better image registration.
- ❑ 4DCT is typically performed to assess motion. Breath hold may be used to reduce heart and lung doses.
- ❑ UFPTI OAR priorities (after mean lung dose < 18Gy):
Heart > Lungs > Breasts (woman only) > esophagus (Hoppe 2014 IJROBP)
- ❑ Cardiac radiation exposure of ≥ 15 Gy increased the relative hazard of congestive heart failure, myocardial infarction, pericardial disease, and valvular abnormalities by 2-6 fold compared to non-irradiated survivors (Mulrooney 2009 BMJ).

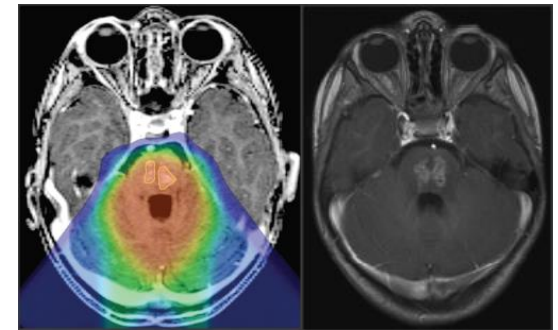
Pediatric Hodgkin Lymphoma: Proceed With Caution

- Appropriate margins to account for range uncertainty and going through heterogeneous tissues?
- Distal edges in critical organs. Uncertain increased RBE effect?
- Robustness evaluation or robust optimization for range and setup uncertainties
- Accuracy of proton dose calculation in thorax?
- CT image artifacts in thorax and shoulder regions
- Interplay effect significant from respiratory motion and pencil beam scanning?
- Volumetric image guidance is not available in many proton centers
- Patient selection for proton therapy depends on disease location and extent?

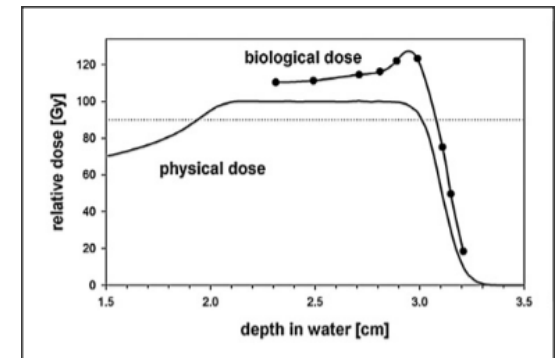
For more discussions, see the following publications
Lohr et al, Strahlenther Onkol, 2014:190:864-871
Hodgson & Dong, Leuk & Lymphoma, 2014:51:1397-1398

Controversy on Brainstem Necrosis from Proton Therapy

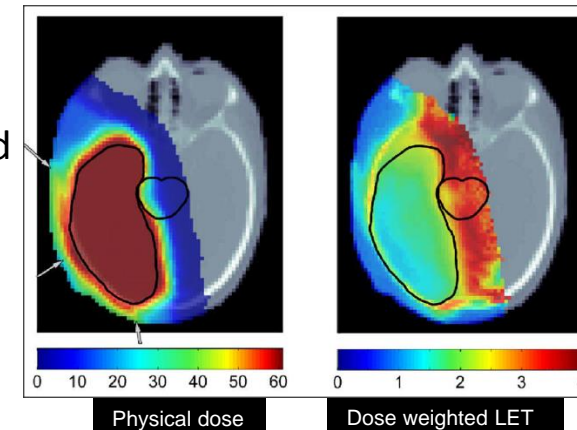
- ❑ Unanticipated complication of brainstem necrosis developed in pediatric patients receiving proton therapy.
 - 43% post-PT MRI changes in brain/brainstem of ependymoma patients (MDACC, Gunther 2015 IJROBP)
 - 3.8% incidence for >50.4 CGE to brainstem, but 10.7% for patients with posterior fossa tumors and 12.5% for <5 y.o. (UFPTI, Indelicato 2014 Acta Oncologica)
- ❑ Researchers suspected increased RBE at the end of range explains brainstem necrosis and proposed biological proton planning considering RBE variation.
- ❑ So far **no evidence of association** between RBE/LET distribution and brainstem toxicity or recurrence
 - Elevated RBE values due to increased LET at the distal end of treatment fields do not clearly correlate with radiation induced brainstem injury (Giantsoudi 2015 PTCOG meeting, Giantsoudi 2014 IJROBP).
 - No correlation between recurrence and Monte-Carlo calculated LET distribution in medulloblastoma patients receiving proton therapy (Sethi 2014 IJROBP).



Sabin et al, Am J Neuroradiol, 2013;34:446-450



Paganetti, Phys Med Biol, 2012;57:R99-R117



Wedenberg et al, Med Phys, 2014;41:091706

Controversy on Brainstem Necrosis from Proton Therapy

- Approaches to mitigate effects of \uparrow RBE at distal edge
 - Multiple fields with large angular separation
 - Proper angles to avoid distal ends of SOBP inside critical structures
 - Smear the distal fall off: split the dose for a field in half; deliver half of the dose as planned and then other half with range modified by 3mm (Buchsbaum 2014 RO)

- No consensus on brainstem tolerance for proton therapy. Currently err on the side of caution with brainstem.

UFPTI guidelines: **D_{\max} to brainstem ≤ 56.6 Gy**
 $D_{50\%}$ to brainstem ≤ 52.4 Gy

For young patients with posterior fossa tumors who undergo aggressive surgery, more conservative dosimetric guidelines should be considered. (Indelicato Acta 2014 Oncologica)

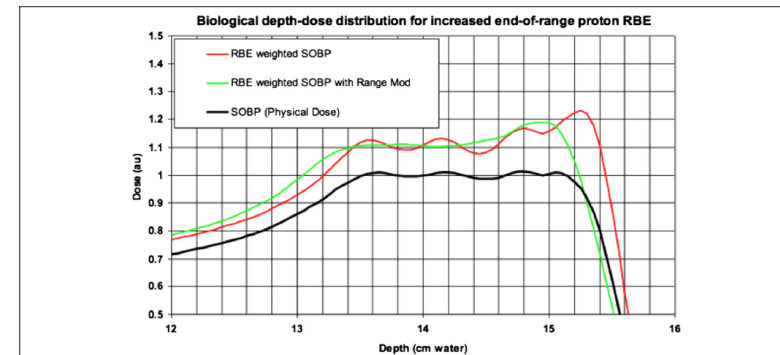
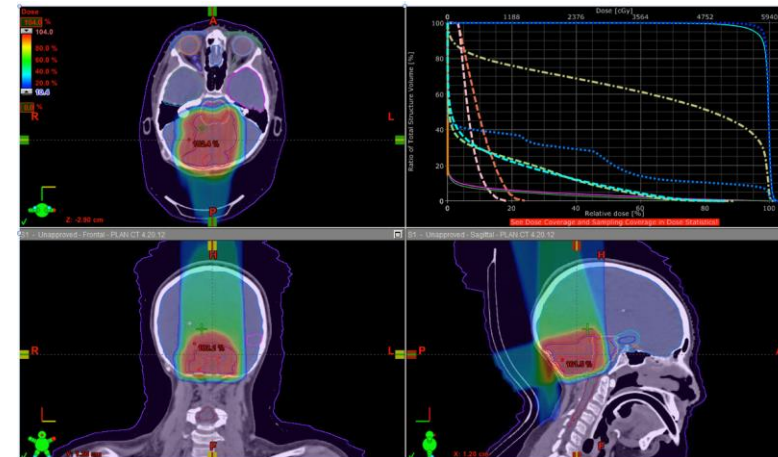


Figure 1 The physical dose for a SOBP composed of four pristine Bragg peaks each separate by 6 mm water equivalent. Applying our illustrative model of increased distal RBE to the individual pristine peaks produces the RBE weighted SOBP. The "range mod" technique mitigates the changes in SOBP plateau flatness, range, and effective dose at the distal edge. Here the modulation is achieved by splitting the SOBP into two parts and shifting one by 3 mm to both smooth out the SOBP and decrease the RBE at the end of the beam.

Buchsbaum et al, Radiat Oncol, 2014:9:2

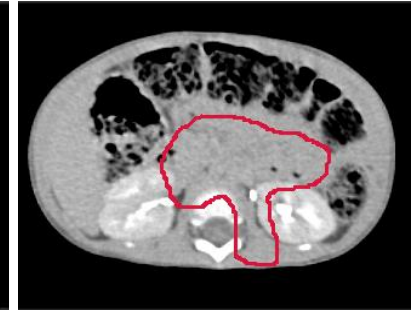
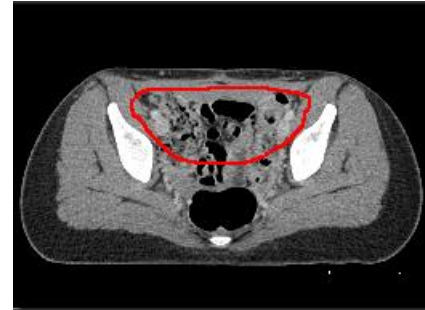


Buchsbaum et al, Radiat Oncol, 2014:9:2

Affecting Proton Range: Bowel Gas, Metal Artifact, and Beam Hardening

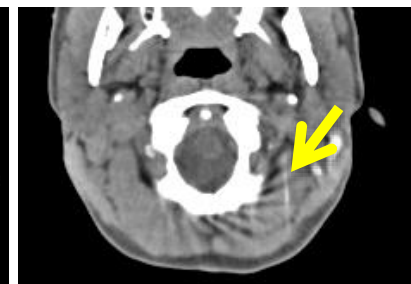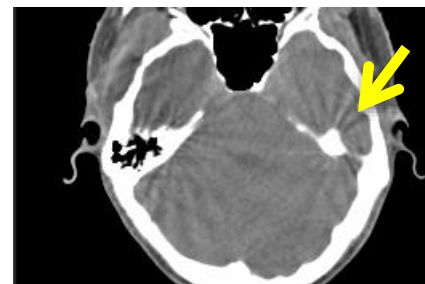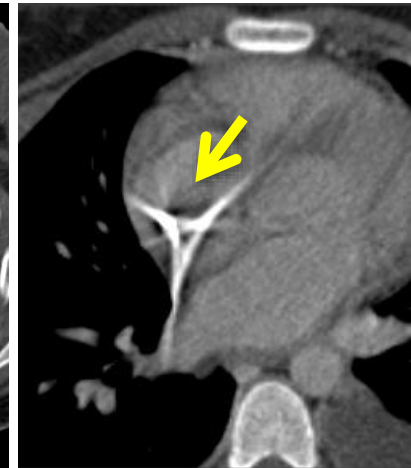
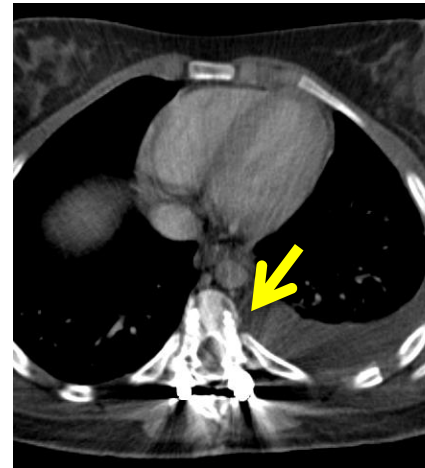
Bowel gas

- Often near neuroblastoma, Wilm's tumor, rhabdomyosarcoma, and bone sarcoma in abdomen and pelvis
- Vary in size and location every day
- Avoid shooting through bowel gas
- Override density within beam path on planning CT? Expect to average out?
- Pose a problem for whole abdominal RT



Metal artifact

- Spinal implant, dental braces, surgical clips
- Apply metal artifact reduction on CT? Need to overwrite CT numbers
- Need to know hardware material to assign proper proton stopping power



Beam hardening artifact without metal

Summary for Pediatric Proton Therapy

- ❑ Proton therapy is compelling for children and adolescents because of the promise in reducing **late effects and second cancer risk**.
- ❑ Most children are currently treated with passively scattered beams but **IMPT with scanning beams** of smaller spot sizes has arrived.
- ❑ Data on OAR tolerance and RBE effects in children are extremely limited. Planners and physicists should be careful in translating photon experience into proton (CT scan, margin design, OAR constraints, beam angle selection, setup and immobilization devices, etc).
- ❑ Opportunities await and abound for physicists –
 - technical guidance on patient selection for proton therapy
 - safe and efficient delivery to this vulnerable patient population
 - disease-specific treatment techniques including reirradiation
 - uncertainty analysis and margin design
 - sharing planning and delivery experience with the community



Please contact authors for questions and requests to use materials in this slide set for publication or presentation.

Chia-ho Hua chia-ho.hua@stjude.org

Ken Ulin Kulin@qarc.org